

The Pattern of Acetabular Cartilage Wear Is Hip Morphology-dependent and Patient Demographic-dependent

Cecilia Pascual-Garrido MD, PhD, Deborah J. Li BA, George Grammatopoulos MD, PhD, FRCS, Elizabeth L. Yanik PhD, ScM, ANCHOR Group, John C. Clohisy MD

Received: 1 June 2018 / Accepted: 4 January 2019 / Published online: 17 April 2019
Copyright © 2019 by the Association of Bone and Joint Surgeons

Abstract

Background Acetabular cartilage damage has been described in patients with femoroacetabular impingement (FAI). However, most reports of articular cartilage damage in hip FAI have been focused on the acetabular cartilage and derived from single-center, retrospective studies of

relatively small patient cohorts. Identifying patterns of articular cartilage wear is important in patient selection, treatment prognosis, and determining whether patterns of intraarticular cartilage wear are secondary to abnormal hip morphology. Using a multicenter, observational cohort, we sought to determine whether there was a specific pattern of cartilage wear across acetabular and femoral articular cartilage among patients with symptomatic FAI.

This work was supported by the Curing Hip Disease Fund (JCC). *Clinical Orthopaedics and Related Research*® neither advocates nor endorses the use of any treatment, drug, or device. Readers are encouraged to always seek additional information, including FDA approval status, of any drug or device before clinical use.

Each author certifies that his or her institution approved the human protocol for this investigation and that all investigations were conducted in conformity with ethical principles of research.

This work was performed at the Department of Orthopaedic Surgery, Washington University School of Medicine, St Louis, MO, USA.

Questions/purposes (1) Is there is a specific pattern of cartilage wear in the acetabulum and femoral head, assessed during hip arthroscopy, in cam FAI, pincer, and mixed-type hip pathologies? (2) Are there specific patterns of cartilage wear associated with duration of symptoms, age, and/or body mass index (BMI)?

Methods A multicenter observational cohort and a hip preservation database from a senior author were used to identify 802 patients who underwent hip arthroscopy for the treatment of symptomatic FAI. The diagnosis of cam, pincer, or mixed-type FAI was determined by each treating surgeon at each institution using the minimum basic criteria of pain in the affected hip for a period of > 3 months, hip ROM, and radiographic findings. Acetabular and femoral head cartilage lesions were classified arthroscopically by location and severity for each group (cam, pincer, or mixed FAI). Cartilage wear was classified using the Beck classification and defined as cartilage lesions greater than Grade 1 (normal macroscopically sound cartilage). The assessment of cartilage wear was performed arthroscopically by experienced hip preservation surgeons who are a part of ANCHOR, a multicenter group that uses a longitudinally maintained database to investigate issues related to hip preservation surgery. Clinical characteristics, radiographic findings, and acetabular and femoral head damage by location and severity of wear were reported based on patient

C. Pascual-Garrido, E. L. Yanik, J. C. Clohisy, Department of Orthopaedic Surgery, Washington University School of Medicine, St Louis, MO, USA

D. J. Li, University of Miami Miller School of Medicine, Miami, FL, USA

G. Grammatopoulos, Nuffield Orthopaedic Care, University of Oxford, Oxford, UK

ANCHOR Group, Washington University, St Louis, MO 63110, USA

J. C. Clohisy (✉), Department of Orthopaedic Surgery, Washington University School of Medicine, 660 S Euclid Avenue, Campus Box 8233, St Louis, MO 63110, USA, Email: jclohisy@wustl.edu

All ICMJE Conflict of Interest Forms for authors and *Clinical Orthopaedics and Related Research*® editors and board members are on file with the publication and can be viewed on request.

diagnoses of cam ($n = 472$), mixed ($n = 290$), and pincer ($n = 40$) FAI hip pathologies. Wald chi-square tests were used to test for differences in the presence of wear in each cartilage quadrant across hip pathologies, duration of symptoms, age, and BMI. One-way analysis of variance tests were used to test for differences in average grade of wear in each cartilage quadrant across hip pathologies, duration of symptoms, age, and BMI. A bivariate logistic regression model was used to identify factors independently associated with the presence of cartilage wear in the acetabulum and femoral head. Acetabular cartilage wear was present in 743 of 802 patients (93%) in the cohort. Femoral head cartilage wear was observed in only 130 (16%).

Results We found significant associations between acetabular patterns of wear and FAI hip pathologies; specifically, we observed more frequent and severe debonding of acetabular cartilage in patients with symptomatic cam (93%, 1.7 ± 1.1 grade) and mixed (97%, 1.7 ± 1.2 grade) FAI compared with Pincer (75%, 1.5 ± 0.9 grade) FAI hip pathologies ($p < 0.001$). Superolateral peripheral cartilage lesions occurred more frequently and with greater severity in patients with cam (90% [416 of 472] prevalence, 3.1 ± 1.1 grade) and mixed (91% [260 of 290] prevalence, 3.1 ± 1.1 grade) FAI than in pincer (60% [24 of 40] prevalence, 2.2 ± 1.1 grade) FAI hip pathologies ($p < 0.0001$). Conversely, patients with pincer FAI most commonly demonstrated cartilage lesions with an even distribution at the anterior and superolateral acetabular rim: 64% (25 of 40) (mean grade 2.1 ± 1.0) and 60% (24 of 40) mean grade 2.2 ± 1.1 , respectively. Age was associated with increased presence of wear in both the acetabulum (odds ratio [OR], 1.05; 95% confidence interval [CI], 1.2–1.7; $p = 0.005$) and femoral head (OR, 1.08; 95% CI, 1.6–1.1; $p < 0.001$). BMI was associated with a greater presence of wear only in the femoral head (OR, 1.1; 95% CI, 1.2–1.1; $p = 0.002$). Specifically, compared with patients with a BMI $< 30 \text{ kg/m}^2$, patients with a BMI $\geq 30 \text{ kg/m}^2$ presented with more frequent and more severe lesions in the posterior peripheral acetabular rim (42% [47 of 117] versus 26% [171 of 677], $p = 0.0006$; grade 1.9 ± 1.3 versus grade 1.4 ± 0.9 , $p < 0.001$), the anterolateral femoral head (22% [20 of 117] versus 9% [6 of 67], $p = 0.006$), and the anteromedial femoral head (15% [16 of 117] versus 6% [39 of 677], $p = 0.002$; grade 1.3 ± 0.8 versus grade 1.1 ± 0.6 , $p = 0.04$). In general, we found that older patients (≥ 50 years old) presented with more frequent and more severe lesions in both the acetabulum and femoral head. We found no association between hip pathology and cartilage wear patterns in the examined femoral heads.

Conclusions Hip morphology affects the pattern of acetabular cartilage wear. More frequent and severe cartilage

lesions were observed in patients with symptomatic FAI cam and mixed-type hip pathologies. Surgical attempts to restore normal anatomy to avoid FAI should be performed to potentially improve long-term joint homeostasis. Increasing age is an independent risk for cartilage wear in both the acetabulum and femoral head. Additionally, increased BMI is an independent risk factor for cartilage wear in the femoral head. In the future, prospective studies should provide further insight into the pathomechanics of early degenerative changes associated with hip FAI deformities.

Level of Evidence Level III, prognostic study.

Introduction

Intraarticular lesions are common in patients with femoroacetabular impingement (FAI) [4, 5]. Cam FAI results from asphericity of the femoral head-neck area with an increasing radius of the femoral epiphysis as it joins the neck [4]. This deformity is driven into the acetabulum during hip flexion, damaging the acetabular cartilage [9]. Conversely, pincer FAI is characterized by an abnormality of the acetabulum, including excessive head coverage as is seen in acetabular retroversion or in a deep acetabulum. In these hips, the femoral neck impinges against excessive acetabulum coverage, resulting in linear contact between the neck and acetabular rim [9]. Both structural abnormalities frequently occur together and are termed as mixed or combined FAI.

The presence of articular cartilage damage at the time of FAI surgery is well documented, occurring in 70% to 88% of patients undergoing hip arthroscopy for the treatment of FAI [4, 5, 11]. However, although patterns of cartilage wear in hip FAI have been suggested, most reports are derived from single-center or retrospective studies of relatively small patient cohorts [4, 5, 10, 11]. Additionally, most of these studies have focused on acetabular cartilage damage alone without including the femoral head. There is also a lack of evaluation of associated comorbidities that may affect the pattern of cartilage damage, such as age, body mass index (BMI), or pain chronicity. Identifying patterns of articular cartilage wear is important in patient selection, treatment prognosis, and determining whether patterns of intra-articular cartilage wear are secondary to abnormal hip morphology.

Therefore, in our study, we sought answer the following questions: (1) Is there is a specific pattern of cartilage wear in the acetabulum and femoral head, assessed during hip arthroscopy, in cam FAI, pincer, and mixed-type hip pathologies? (2) Are specific cartilage wear patterns associated with duration of symptoms, age, and/or BMI?

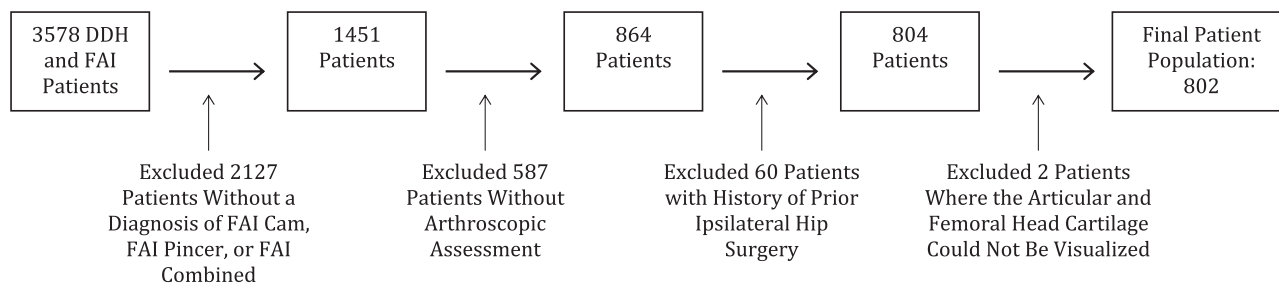


Fig. 1 Flowchart shows final cohort and reasons for exclusion. DDH = developmental dysplasia of the hip.

Patients and Methods

A total of 3578 patients who underwent a surgical procedure between January 2009 and November 2016 for the treatment of symptomatic FAI were identified using a longitudinally maintained database and a longitudinal cohort from the senior author (JCC) [6]. We excluded patients who did not have a diagnosis of FAI; those without arthroscopic assessment of the hip; those with previous ipsilateral surgery; patients with sequelae of childhood disease such as Legg-Calvé-Perthes disease, slipped capital femoral epiphysis, or other associated neurologic disorders; and those with acetabular or femoral head cartilage that could not be visualized during arthroscopy. A cohort of 802 patients were identified for this multicenter, observational study (Fig. 1). After obtaining informed consent for participation in this study, we documented patient demographics including sex, age, BMI, and pain chronicity. Pain was characterized as none, slight, mild, moderate, severe, or disabling. Significant symptoms necessitated the presence of at least moderate pain to consider a symptomatic hip. All patients in the study had persistent hip pain that was refractory to at least 3 months of nonoperative treatment (activity modification, nonsteroidal anti-inflammatory drugs, and physical therapy). None of the included hips had advanced osteoarthritis (Tönnis Grade

III-IV [22]). We documented preoperative diagnoses, radiographic parameters, and operative findings. Each treating surgeon at each institution diagnosed FAI using the minimum basic criteria of pain in the affected hip for a period of > 3 months, hip ROM, and radiographs. The diagnosis of FAI was characterized by abnormal repetitive abutment of the proximal femur and acetabular rim that led to patient-reported dysfunction of the hip (pain, activity limitation, motion restriction) [6]. Indications for hip arthroscopy was decided by each ANCHOR surgeon based on the mentioned criteria. This study was approved by each participating institution’s review board.

The treating physician determined the type of FAI based on previously published criteria [7]. All radiographs were done using a standardized protocol including a supine AP pelvis and frog lateral radiograph. Interobserver and intraobserver reliability of the radiographic analysis of FAI was previously performed by our group [18]. The decision to use a frog lateral view, in addition to an AP view of the pelvis, was based on previous studies in which radiographs were compared with CT for the assessment of cam deformity. The addition of the frog lateral view to the AP of the pelvis resulted in having the highest specificity for detecting cam lesions out of any other radiographic view [17].

Operative findings were recorded during hip arthroscopy on the basis of a combination of prospectively recorded operative findings (100% of patients) as previously described [16]. We used the Beck classification [4] to classify acetabular and femoral head cartilage damage by location and severity (Table 1). Previously, our group has performed intra- and interobserver reliability for arthroscopic scoring of cartilage lesions using the Beck classification, which showed substantial interobserver reliability (average kappa coefficient (κ) = 0.62; range, 0.48-0.78) and an overall agreement rate of 81.7% [16]. Cartilage wear was defined as any cartilage lesion equal to or greater than Grade 2, such as roughening of the surface or fibrillation at any location of the acetabulum or femoral head. The pattern of cartilage wear was represented by the mean grade of wear for each location on both the acetabulum and femoral head for each

Table 1. Articular cartilage wear classification

Description	Criteria
1: Normal	Macroscopically sound cartilage
2: Malacia	Roughening of surface, fibrillation
3: Debonding	Loss of fixation to the subchondral bone, macroscopically sound cartilage; carpet phenomenon
4: Cleavage	Loss of fixation to the subchondral bone; frayed edges, thinning of the cartilage, flap
5: Defect	Full-thickness defect

For each specific location, the average cartilage wear was reported; cartilage wear was defined as the presence of a grade > 1 lesion.

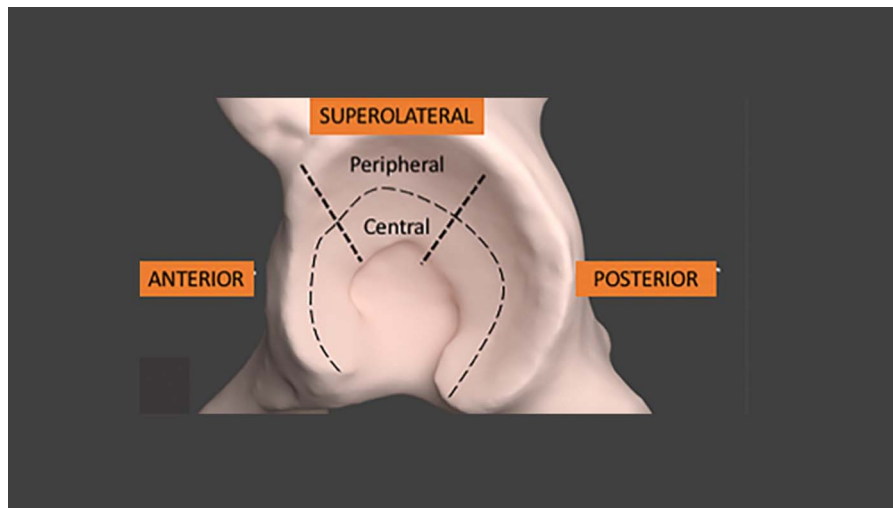


Fig. 2 For each zone, the surgeon was requested to describe the worst chondromalacia for each section involved using the 1, 2, 3, 4, and 5 grading system [1]. The acetabulum was divided into central and peripheral zones. Three anatomic locations were defined as anterior, superolateral, and posterior.

corresponding abnormal hip pathology (cam, pincer, and mixed FAI). For each zone, the surgeon was requested to describe the worst chondromalacia for each section involved using the 1, 2, 3, 4, and 5 Beck grading system. When multiple lesions were present, all were characterized; however, for purposes of analysis, the most severe lesion alone was utilized [4]. The acetabular lesions were localized into the anterior, superolateral, and posterior quadrants (peripheral and central) (Fig. 2). Femoral head cartilage wear was identified at the anterolateral, anteromedial, posterolateral, and posteromedial areas.

Statistical Analysis

We reported frequencies of patient demographics, radiographic measurements, and surgical visualization of the presence of articular cartilage damage. To test for differences in demographic and radiographic characteristics across FAI diagnoses, we conducted Wald chi-square tests for categorical variables and one-way analyses of variance (ANOVAs) for continuous variables. Mean grades of acetabular and femoral articular cartilage damage were reported along with standard errors. Wald chi-square tests were used to evaluate the differences in patterns of acetabular and femoral cartilage wear across FAI diagnoses and pain chronicity (pain for < 1 year, 1-3 years, > 3-5 years, and > 5 years). Chi-square trend tests were used to evaluate statistically significant trends in patterns of acetabular and femoral cartilage wear across age (< 30, 30-50, and > 50 years) and BMI (< 30 and ≥ 30 kg/m²) groups. Fisher's exact tests were calculated in place of Wald chi-square tests for

variables where expected cell counts were < 5. One-way ANOVAs were calculated to evaluate for differences in mean grade of wear across FAI subgroups, pain chronicity, age, and BMI. A bivariate logistic regression model was used to identify factors independently associated with the presence of cartilage wear in the acetabulum and femoral head. All statistical tests were two-sided and a p value of < 0.05 was considered to be statistically significant. All analyses were performed using SAS 9.4 (SAS Institute Inc, Cary, NC, USA).

Results

A total of 802 patients (802 hips) met all inclusion criteria and were included in the final study population. Four hundred seventy-two patients (58%) had a clinical diagnosis of cam FAI, 290 patients (36%) combined FAI, and 40 patients (6%) pincer FAI (Table 2). The mean age at surgery was 32.1 ± 12 years and average BMI was 25.1 ± 4.5 kg/m². Women made up 58% (469) of the study population and men 42% (333). Hip symptom duration before surgery varied with the most common timeframe being 1 to 3 years (45%) followed by 6 to 12 months (33%). Average lateral center-edge angle (LCEA), AP α -angle, frog α -angle, acetabular inclination (AI) angle, and anterior center edge (ACE) angle taken from radiographs were $29.0^\circ \pm 6.7^\circ$, $55.0^\circ \pm 17^\circ$, $53.0^\circ \pm 17^\circ$, $5.96^\circ \pm 6.52^\circ$, and $31.2^\circ \pm 7.9^\circ$, respectively (Table 2). Overall, acetabular cartilage wear was identified in 743 of 802 hips (93%) and femoral head cartilage wear in 130 of 802 hips (16%) (Table 3).

Table 2. Patient demographics in the study population and across FAI hip pathologies

Variables	Total (n = 802)	Cam FAI (n = 472)	Pincer FAI (n = 40)	Combined FAI (n = 290)	p value
Age at surgery (years; mean ± SD)	32 ± 12	32 ± 13	34 ± 12	31 ± 12	0.086
Sex, number (%)					< 0.001
Male	333 (41.5)	180 (38.1)	7 (17.5)	146 (50.3)	
Female	469 (58.5)	292 (61.9)	33 (82.5)	144 (49.7)	
BMI (kg/m ² ; mean ± SD)	25.1 ± 4.5	24.8 ± 4.4	26.3 ± 4.6	25.6 ± 4.8	0.017
Pain chronicity					0.717
< 1 year	261 (32.6)	149 (31.6)	15 (37.5)	97 (33.6)	
1-3 years	358 (44.8)	211 (44.8)	19 (47.5)	128 (44.3)	
3-5 years	94 (11.8)	55 (11.7)	5 (12.5)	34 (11.8)	
> 5 years	87 (10.9)	56 (11.9)	1 (2.5)	30 (10.4)	
LCEA (frequency, % of total)					< 0.001
LCEA ≤ 25	237 (30.0)	173 (37.5)	7 (17.5)	57 (19.9)	
25 > LCEA < 35	409 (51.8)	236 (51.1)	11 (27.5)	162 (56.5)	
35 ≥ LCEA	143 (18.1)	53 (11.5)	22 (55.0)	68 (23.7)	
Mean ± SD	29.0 ± 6.7	27.5 ± 6.0	35.7 ± 9.7	30.5 ± 6.4	< 0.001
AP α-angle (frequency, % of total)*					0.013
α-angle < 55	167 (66.5)	109 (69.9)	12 (92.3)	46 (56.1)	
55 ≥ α-angle	84 (33.5)	47 (30.1)	1 (7.7)	36 (43.9)	
Mean ± SD	55.0 ± 17	53.8 ± 17	44.1 ± 6.14	59.0 ± 17.8	0.005
Frog lateral α-angle (frequency, % of total) [†]					0.052
α-angle < 55	366 (60.6)	228 (62.8)	17 (77.3)	121 (55.3)	
55 ≥ α-angle	238 (39.4)	135 (37.2)	5 (22.7)	98 (44.8)	
Mean ± SD	53.0 ± 12.8	52.8 ± 12.5	47.9 ± 10.6	53.9 ± 13.5	0.102
AI angle (frequency; mean ± SD)	5.96 ± 6.52	7.01 ± 6.65	2.77 ± 9.90	4.71 ± 5.27	< 0.001
ACE angle (frequency; mean ± SD)	31.2 ± 7.85	29.5 ± 7.75	36.9 ± 7.83	33.2 ± 7.31	< 0.001

*Five hundred fifty-one missing data points from AP α-angle were excluded from the analysis.

†198 missing data points from frog lateral α-angle were excluded from the analysis; Wald chi-square p values were calculated to test for differences in frequencies between FAI groups; one-way analysis of variance p values were calculated to test for differences in means between FAI groups; data points with missing values were excluded from the analysis, variables missing < 10 data points were not specified with an asterisk because the missing numbers were negligible in affecting the significance of association with FAI hip pathologies; FAI = femoroacetabular impingement; BMI = body mass index; LCEA = lateral center-edge angle; AI = acetabular inclination; ACE = anterior center edge.

Acetabulum and Femoral Head Cartilage Wear Frequency and Severity by Cam, Pincer, and Mixed-type FAI Hip Pathologies

FAI hip pathology was associated with patterns of acetabular cartilage wear in several quadrants; specifically, we observed more frequent and severe debonding acetabular cartilage lesions in patients with symptomatic cam and mixed FAI hip pathologies (Table 3). Superolateral peripheral cartilage lesions occurred more frequently and with greater severity in patients with cam (90% [416 of 472] prevalence, 3.1 ± 1.1 grade) and mixed (91% [260 of 290] prevalence, 3.1 ± 1.1 grade) FAI compared with pincer (60% [24 of 40]

prevalence, 2.2 ± 1.1 grade) FAI hip pathologies (p < 0.001). Posterior peripheral rim cartilage lesions were also observed in 27% (127 of 472) of patients with cam FAI and 30% (85 of 290) of patients with mixed FAI, although the prevalence of cartilage wear did not differ significantly by hip pathology (Table 4). Overall, the pincer group presented with less frequent cartilage wear in all acetabular quadrants compared with cam FAI and mixed-type FAI. Compared with cam FAI and mixed type, lesions in the pincer group were evenly distributed in the anterior peripheral rim (64% [25 of 40]) and superolateral peripheral rim (60% [24 of 40]) (Fig. 3). FAI hip pathology was not significantly associated with any cartilage wear patterns in the femoral head (Table 4).

Table 3. Prevalence of articular cartilage damage between different subgroups

Cartilage wear	Total (n = 802)	Cam FAI (n = 472)	Pincer FAI (n = 40)	Combined FAI (n = 290)	p value
Acetabular chondromalacia					
Yes	743 (93)	435 (93)	30 (75)*	278 (96.5)	< 0.001
No	54 (6.8)	34 (7.3)	10 (25)	10 (3.5)	
Average grade (mean ± SD)	1.72 ± 1.14	1.73 ± 1.14	1.45 ± 0.88	1.73 ± 1.16	
Femoral head chondromalacia					
Yes	130 (16.4)	83 (17.8)	9 (23)	38 (13)	0.130
No	664 (83.6)	384 (82)	30 (77)	250 (86.8)	
Average grade (mean ± SD)	1.15 ± 0.64	1.17 ± 0.70	1.15 ± 0.59	1.11 ± 0.56	

Values represented as number (%); Wald chi-square p values were calculated to test for differences in frequencies between FAI groups; FAI = femoroacetabular impingement.

Acetabulum and Femoral Head Cartilage Wear Frequency and Severity Patterns by Pain Chronicity, Age, and BMI

Older patients were more likely to demonstrate a higher frequency and severity of cartilage lesions on both the acetabular and femoral sides, whereas longer duration of symptoms and higher BMI showed only small and isolated increases in the frequency and grade of lesions.

Specifically in the acetabulum, patients older than 50 years of age had a higher prevalence and graded severity of cartilage wear compared with patients younger than 30 years of age in the anterior central (14% versus 2%, $p < 0.001$), anterior peripheral (89% versus 67%, $p < 0.001$; 2.7 ± 1.1 versus 2.3 ± 1.2 , $p > 0.001$), superolateral central (21% versus 2%, $p < 0.001$; 1.3 ± 0.7 versus 1.1 ± 0.4 , $p = 0.003$), superolateral peripheral (92% versus 82%, $p < 0.001$; 3.4 ± 1.1 versus 2.8 ± 1.1 , $p < 0.001$), posterior central (13% versus 1%, $p < 0.001$; 1.2 ± 0.8 versus 1.0 ± 0.2 , $p < 0.001$), and posterior peripheral (57% versus 16%, $p < 0.0001$; 2.1 ± 1.3 versus 1.2 ± 0.6 , $p < 0.001$) acetabular quadrants. In the femoral head, patients older than 50 years of age had a higher prevalence and graded severity of cartilage wear compared with patients younger than 30 years of age in the posterolateral (19% versus 0.3%, $p < 0.001$; 1.4 ± 1.0 versus 1.0 ± 0.1 , $p < 0.001$), anterolateral (30% versus 3%, $p < 0.0001$; 1.6 ± 1.2 versus 1.0 ± 0.2 , $p < 0.001$), anteromedial (25% versus 1%, $p < 0.001$; 1.6 ± 1.2 versus 1.0 ± 0.2 , $p < 0.001$), and posteromedial (18% versus 1%, $p < 0.001$; 1.6 ± 1.3 versus 1.0 ± 0.2 , $p < 0.001$) femoral head quadrants (Table 5). In bivariate logistic regression analysis, increasing age was an independent risk factor for the presence of cartilage wear in the acetabulum (odds ratio [OR], 1.05; 95% confidence interval [CI], 1.02-1.07; $p = 0.005$) and femoral head (OR, 1.08; 95% CI, 1.06-1.1; $p < 0.001$) (Table 6).

Regarding pain chronicity, patients with a longer duration of pain symptoms had a higher prevalence of

cartilage wear in the anterior peripheral acetabular rim (87% in 3- to 5-year pain versus 72% in < 1-year pain, $p = 0.033$) and posterior peripheral acetabular rim (42% in > 5-year pain versus 24% in < 1-year pain, $p = 0.001$). Grade of wear in the posterior peripheral acetabulum was also higher in severity in patients with longer pain chronicity (1.7 ± 1.0 in > 5-year pain versus 1.4 ± 0.9 in < 1-year pain, $p = 0.027$). Pain chronicity was not associated with differences in cartilage wear in the anterior central, superolateral, or posterior central acetabulum or any quadrants in the femoral head (Table 5). Pain chronicity was not associated with prevalence of cartilage wear in the acetabulum or femoral head in bivariate logistic regression analysis (Table 6).

In the acetabulum, a BMI ≥ 30 kg/m² was associated with a higher prevalence and greater severity of cartilage wear in the posterior peripheral cartilage rim compared with a BMI < 30 kg/m² (42% versus 26%, $p = 0.006$; 1.9 ± 1.3 versus 1.4 ± 0.9 , $p < 0.001$). BMI was not associated with differences in cartilage wear in the anterior, superolateral, or posterior central acetabulum. In the femoral head, a higher BMI was associated with a higher prevalence of wear in the anterolateral quadrant (20% versus 9%, $p = 0.006$) as well as a higher prevalence and grade of wear in the anteromedial quadrant (15% versus 6%, $p = 0.002$; 1.3 ± 0.8 versus 1.1 ± 0.6 , $p = 0.04$). BMI was not associated with differences in cartilage wear in the posterolateral or posteromedial quadrants of the femoral head (Table 5). In bivariate logistic regression analysis, higher BMI was an independent risk factor for presence of cartilage wear in the femoral head (OR, 1.06; 95% CI, 1.02-1.11; $p = 0.002$) but not the acetabulum (Table 6).

Discussion

FAI is a structural hip deformity that has been linked to premature intraarticular degenerative changes [9, 24]. A specific pattern of cartilage wear has been reported

Table 4. Acetabular and femoral head articular damage distribution across FAI diagnoses

Location of cartilage wear	Total (n = 802)	Cam FAI (n = 472)	Pincer FAI (n = 40)	Mixed FAI (n = 290)	p value
Acetabular cartilage damage					
Anterior central					
Presence of wear, number (%)	33 (4.3)	26 (5.7)	0*	7 (2.5)	0.045
Grade of wear, mean \pm SD	1.07 \pm 0.41	1.09 \pm 0.45	1	1.05 \pm 0.38	0.240
Anterior peripheral					
Presence of wear, number (%)	607 (76.8)	351 (75.8)	25 (64.1)	231 (80.2)	0.059
Grade of wear, mean \pm SD	2.51 \pm 1.20	2.48 \pm 1.19	2.13 \pm 1.03	2.59 \pm 1.21	0.065
Superolateral central					
Presence of wear, number (%)	41 (5.3)	32 (7.0)	1 (2.6)*	8 (2.9)	0.036
Grade of wear, mean \pm SD	1.09 \pm 0.47	1.12 \pm 0.52	1.03 \pm 0.16	1.06 \pm 0.41	0.172
Superolateral peripheral					
Presence of wear, number (%)	700 (89)	416 (89.9)	24* (60.0)	260 (91.2)	< 0.001
Grade of wear, mean \pm SD	3.05 \pm 1.09	3.07 \pm 1.05	2.15 \pm 1.14*	3.13 \pm 1.09	< 0.001
Posterior central					
Presence of wear, number (%)	32 (4.2)	25 (5.6)	0	7 (2.5)	0.054
Grade of wear, mean \pm SD	1.06 \pm 0.36	1.07 \pm 0.36	1	1.05 \pm 0.37	0.382
Posterior peripheral					
Presence of wear, number (%)	219 (28.2)	127 (27.8)	7 (18.4)	85 (30.3)	0.299
Grade of wear, mean \pm SD	1.49 \pm 0.97	1.51 \pm 1.00	1.37 \pm 0.88	1.48 \pm 0.92	0.668
Femoral head cartilage damage					
Posterolateral					
Presence of wear, number (%)	38 (5.2)	24 (5.6)	2 (6.3)	12 (4.3)	0.729
Grade of wear, mean \pm SD	1.13 \pm 0.65	1.15 \pm 0.68	1.22 \pm 0.87	1.10 \pm 0.56	0.490
Anterolateral					
Presence of wear, number (%)	83 (10.8)	49 (11.0)	6 (15.8)	28 (9.9)	0.539
Grade of wear, mean \pm SD	1.18 \pm 0.65	1.19 \pm 0.68	1.21 \pm 0.58	1.16 \pm 0.61	0.816
Anteromedial					
Presence of wear, number (%)	56 (7.4)	38 (8.7)	4 (10.8)	14 (5.0)	0.131
Grade of wear, mean \pm SD	1.14 \pm 0.60	1.17 \pm 0.67	1.16 \pm 0.55	1.09 \pm 0.48	0.211
Posteromedial					
Presence of wear, number (%)	36 (5.1)	26 (6.3)	0	10 (3.8)	0.148
Grade of wear, mean \pm SD	1.14 \pm 0.68	1.18 \pm 0.76	1	1.10 \pm 0.58	0.195

Wald chi-square p values were calculated to test for differences in frequencies between FAI groups; one-way analysis of variance p values were calculated to test for differences in means between FAI groups; acetabular and femoral head articular damage distribution across FAI diagnoses; presence of wear was defined as those with a grade > 1 of cartilage damage; grade of wear was reported using the mean grades of acetabular and femoral articular cartilage damage (grade 1 to 5) along with standard errors. *statistical difference; FAI = femoroacetabular impingement.

previously in the acetabulum of patients with hip FAI with typical cartilage lesions observed in the anterosuperior peripheral rim [4]. Still, the effect of abnormal morphology in the femoral head and the rest of the acetabulum remains to be better defined. Moreover, the effect of patient characteristics in intraarticular cartilage wear in this population has not been previously clearly described. We found no association between diagnosis and cartilage wear patterns in the examined femoral heads, but we did find patterns on

the acetabular side of the joints that were associated with the various diagnoses; specifically, we observed more frequent and severe debonding of acetabular cartilage in patients with symptomatic cam and mixed FAI. Increasing age and higher BMI are also independent risk factors for cartilage wear. Patients older than 50 years of age presented with a higher prevalence and severity of cartilage wear in every location of the acetabulum and femoral head, suggesting advanced deterioration of articular cartilage in the

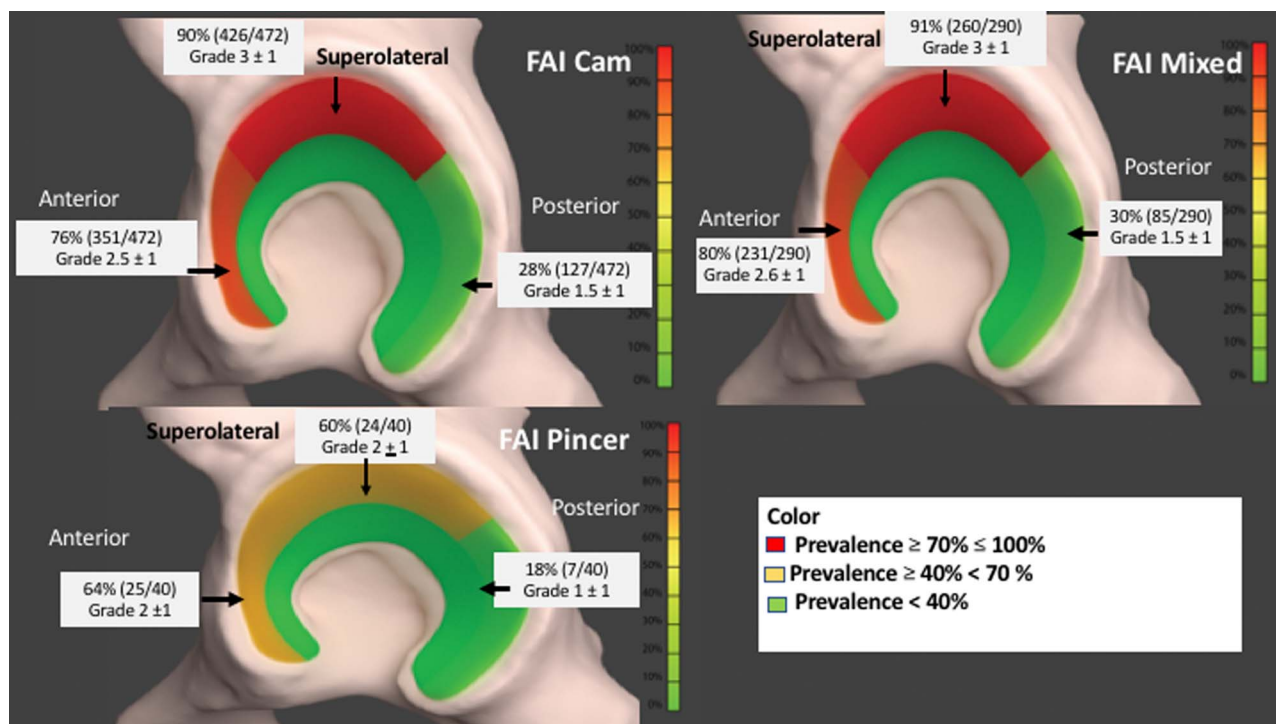


Fig. 3 A heat map was performed according to the prevalence of cartilage damage. Percent represents frequency of presence of cartilage wear. The grade is the average grade observed in each location for each pathology. Red color: 70%-100%, yellow color: $\geq 40 < 70$, and green: < 40 . Acetabular articular cartilage damage topographies across FAI diagnoses. Graphic design courtesy of Udayabhanu Jammalamadaka PhD.

older population. Patients with a higher BMI ($\geq 30 \text{ kg/m}^2$) and pain chronicity of > 3 years had higher cartilage wear in some locations of the acetabulum and femoral head. This information is important for patient selection for surgery, surgical planning, and treatment prognosis. Identification of patterns of cartilage wear is paramount to improving understanding of the physiopathology of hip derangement in FAI.

This study has a number of limitations. First, cartilage wear was graded by different observers, possibly limiting data reliability. However, our group has previously performed intra- and interobserver reliability for arthroscopic scoring of cartilage lesions using the Beck classification and showed substantial interobserver reliability, suggesting good agreement between raters [16]. Second, although clinical presentation, ROM, and radiographic measurements were used to diagnose FAI, there may be some variability between surgeons as is a limitation from doing multicenter studies. Third, patients with a clinical diagnosis of FAI were included only if they had undergone hip arthroscopy. This may omit patients who did not have intraarticular pathology and thus were not scheduled for hip arthroscopy, suggesting a higher prevalence of intraarticular lesions than would be observed if all patients with symptomatic FAI were included. Fourth, we do not have an

unaffected control group to compare patterns of cartilage wear. Fifth, from a total of 1389 hips identified with a clinical diagnosis of FAI, only 802 were able to be included in the final cohort because not all locations from the acetabulum and femoral head were visualized during hip arthroscopy, possibly reducing the internal validity of this study. We still believe this study is reporting one of the largest cohorts of patients with a clinical diagnosis of FAI in which intraarticular patterns of cartilage wear were investigated. Finally, radiographic measures were performed by different observers, possibly limiting data reliability. However, we have previously shown acceptable interrater reliability for radiographic measurements used in this study proving good agreement between observers [18]. Additionally, the use of radiographs to assess three-dimensional (3-D) bone deformity has its limitations. To date, 3-D imaging (CT) is the gold standard for detection of femoral head-neck deformity [3]. However, plain radiographs remain the initial diagnostic examination for FAI. All our patients were assessed with a complete series of radiographs including AP, 45° Dunn view, and the frog lateral view. Previous authors have proposed that this three-view series is diagnostic for most patients without the need for additional radiation exposure from cross-table radiographs or 3-D imaging/CT [17].

Table 5. Acetabulum and femoral head cartilage wear frequency and severity patterns by pain chronicity, age, and BMI

Pain-age and BMI	Pain chronicity*					Age at surgery†				BMI‡		
	< 1 year (n = 261)	1-3 years (n = 358)	3-5 years (n = 94)	< 5 years (n = 87)	p value	x ≤ 30 (n = 365)	30 < x < 50 (n = 371)	x ≥ 50 (n = 66)	p value	x < 30 (n = 677)	x ≥ 30 (n = 117)	p value
Acetabular articular cartilage damage												
Anterior central												
Presence of wear, number (%)	11 (4.4)	14 (4.1)	2 (2.3)	6 (7.1)	0.494	7 (1.9)	17 (4.9)	9 (13.9)	< 0.001	28 (4.3)	5 (4.5)	0.804
Grade of wear, mean ± SD	1.09 ± 0.46	1.07 ± 0.40	1.02 ± 0.15	1.11 ± 0.49	0.534	1.05 ± 0.38	1.08 ± 0.44	1.15 ± 0.40	0.146	1.07 ± 0.41	1.08 ± 0.45	0.854
Anterior peripheral												
Presence of wear, number (%)	186 (72.4)	271 (76.8)	80 (87.0)	69 (80.2)	0.033	242 (67.0)	306 (84.3)	59 (89.4)	< 0.001	508 (76.3)	94 (81.0)	0.261
Grade of wear, mean ± SD	2.44 ± 1.24	2.51 ± 1.18	2.58 ± 1.12	2.65 ± 1.23	0.483	2.28 ± 1.15	2.70 ± 1.22	2.67 ± 1.11	< 0.001	2.49 ± 1.19	2.62 ± 1.23	0.294
Superolateral central												
Presence of wear, number (%)	10 (4.0)	17 (4.9)	5 (5.5)	9 (10.6)	0.145	7 (1.9)	20 (5.7)	14 (21.2)	< 0.001	33 (5.0)	8 (7.1)	0.358
Grade of wear, mean ± SD	1.08 ± 0.46	1.08 ± 0.41	1.10 ± 0.47	1.19 ± 0.66	0.251	1.05 ± 0.42	1.09 ± 0.46	1.30 ± 0.68	< 0.001	1.08 ± 0.42	1.17 ± 0.70	0.064
Superolateral peripheral												
Presence of wear, number (%)	224 (86.8)	310 (88.6)	84 (91.3)	80 (93.0)	0.368	295 (81.9)	344 (95.0)	61 (92.4)	< 0.001	589 (88.6)	105 (91.3)	0.388
Grade of wear, mean ± SD	3.03 ± 1.13	2.98 ± 1.08	3.16 ± 1.06	3.24 ± 1.05	0.150	2.84 ± 1.08	3.19 ± 1.06	3.44 ± 1.14	< 0.001	3.03 ± 1.08	3.23 ± 1.16	0.073
Posterior central												
Presence of wear, number (%)	5 (2.0)	16 (4.7)	4 (4.5)	7 (8.3)	0.062	5 (1.4)	19 (5.4)	8 (12.5)	< 0.001	29 (4.5)	3 (2.8)	0.606
Grade of wear, mean ± SD	1.02 ± 0.18	1.07 ± 0.38	1.08 ± 0.46	1.12 ± 0.50	0.146	1.02 ± 0.15	1.07 ± 0.38	1.23 ± 0.77	< 0.001	1.07 ± 0.38	1.04 ± 0.23	0.432
Posterior peripheral												
Presence of wear, number (%)	61 (23.9)	87 (25.4)	35 (38.0)	35 (41.7)	0.001	56 (15.6)	126 (35.8)	37 (56.9)	< 0.001	171 (26.1)	47 (42.0)	< 0.001
Grade of wear, mean ± SD	1.42 ± 0.90	1.45 ± 0.94	1.68 ± 1.10	1.68 ± 1.04	0.027	1.21 ± 0.59	1.66 ± 1.12	2.09 ± 1.25	< 0.001	1.43 ± 0.89	1.88 ± 1.28	< 0.001

Table 5. continued

Pain-age and BMI	Pain chronicity*					Age at surgery [†]				BMI [‡]		
	< 1 year (n = 261)	1-3 years (n = 358)	3-5 years (n = 94)	< 5 years (n = 87)	p value	x ≤ 30 (n = 365)	30 < x < 50 (n = 371)	x ≥ 50 (n = 66)	p value	x < 30 (n = 677)	x ≥ 30 (n = 117)	p value
Femoral head articular cartilage damage												
Posterolateral												
Presence of wear, number (%)	13 (5.4)	14 (4.2)	4 (4.8)	7 (8.5)	0.450	1 (0.3)	25 (7.6)	12 (19.4)	< 0.001	31 (4.9)	7 (6.9)	0.414
Grade of wear, mean ± SD	1.12 ± 0.60	1.11 ± 0.58	1.16 ± 0.76	1.24 ± 0.88	0.374	1.00 ± 0.05	1.21 ± 0.83	1.42 ± 1.03	< 0.001	1.12 ± 0.62	1.21 ± 0.84	0.230
Anterolateral												
Presence of wear, number (%)	25 (9.9)	38 (11.2)	12 (13.6)	8 (9.4)	0.758	9 (2.5)	55 (15.8)	19 (29.7)	< 0.001	60 (9.2)	22 (20.2)	<0.001
Grade of wear, mean ± SD	1.17 ± 0.62	1.19 ± 0.66	1.23 ± 0.72	1.15 ± 0.59	0.873	1.03 ± 0.22	1.26 ± 0.75	1.59 ± 1.18	< 0.001	1.16 ± 0.63	1.29 ± 0.74	0.051
Anteromedial												
Presence of wear, number (%)	16 (6.4)	28 (8.4)	7 (8.2)	5 (6.0)	0.764	5 (1.4)	35 (10.3)	16 (25.0)	< 0.001	39 (6.1)	16 (14.7)	0.002
Grade of wear, mean ± SD	1.13 ± 0.59	1.14 ± 0.58	1.18 ± 0.71	1.12 ± 0.57	0.913	1.03 ± 0.24	1.18 ± 0.65	1.56 ± 1.18	< 0.001	1.12 ± 0.57	1.25 ± 0.76	0.041
Posteromedial												
Presence of wear, number (%)	15 (6.4)	12 (3.8)	3 (3.8)	6 (7.7)	0.309	3 (0.9)	22 (7.0)	11 (18.3)	< 0.001	29 (4.8)	7 (7.1)	0.340
Grade of wear, mean ± SD	1.15 ± 0.68	1.12 ± 0.65	1.15 ± 0.76	1.18 ± 0.73	0.882	1.02 ± 0.23	1.19 ± 0.80	1.55 ± 1.29	< 0.001	1.13 ± 0.66	1.21 ± 0.85	0.274

Acetabular and femoral head articular damage distribution across pain chronicity, age, and BMI; Wald chi-square tests were used to calculate p values to test for differences in frequencies between.

*pain chronicity groups; chi-square trend tests were used to calculate two-sided p values to test for differences between.

†age at surgery groups and.

‡BMI groups; Fisher's exact tests were used to calculate p values in place of Wald chi-square tests for variables with expected cell counts of < 5; one-way analysis of variance p values were calculated to test for differences in means among.

Table 6. Bivariate logistic regression model: presence of articular cartilage damage by pain chronicity (categorical), age (categorical), and BMI (categorical)

Patient's demographic variables	Acetabular articular cartilage Presence of wear		Femoral head articular cartilage Presence of wear	
	*OR (95% CI)	†p value	*OR (95% CI)	†p value
Pain chronicity				
> 1 year	Reference		Reference	
1-3 years	1.28 (0.70-2.33)	0.481	1.20 (0.77-1.87)	0.788
3-5 years	1.65 (0.61-4.48)	0.838	1.25 (0.66-2.37)	0.996
> 5 years	2.56 (0.75-8.77)	0.261	1.61 (0.86-3.02)	0.236
Age at surgery	1.05 (1.02-1.07)	< 0.001	1.08 (1.06-1.10)	< 0.001
BMI	1.02 (0.96-1.09)	0.543	1.06 (1.02-1.11)	0.002

*Logistic regression model, results reported in odds ratio and 95% confidence interval (reference = 1.00).

†Wald chi-square; BMI = body mass index; OR = odds ratio; CI = confidence interval.

We found different patterns of acetabular cartilage wear with different forms of FAI, but no differences in the patterns of femoral head wear. Murray [14] was the first to suggest a relation between abnormal morphology in the hip and subsequent development of hip osteoarthritis. Four decades later, Ganz et al. [8] proposed a mechanism of FAI in hips with early joint degeneration. He identified two types of impingement, including pincer and cam. He proposed that patients with cam FAI presented a typical cartilage delamination of the superolateral aspect of the rim; however, this early report did not describe specific locations of cartilage wear throughout the whole acetabulum and femoral head. Later, Beck et al. [4] was the first to describe specific patterns of articular cartilage wear in the FAI population. After evaluating 149 patients who underwent surgical dislocation for the treatment of symptomatic FAI, the authors observed a pattern of cartilage wear specific to cam FAI with a typical debonding lesion in the anterosuperior aspect of the acetabulum. Authors also proposed that contrary to the cam FAI physiopathology, the mechanism of impingement in pincer FAI was secondary to an excessive coverage of the femoral head, resulting in a typical circumferential chondromalacia lesion over the rim. These results are similar to ours; however, femoral head lesions were not reported, and the effects of age, BMI, and pain chronicity were not assessed either. In addition, hips were classified either as cam FAI or pincer FAI; no patterns of cartilage wear were reported in mixed FAI. Moreover, observations from Beck et al. [4] were performed under direct visualization and not under an arthroscopic view, which may have missed a high percentage of early articular cartilage lesions (Grade 2). Most contemporary studies trying to define cartilage wear patterns under arthroscopy visualization have focused on acetabular cartilage damage [20]. A large amount of studies report cartilage wear in the anterior and superolateral aspects of the rim [1, 5, 10]. Our study shows a pattern of

cartilage wear similar to previous studies [4, 5, 11, 21] with the highest frequency and severity of cartilage lesions in the superolateral aspect of the acetabulum in hips with cam and mixed FAI. However, we also found a high prevalence of posterior cartilage wear in the acetabulum of patients with cam and mixed-type FAI. These lesions were predominantly mild cartilage lesions (malacia), suggesting that the pathologic process involved in the posterior region is not the same as that seen in the superolateral rim (debonding). We believe this pattern of wear could be related to either a more advanced stage of joint degeneration or to increased contact stresses between the posteromedial aspect of the femoral head and the posterior rim of the acetabulum as the impingement occurs at the anterosuperior rim and pushes the femoral head posteriorly. Previous studies using finite element methods to evaluate peak contact stresses in patients with cam FAI have shown that the most common location of peak stress in these patients is in the anterosuperior cartilage, corresponding to known areas of acetabular cartilage delamination [19]. However, the second maximum stress that was proposed by those authors was observed in the posteroinferior acetabulum, possibly secondary to chronic leverage of the femoral head within the acetabulum. Further studies will be needed to define whether this chronic overload could potentially be the initiation of the posterior cartilage wear observed in almost one-third of patients with cam and mixed-type FAI. Furthermore, as shown before by previous authors [1, 21], we found that the presence of a cam lesion or abnormal head-neck offset leads to more severe cartilage wear in the acetabulum. Contemporary approaches to correct this abnormal morphology with an osteochondroplasty have been shown to improve overall joint homeostasis; this study supports the idea that efforts should be made to correct this deformity during surgical intervention [2]. Restoration of the head-neck offset may be critical to prevent further development of intraarticular

derangement. Similar to other studies, we found that isolated pincer FAI had the least amount of cartilage damage in the acetabulum, suggesting that pincer morphology may be less deleterious to acetabular articular cartilage than FAI cam or mixed type [4].

Our cohort also shows that the prevalence of cartilage lesions in the femoral head, compared with the acetabulum, is lower, presenting in only 16% of the included patients. These lesions were mostly superficial and predominantly mild. Contrary to findings in the acetabulum, we did not observe any pattern of femoral cartilage wear among groups. There are few studies that have evaluated cartilage lesions in the femoral head of patients undergoing hip arthroscopy for the treatment of FAI. Like our results, the Danish registry reported 16% of cartilage damage in the femoral head of patients undergoing hip arthroscopy for the treatment of FAI [11]. Additionally, Bhatia et al. [5] reported a prevalence of advanced cartilage lesions in the femoral head in 24% of a cohort of 1097 patients who had hip arthroscopy for the treatment of FAI. The frequency of these advanced femoral head lesions was higher in older patients with longer chronicity of pain and joint space narrowing.

We have also demonstrated that increasing age is independently associated with an increased risk of cartilage wear in the acetabular cartilage and femoral head and that higher BMI is associated with the presence of cartilage wear only in the femoral head. Previous studies have shown that increasing age is an independent factor for acetabular chondromalacia [12, 15]. Unlike our study, none of these studies have evaluated the effect of age on femoral head cartilage lesions. McCormick et al. [13] showed that age was a contributor to poor postoperative outcomes with patients older than 40 years of age doing worse than those younger than 40 years of age. Uchida et al. [23] showed that BMI is an important predictor of poor arthroscopic outcomes when focusing on a population of patients with acetabular dysplasia. Collectively, these observations provide important information regarding patient evaluation for hip arthroscopy. In our practice, we now consider patient age and higher BMI as factors that may negatively affect hip arthroscopy outcomes. Patients older than 40 years are at particular risk for advanced intraarticular disease and may be suboptimal candidates for joint preservation surgery or may require more extensive surgical procedures.

In conclusion, hip morphology affects the pattern of acetabular cartilage wear. More frequent and severe cartilage lesions were observed in patients with symptomatic cam and mixed-type FAI. Increasing age is also an independent risk for cartilage wear in both the acetabulum and femoral head and higher BMI is an independent risk for cartilage wear in the femoral head. Surgical attempts to restore normal anatomy to avoid FAI should be performed

to potentially improve long-term joint homeostasis. In the future, prospective studies should provide further insight into the pathomechanics of early degenerative changes associated with hip FAI deformities.

References

1. Beaulé PE, Hynes K, Parker G, Kemp KA. Can the alpha angle assessment of cam impingement predict acetabular cartilage delamination? *Clin Orthop Relat Res*. 2012;470:3361-3367.
2. Beaulé PE, Speirs AD, Anwender H, Melkus G, Rakhra K, Frei H, Lamontagne M. Surgical Correction of Cam Deformity in Association with Femoroacetabular Impingement and Its Impact on the Degenerative Process within the Hip Joint. *J Bone Joint Surg Am*. 2017;99:1373-1381.
3. Beaulé PE, Zaragoza E, Motamedi K, Copelan N, Dorey FJ. Three-dimensional computed tomography of the hip in the assessment of femoroacetabular impingement. *J Orthop Res*. 2005; 23:1286-1292.
4. Beck M, Kalhor M, Leunig M, Ganz R. Hip morphology influences the pattern of damage to the acetabular cartilage: femoroacetabular impingement as a cause of early osteoarthritis of the hip. *J Bone Joint Surg Br*. 2005;87:1012-1018.
5. Bhatia S, Nowak DD, Briggs KK, Patterson DC, Philippon MJ. Outerbridge Grade IV Cartilage Lesions in the Hip Identified at Arthroscopy. *Arthroscopy*. 2016;32:814-819.
6. Clohisy JC, Baca G, Beaulé PE, Kim YJ, Larson CM, Millis MB, Podeszwa DA, Schoenecker PL, Sierra RJ, Sink EL, Sucato DJ, Trousdale RT, Zaltz I, Group AS. Descriptive epidemiology of femoroacetabular impingement: a North American cohort of patients undergoing surgery. *Am J Sports Med*. 2013;41: 1348-1356.
7. Clohisy JC, Carlisle JC, Beaulé PE, Kim YJ, Trousdale RT, Sierra RJ, Leunig M, Schoenecker PL, Millis MB. A systematic approach to the plain radiographic evaluation of the young adult hip. *J Bone Joint Surg Am*. 2008;(90 Suppl):447-66.
8. Ganz R, Leunig M, Leunig-Ganz K, Harris WH. The etiology of osteoarthritis of the hip: an integrated mechanical concept. *Clin Orthop Relat Res*. 2008;466:264-272.
9. Ganz R, Parvizi J, Beck M, Leunig M, Notzli H, Siebenrock KA. Femoroacetabular impingement: a cause for osteoarthritis of the hip. *Clin Orthop Relat Res*. 2003;112-120.
10. Kaya M, Suzuki T, Emori M, Yamashita T. Hip morphology influences the pattern of articular cartilage damage. *Knee Surg Sports Traumatol Arthrosc*. 2016;24:2016-2023.
11. Lund B, Nielsen TG, Lind M. Cartilage status in FAI patients - results from the Danish Hip Arthroscopy Registry (DHAR). *SICOT J*. 2017;344.
12. McClincy MP, Lebrun DG, Tepolt FA, Kim YJ, Yen YM, Kocher MS. Clinical and radiographic predictors of acetabular cartilage lesions in adolescents undergoing hip arthroscopy. *Am J Sports Med*. 2018;46:3082-3089.
13. McCormick F, Nwachukwu BU, Alpaugh K, Martin SD. Predictors of hip arthroscopy outcomes for labral tears at minimum 2-year follow-up: the influence of age and arthritis. *Arthroscopy*. 2012;28:1359-1364.
14. Murray RO. The aetiology of primary osteoarthritis of the hip. *Br J Radiol*. 1965;38:810-824.
15. Nepple JJ, Carlisle JC, Nunley RM, Clohisy JC. Clinical and radiographic predictors of intra-articular hip disease in arthroscopy. *Am J Sports Med*. 2011;39:296-303.
16. Nepple JJ, Larson CM, Smith MV, Kim YJ, Zaltz I, Sierra RJ, Clohisy JC. The reliability of arthroscopic classification of acetabular rim labrochondral disease. *Am J Sports Med*. 2012;40:2224-2229.

17. Nepple JJ, Martel JM, Kim YJ, Zaltz I, Clohisy JC, Group AS. Do plain radiographs correlate with CT for imaging of cam-type femoroacetabular impingement? *Clin Orthop Relat Res.* 2012; 470:3313-3320.
18. Nepple JJ, Martell JM, Kim YJ, Zaltz I, Millis MB, Podeszwa DA, Sucato DJ, Sink EL, Clohisy JC, Group AS. Interobserver and intraobserver reliability of the radiographic analysis of femoroacetabular impingement and dysplasia using computer-assisted measurements. *Am J Sports Med.* 2014;42:2393-2401.
19. Ng KC, Rouhi G, Lamontagne M, Beaulé PE. Finite element analysis examining the effects of cam FAI on hip joint mechanical loading using subject-specific geometries during standing and maximum squat. *HSS J.* 2012;8:206-212.
20. Redmond JM, Gupta A, Stake CE, Domb BG. The prevalence of hip labral and chondral lesions identified by method of detection during periacetabular osteotomy: arthroscopy versus arthrotomy. *Arthroscopy.* 2014;30:382-388.
21. Streit JJ, Levine A, Barrett IJ, Cooperman DR, Goldberg V. The shape of the proximal femur influences acetabular wear patterns over time. *Clin Orthop Relat Res.* 2013;471:478-485.
22. Tonnis D, Heinecke A. Diminished femoral antetorsion syndrome: a cause of pain and osteoarthritis. *J Pediatr Orthop.* 1991; 11:419-431.
23. Uchida S, Utsunomiya H, Mori T, Taketa T, Nishikino S, Nakamura T, Sakai A. Clinical and radiographic predictors for worsened clinical outcomes after hip arthroscopic labral preservation and capsular closure in developmental dysplasia of the hip. *Am J Sports Med.* 2016;44:28-38.
24. Wyles CC, Norambuena GA, Howe BM, Larson DR, Levy BA, Yuan BJ, Trousdale RT, Sierra RJ. Cam deformities and limited hip range of motion are associated with early osteoarthritic changes in adolescent athletes: a prospective matched cohort study. *Am J Sports Med.* 2017;45: 3036-3043.