

Hip Symposium Bern, Pre-course, 2023

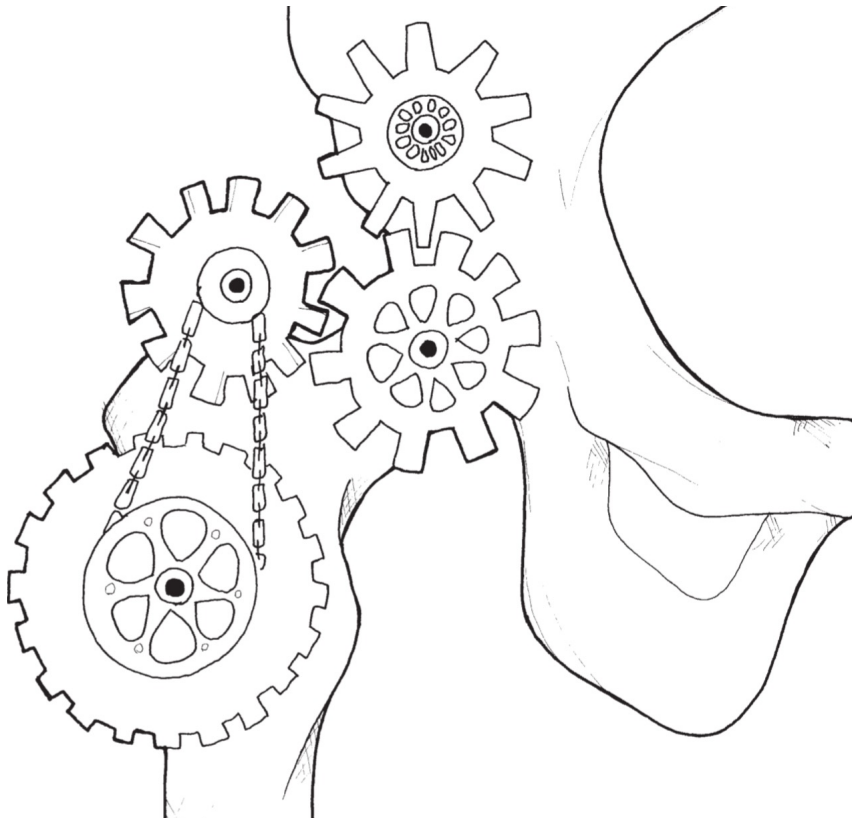
How it works – Pathomechanisms of the hip

Moritz Tannast

Professor and Chairman, Department of Orthopaedic Surgery & Traumatology

University of Fribourg, HFR Fribourg Hospital, Fribourg, Switzerland

Overview



The Normal Hip

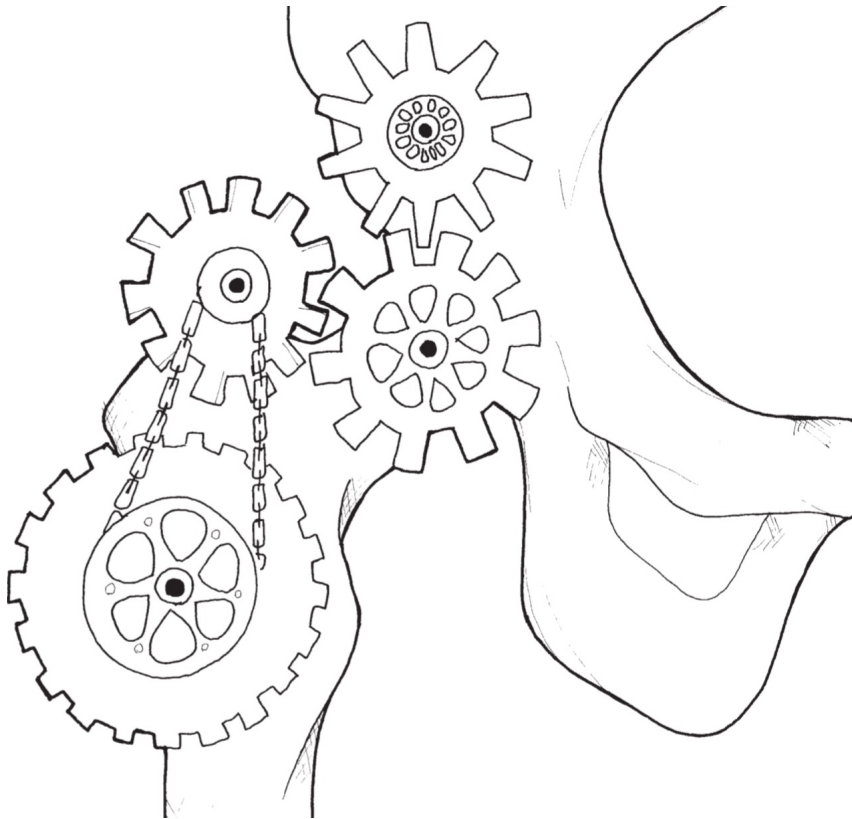
Dysplasia

Cam-Impingement

Pincer-Impingement

Femoral Maltorsion

Overview



The Normal Hip

Dysplasia

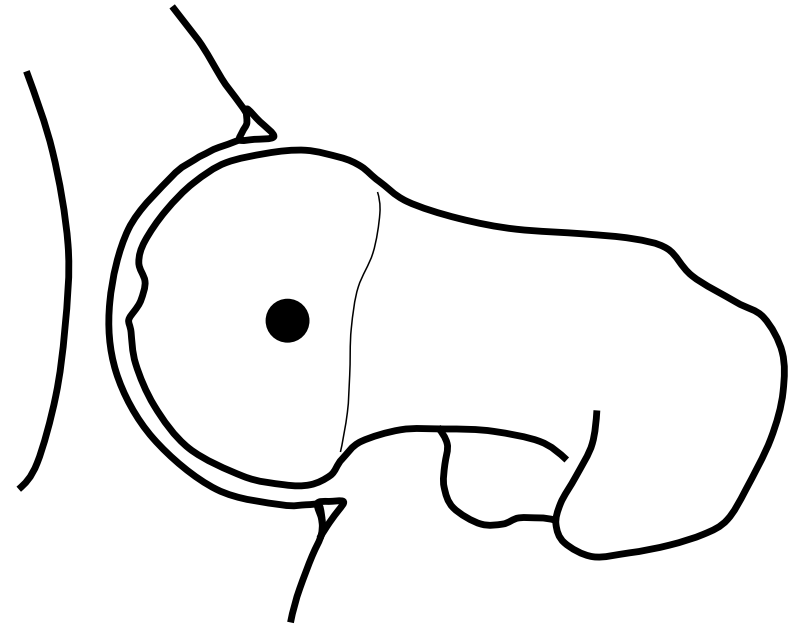
Cam-Impingement

Pincer-Impingement

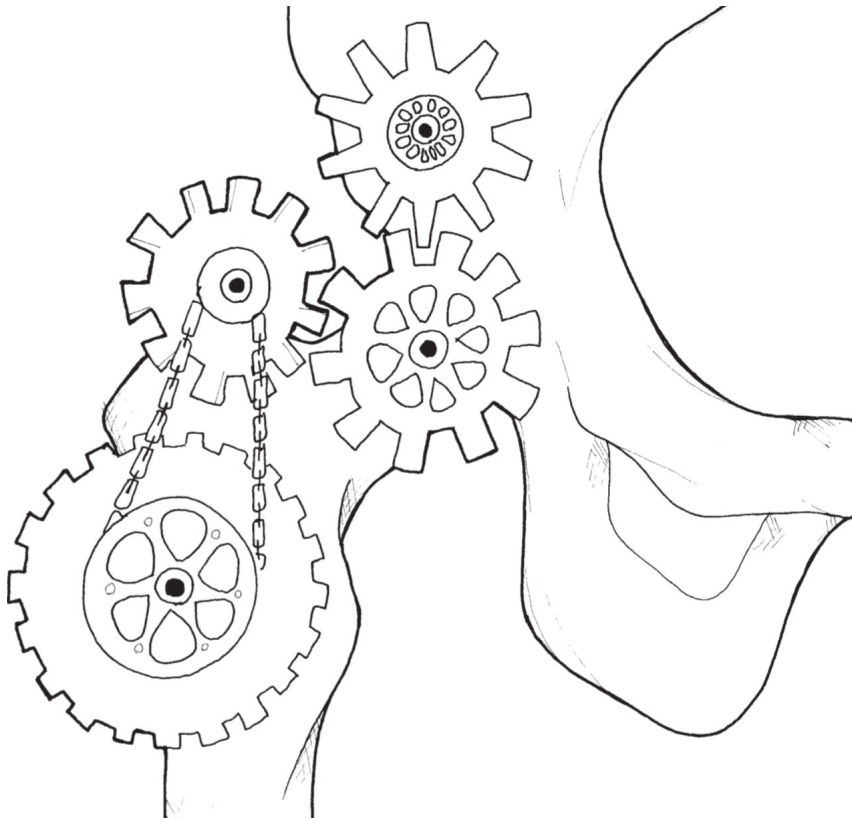
Femoral Maltorsion

The Normal Hip

- pain-free
- stable
- ‚unlimited‘ range of motion within physiological amplitudes
- single point of rotation without translation
- lasts a lifetime



Overview



The Normal Hip

Dysplasia

Cam-Impingement

Pincer-Impingement

Femoral Maltorsion

Instability: Hip Dysplasia

- smaller lunate surfae
- deficient femoral coverage


Steppacher et al, Osteoarthritis Cartilage, 2014

Babst et al, CORR, 2011

Ward et al, CORR, 2000

Haefeli et al, CORR, 2015

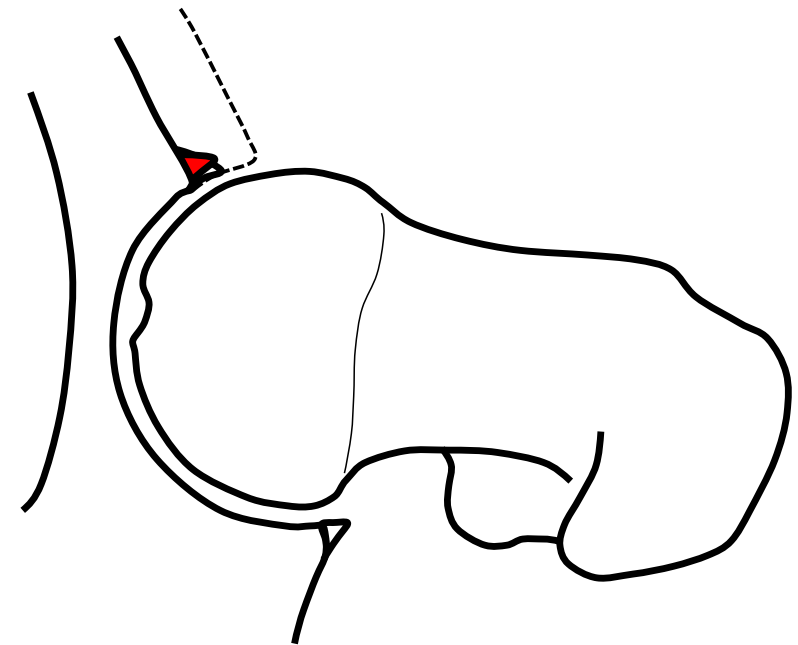
Dysplasia



Normal

Instability: Hip Dysplasia

- smaller lunate surfae
- deficient femoral coverage



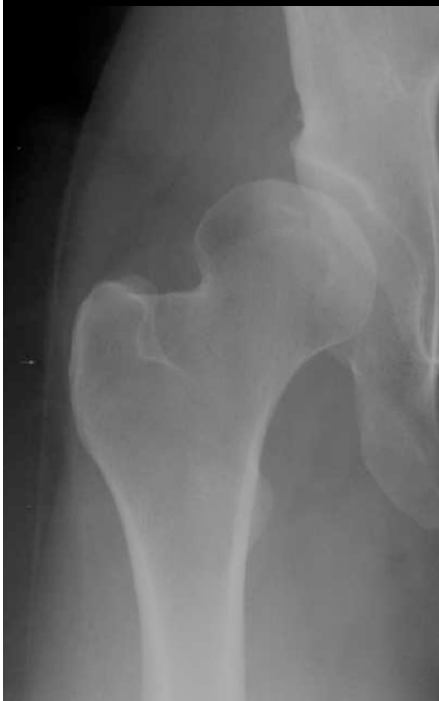Steppacher et al, Osteoarthritis Cartilage, 2014

Babst et al, CORR, 2011

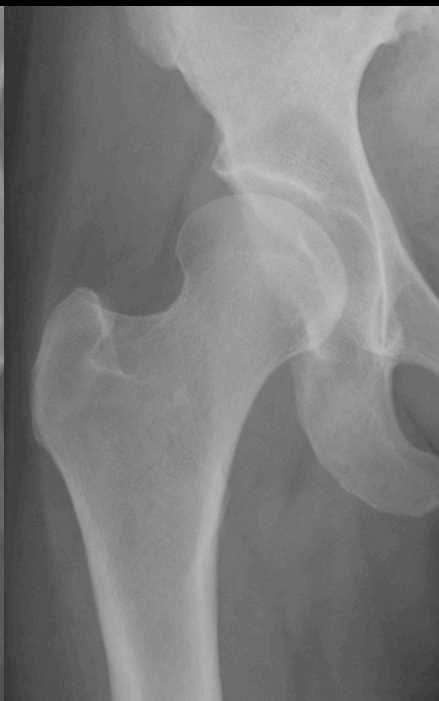Ward et al, CORR, 2000

Haefeli et al, CORR, 2015

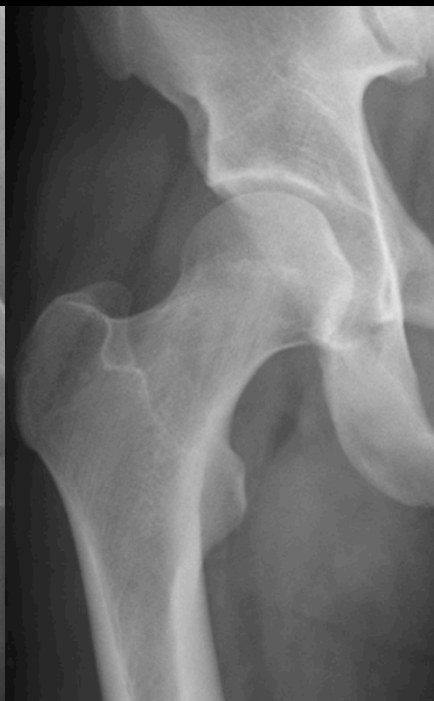severe dysplasia



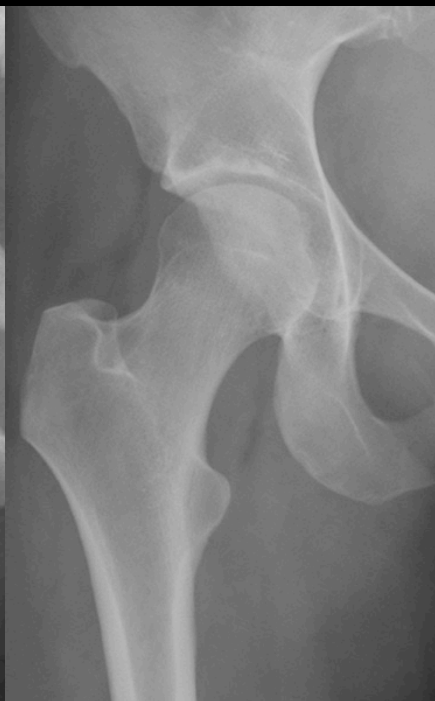dysplasia



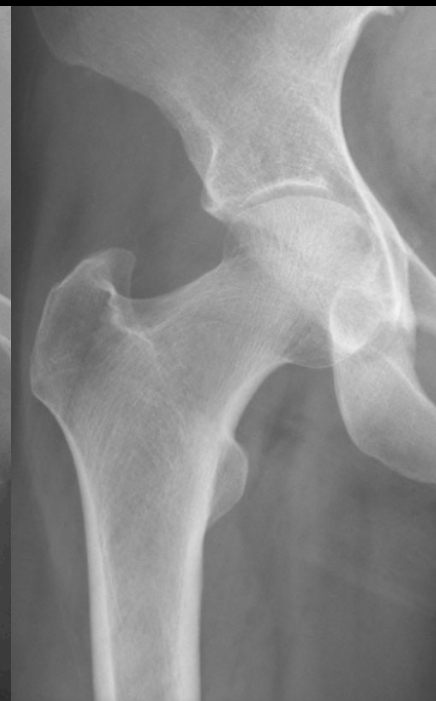normal



deep hip



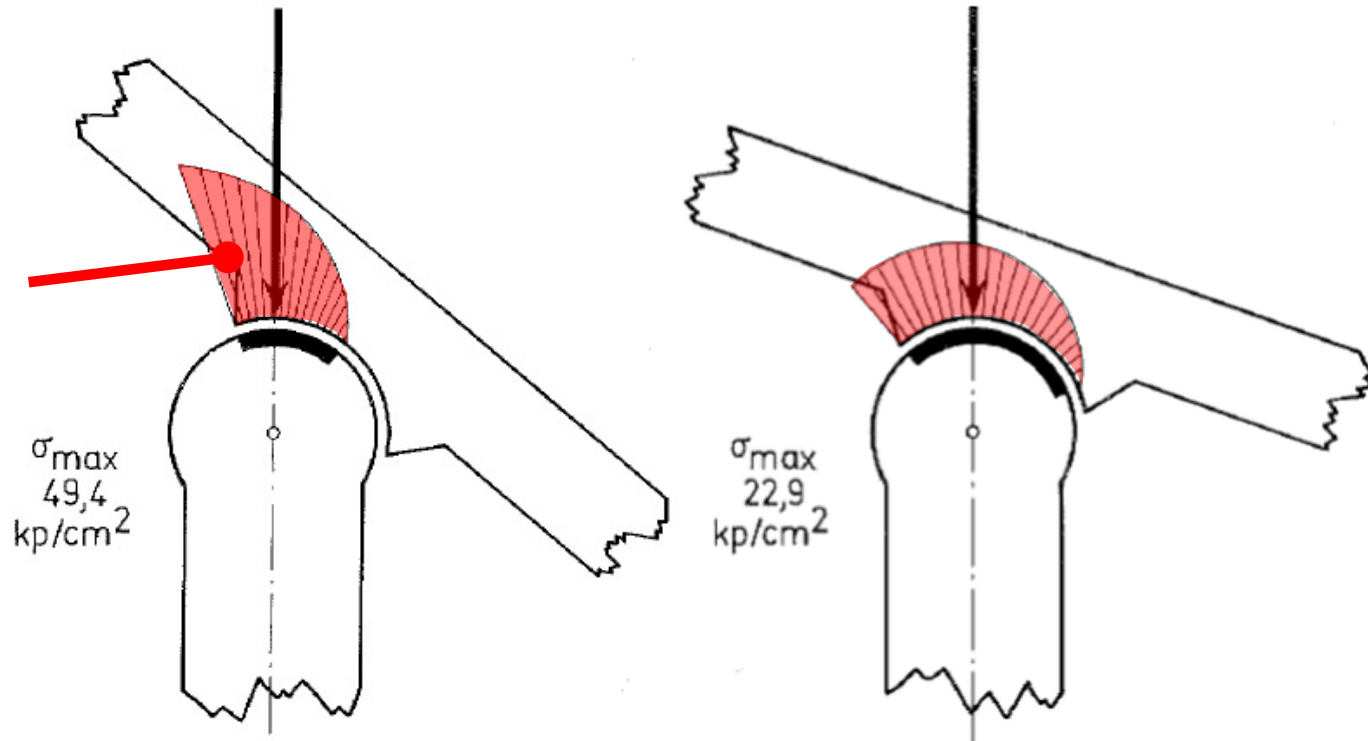
protrusio



Instability

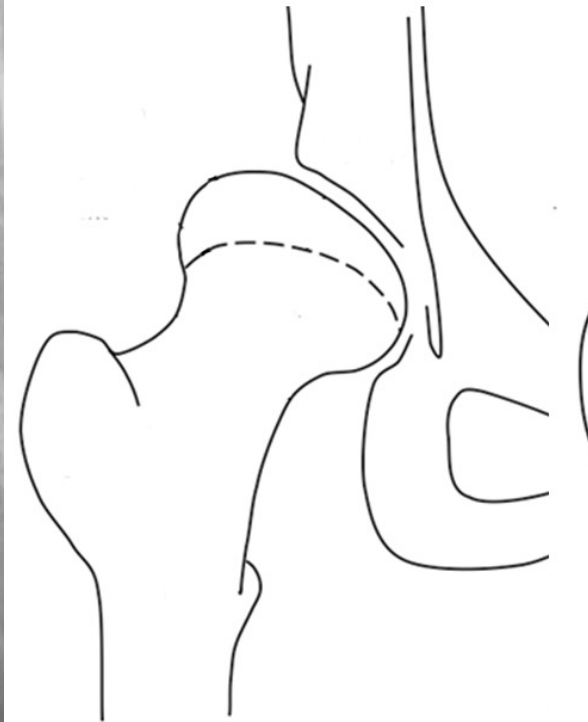
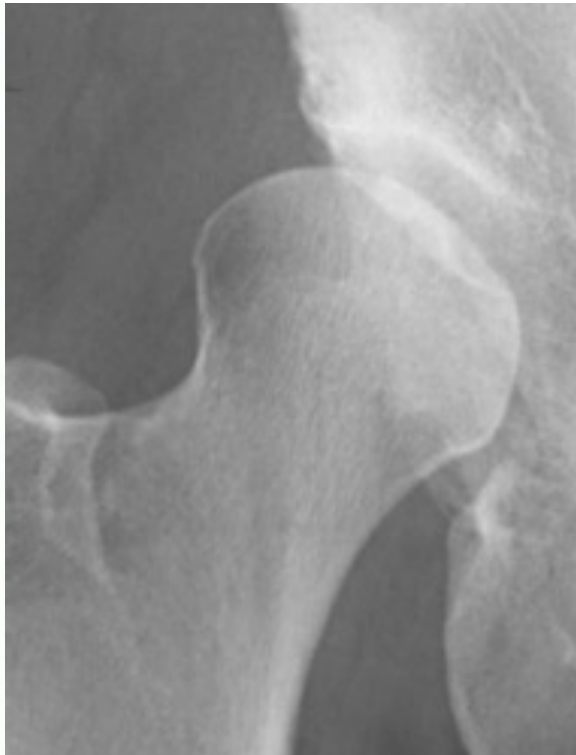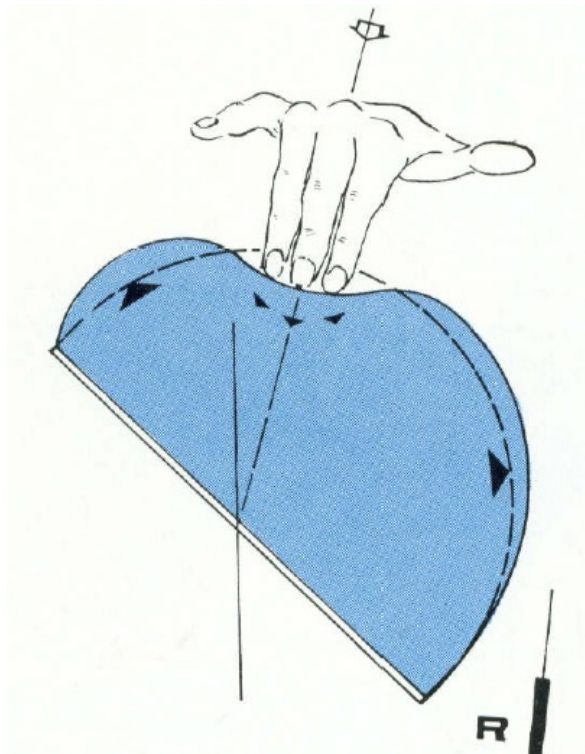
Residual Dysplasia of the Hip: Static Overload

**Reactive
subchondral
sclerosis**

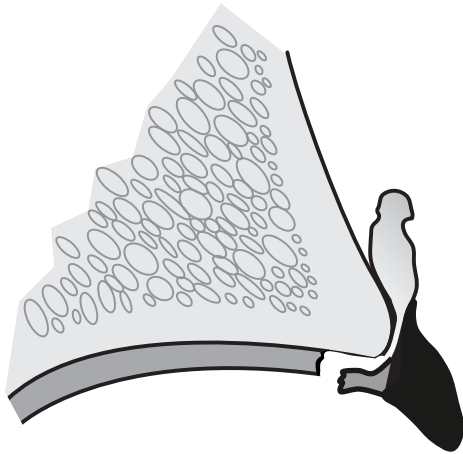


Pauwels, 1976

Residual Dysplasia of the Hip: Femoral Deformation

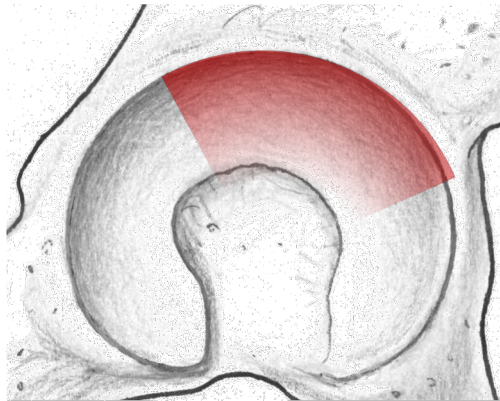


Dysplasia: Intraarticular Damage Pattern



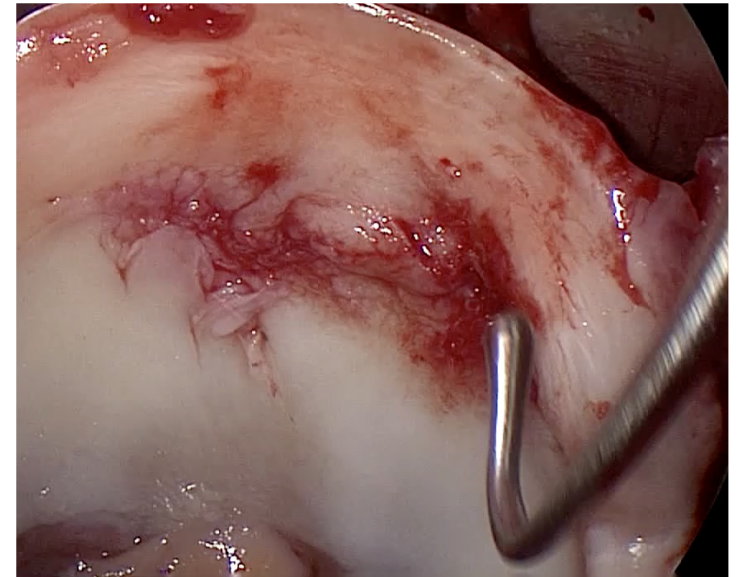
Characterization:

Large labrum with cysts/ganglion
Part of the hyaline cartilage remains
attached to the labrum

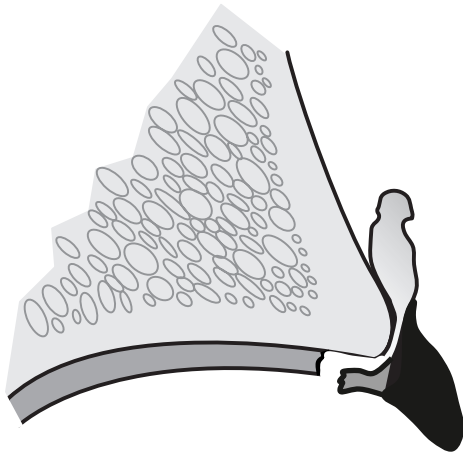


Localization:

Superior/anterosuperior

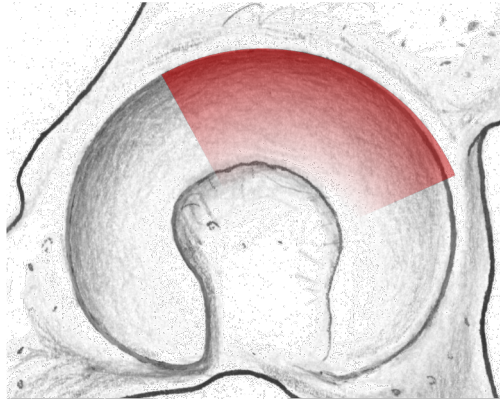


Dysplasia: Intraarticular Damage Pattern



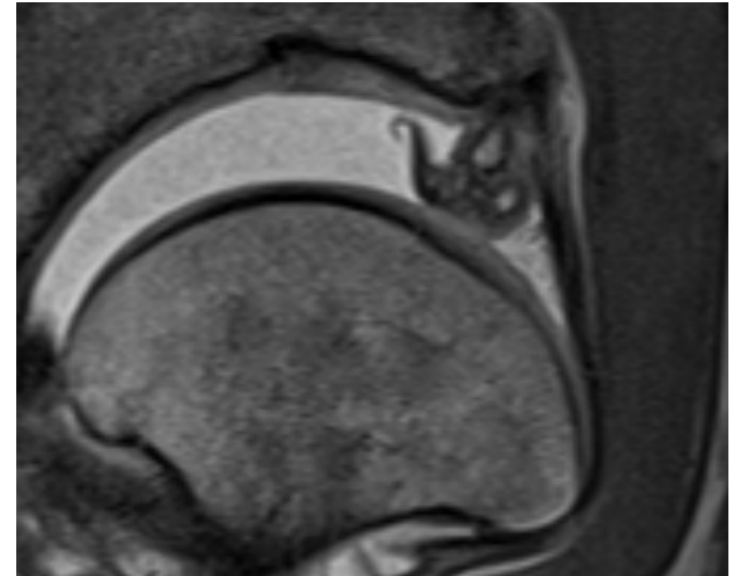
Characterization:

Large labrum with cysts/ganglion
Part of the hyaline cartilage remains
attached to the labrum

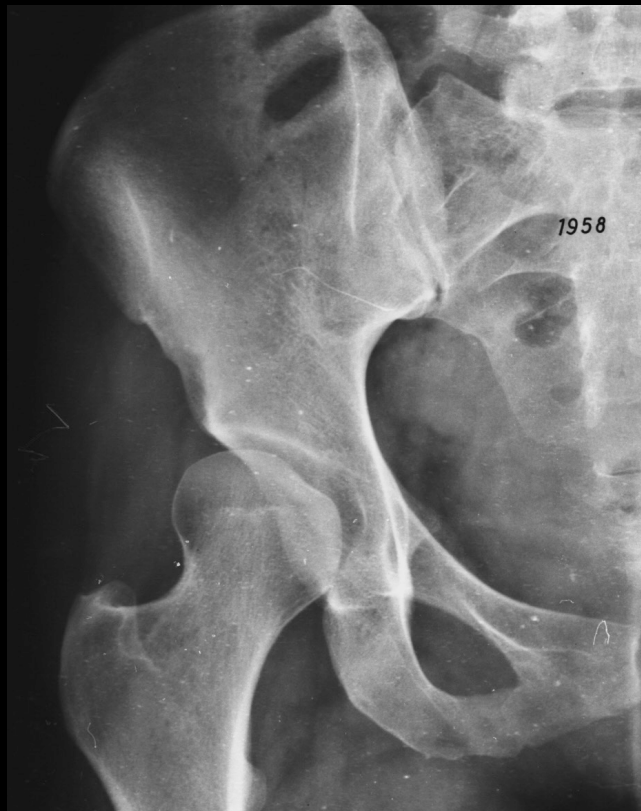

Localization:

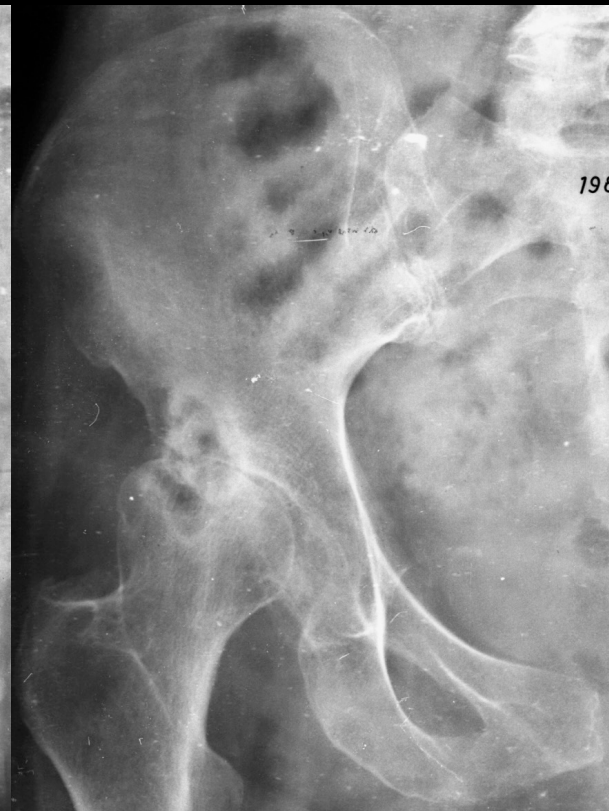Superior/anterosuperior



Hip Dysplasia: Natural Course

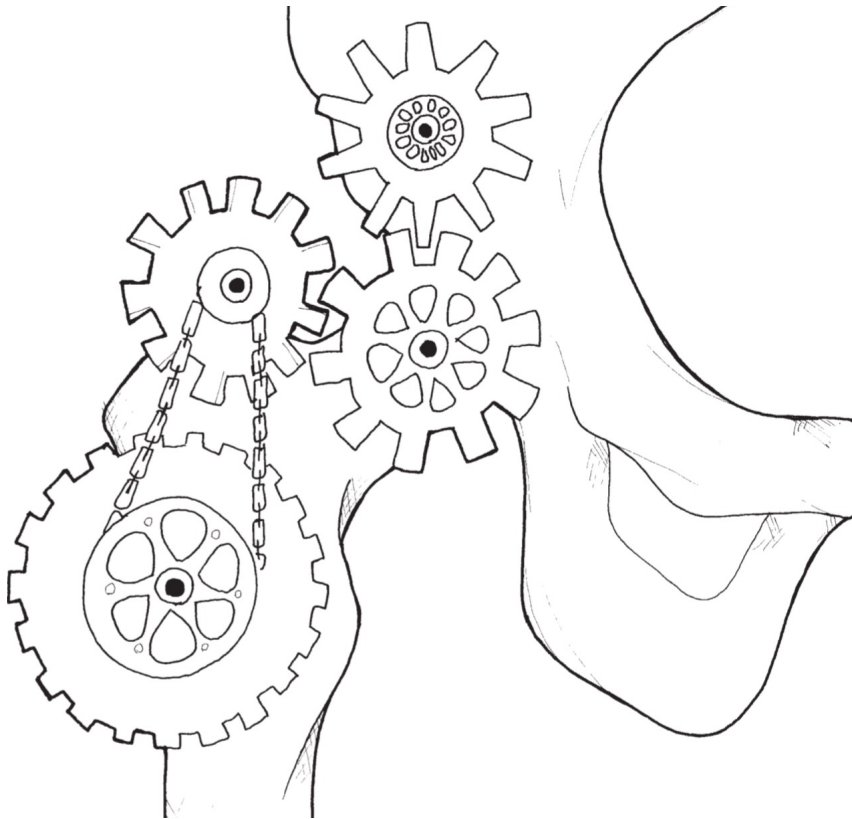


1958



1984

Overview



The Normal Hip

Dysplasia

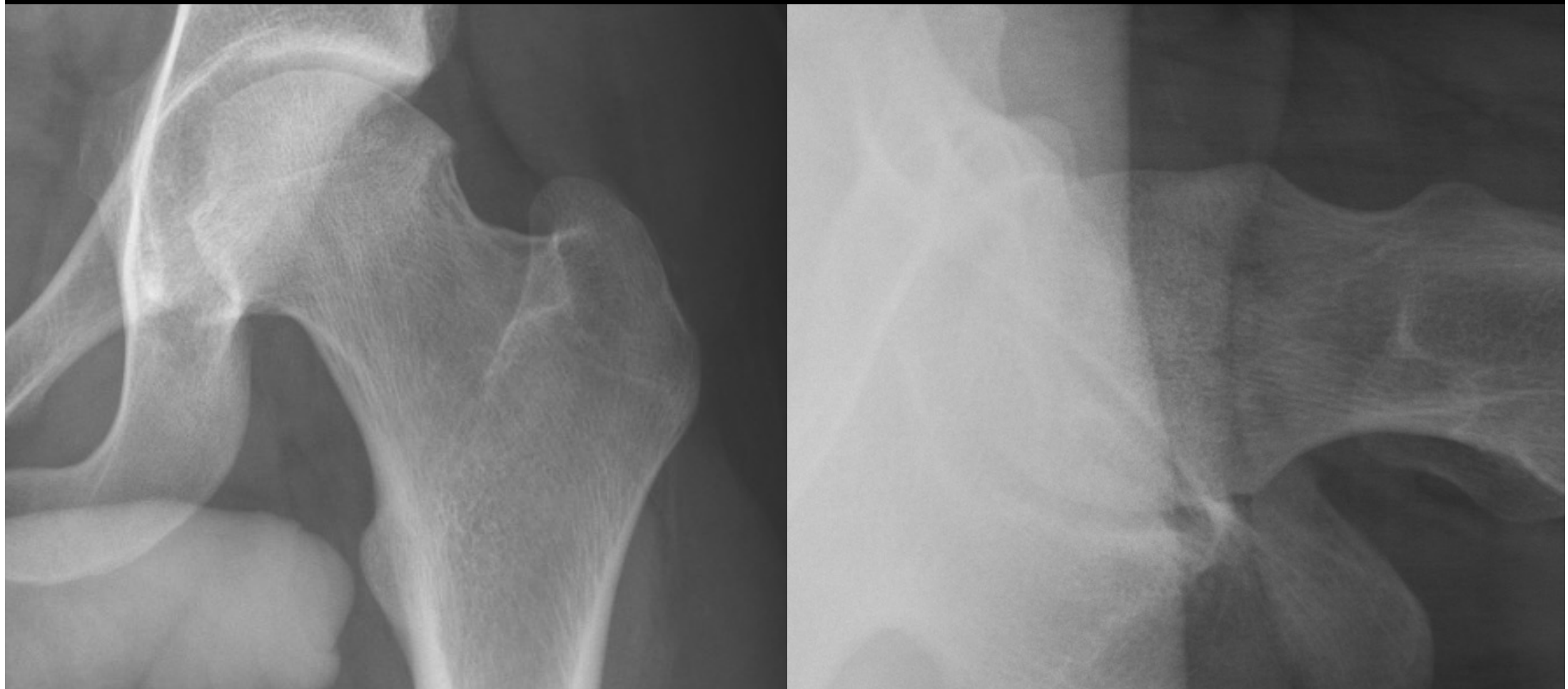Cam-Impingement

Pincer-Impingement

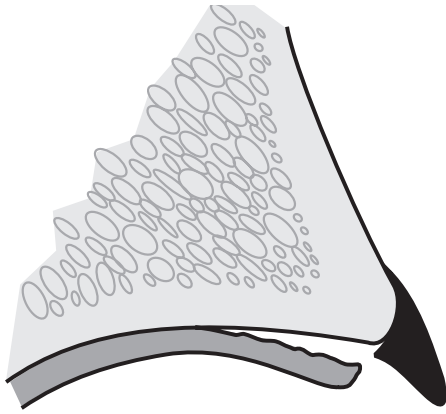
Femoral Maltorsion

Impingement: Cam



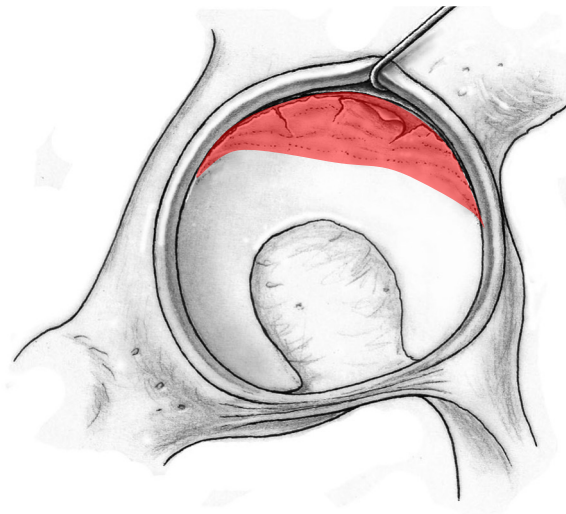


Cam: Intraarticular Damage Pattern



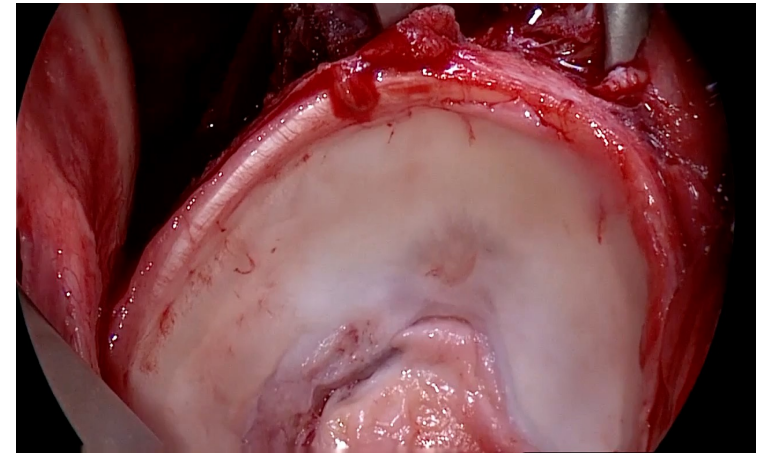
Characterization:

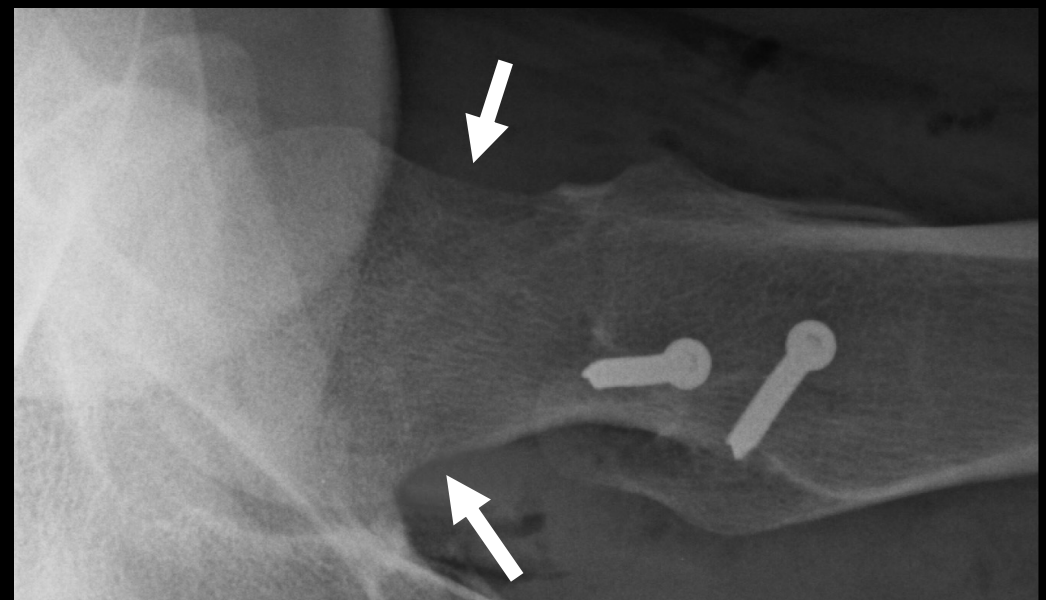
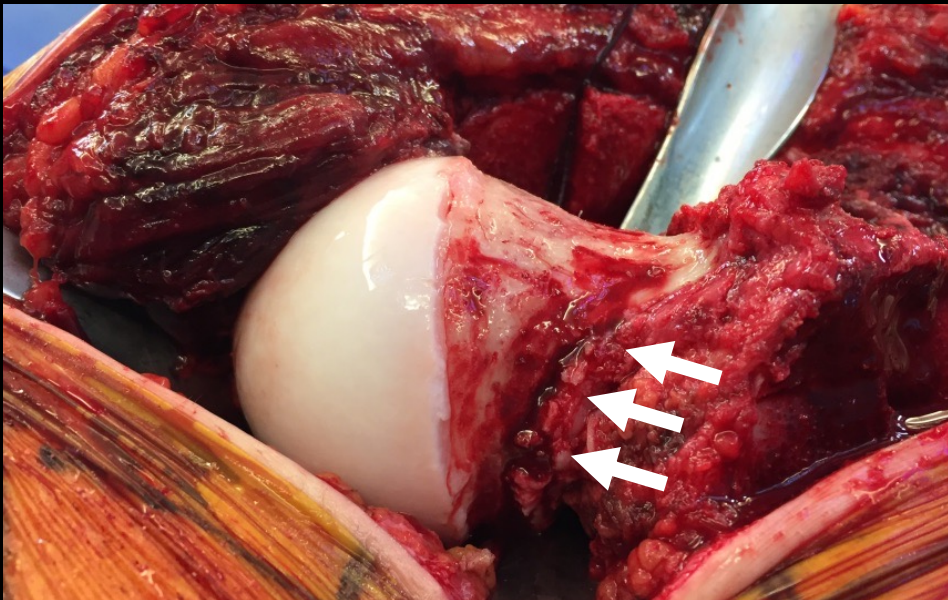
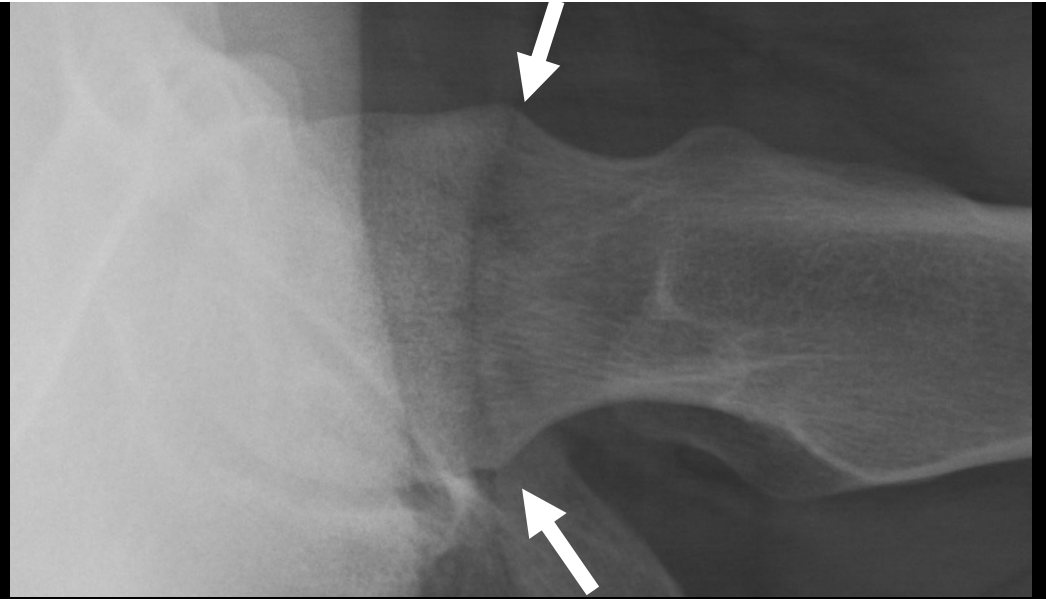
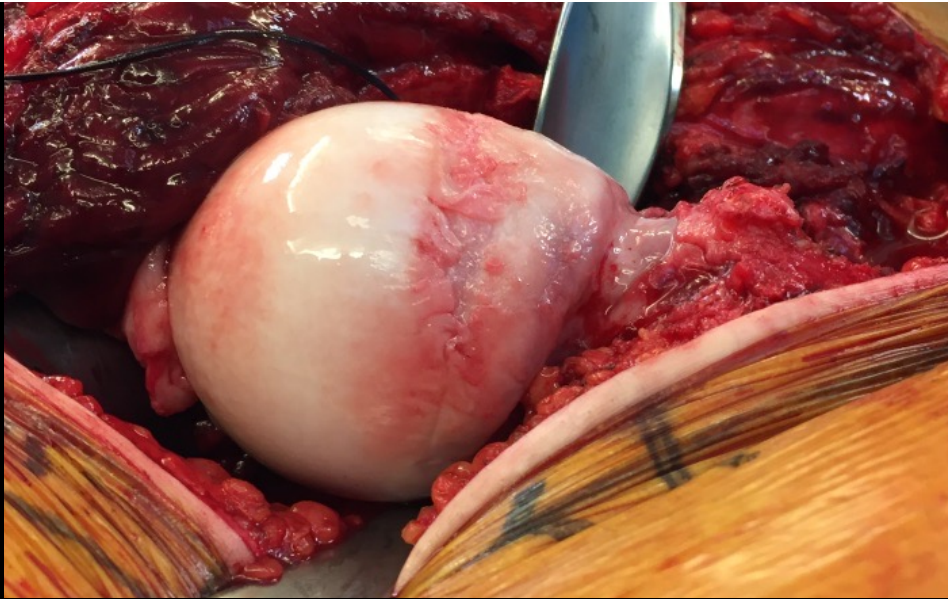
Disruption of chondrolabral
junction
Deep cartilage damage with flap
formation



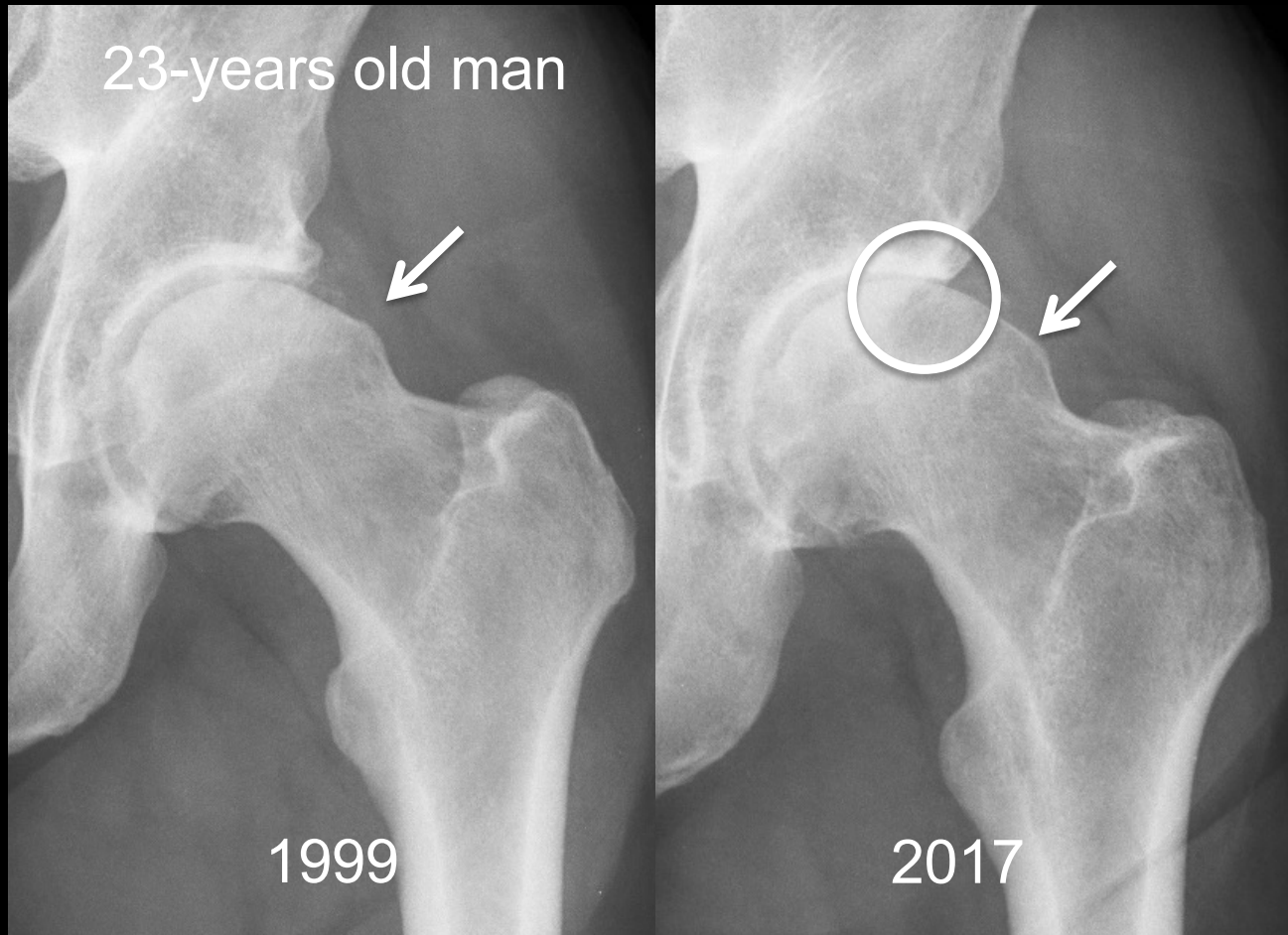
Localization:

Superior/anterosuperior

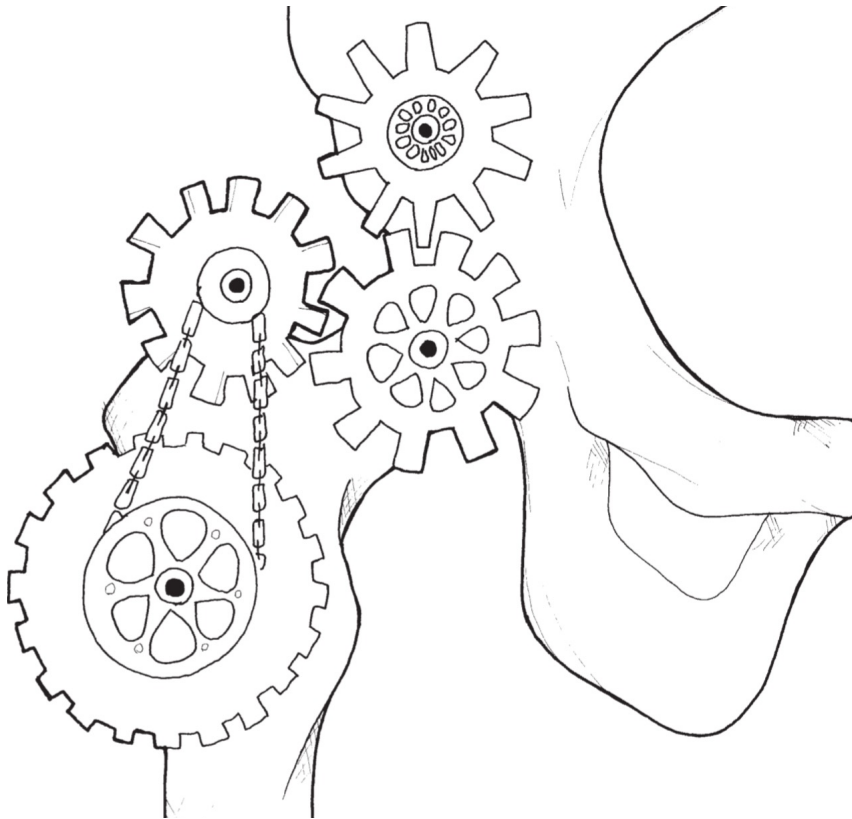




Cam-Impingement: The natural course



Overview



The Normal Hip

Dysplasia

Cam-Impingement

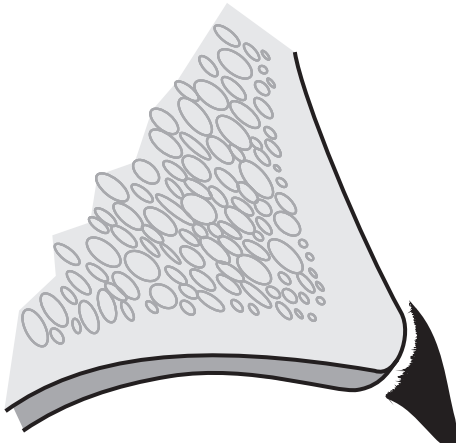
Pincer-Impingement

Femoral Maltorsion

Impingement: Pincer

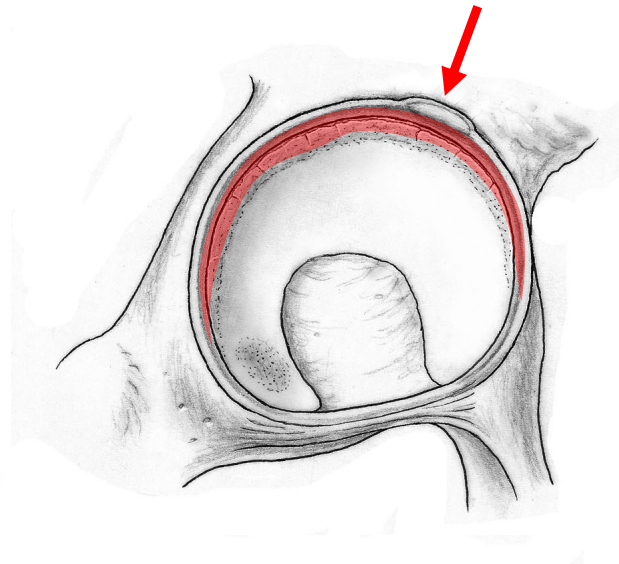


Pincer: Intraarticular Damage Pattern



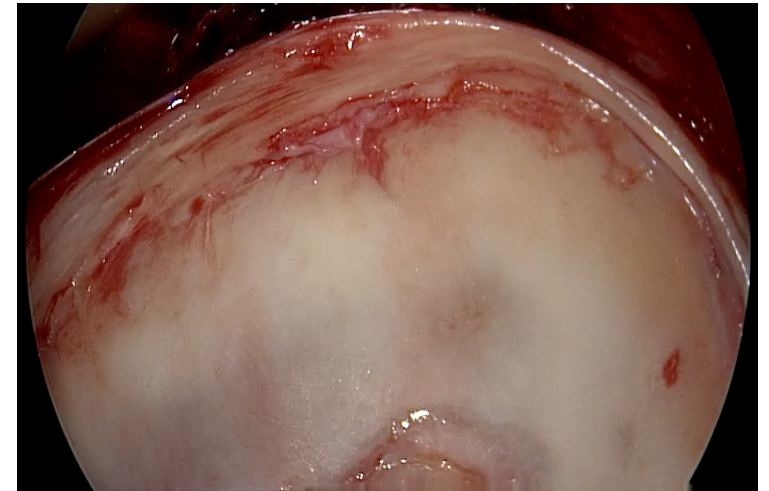
Characterization:

Full labral lesion, calcification and
ossifications
Adjacent small, circumferential
cartilage lesion

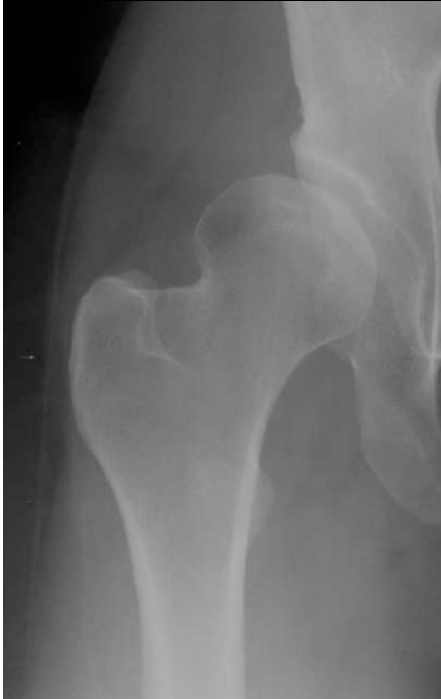

Localization:

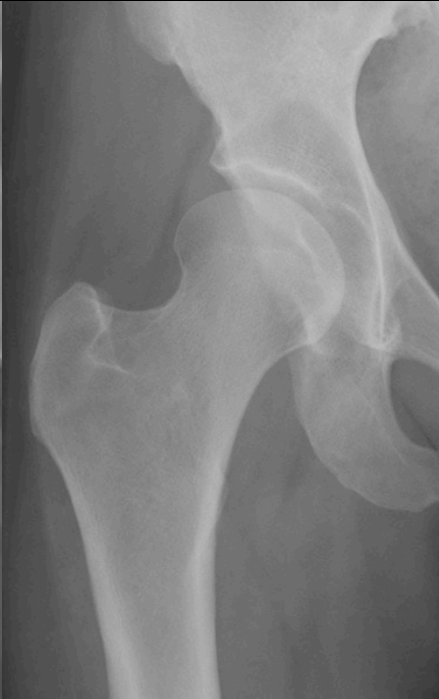Superior/anterosuperior



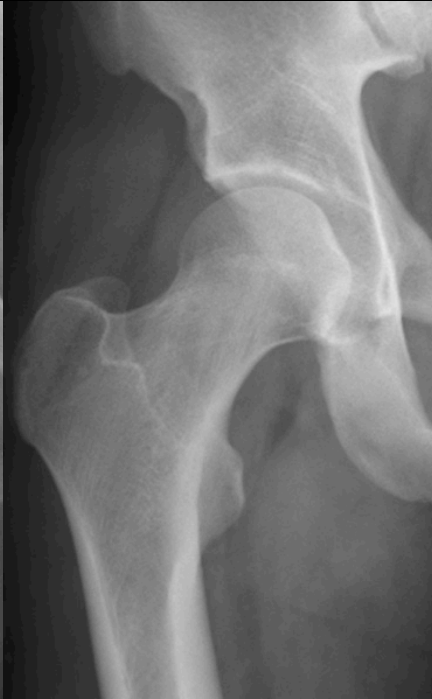Schwere Dysplasie



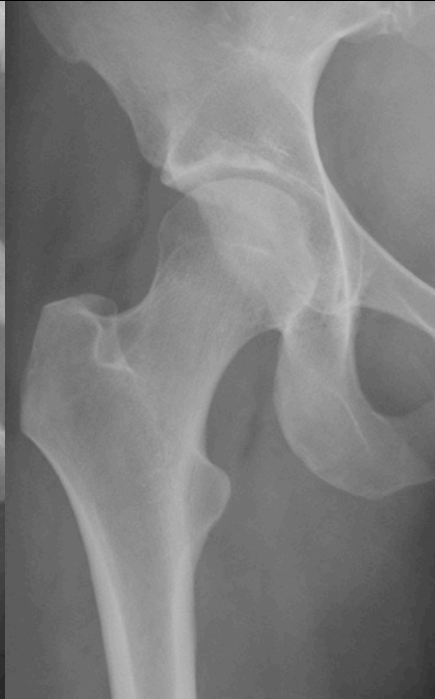Dysplasie



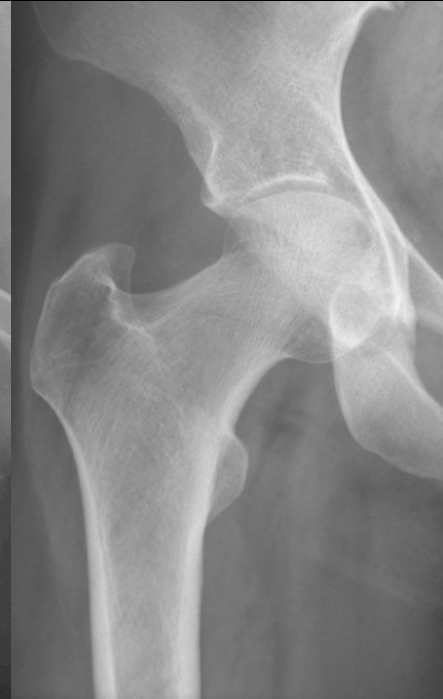Normal



Tiefe Hüfte



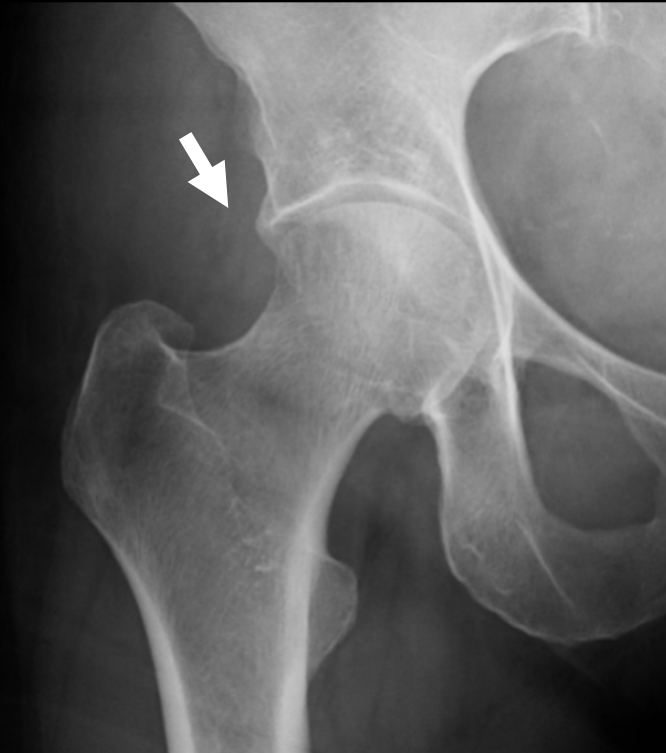Protrusio



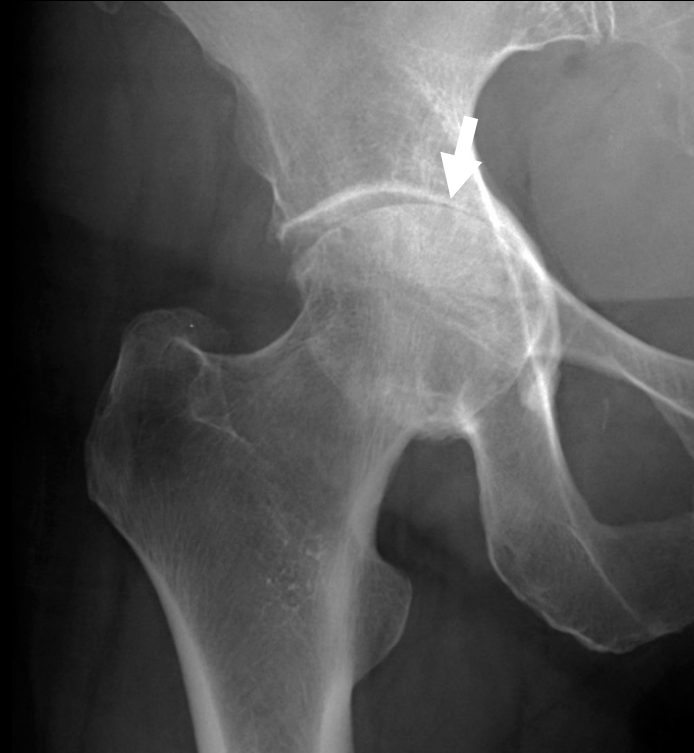Instability

Impingement

Protrusio: The natural course

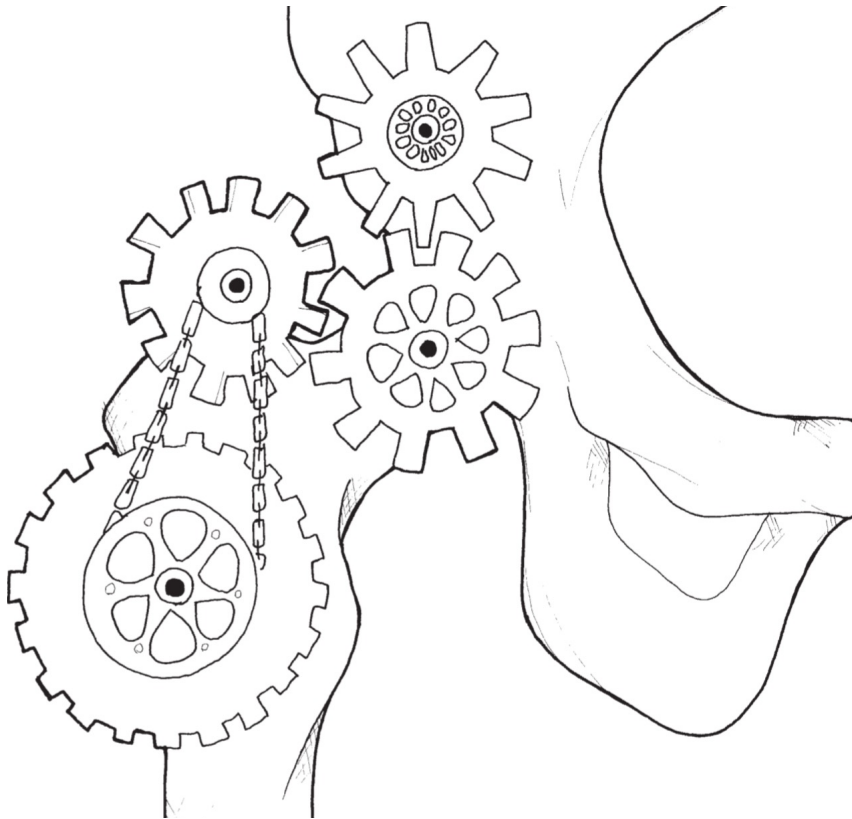


39-years old patient



15 years later...

Overview



The Normal Hip

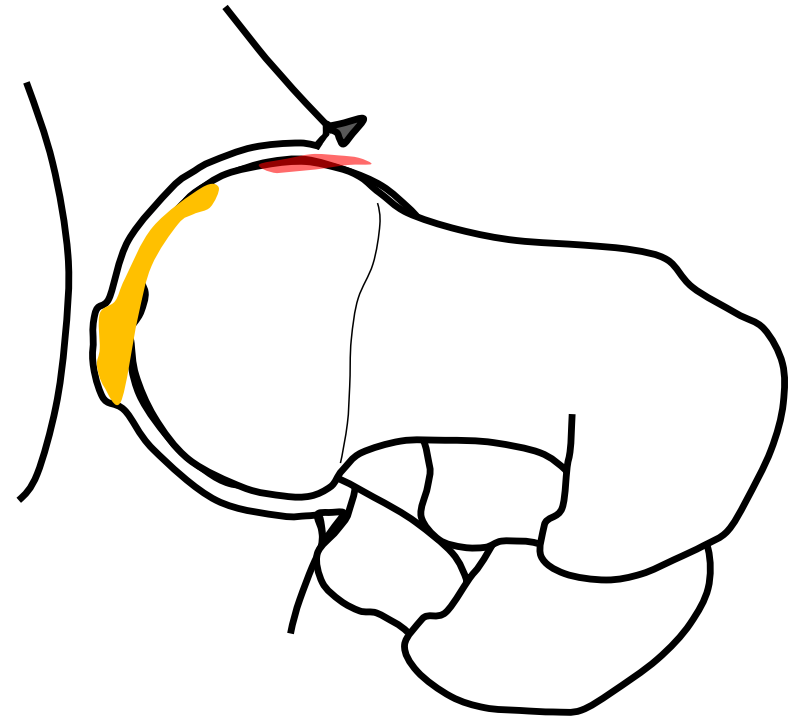
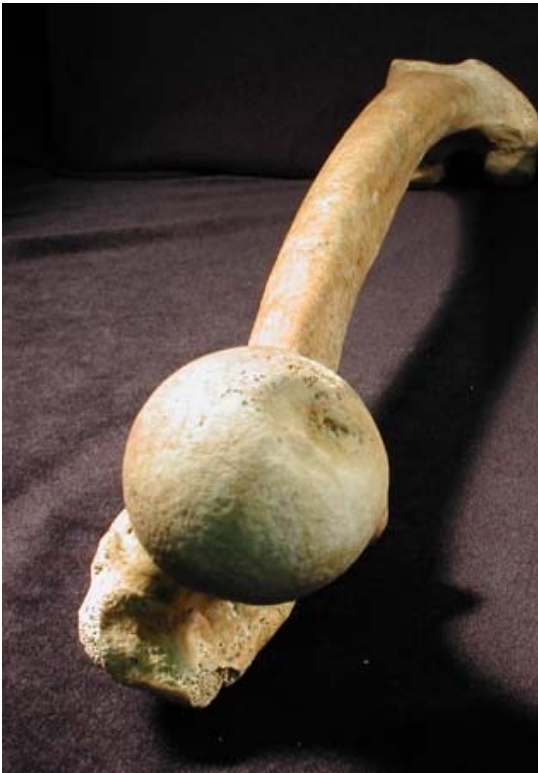Dysplasia

Cam-Impingement

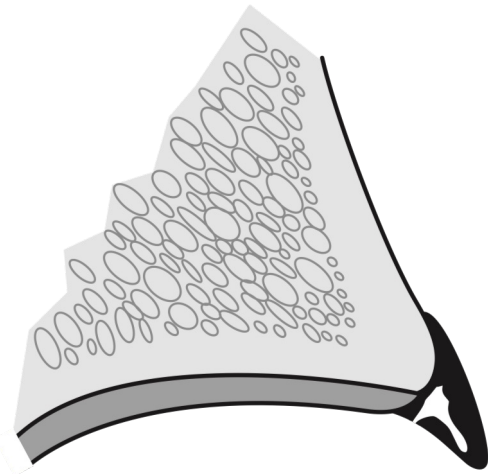
Pincer-Impingement

Femoral Maltorsion

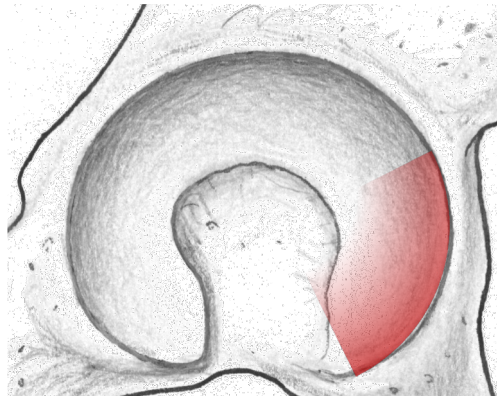
Levering out



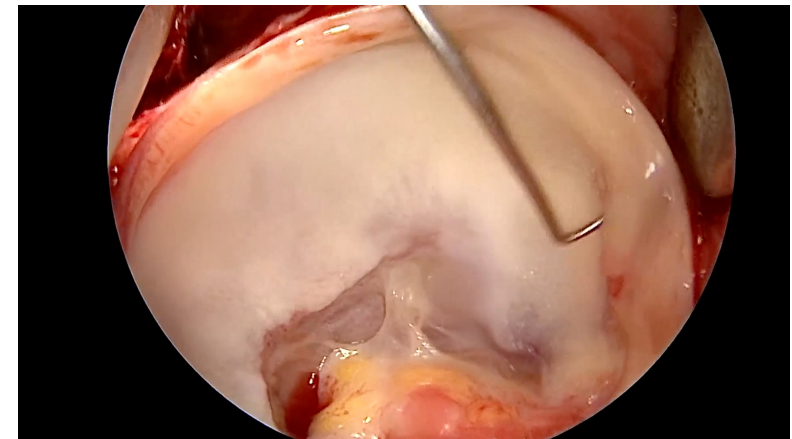
Femoral Anteversion: Intraarticular Damage Pattern



Characterization:
Large labrum
which appears ,empty‘

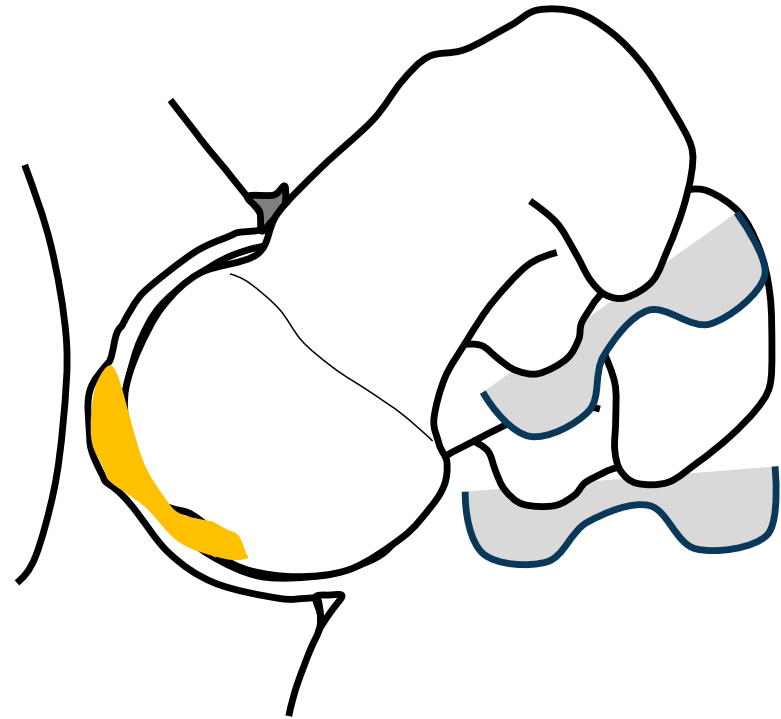
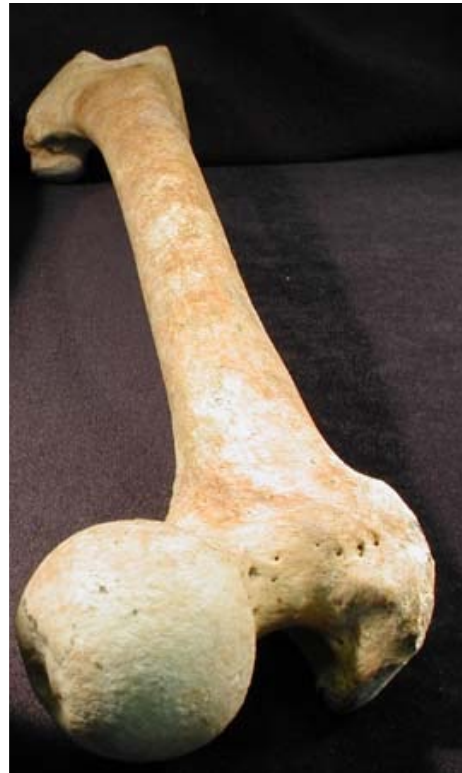

Localization:
Anteroinferior (contre coup)



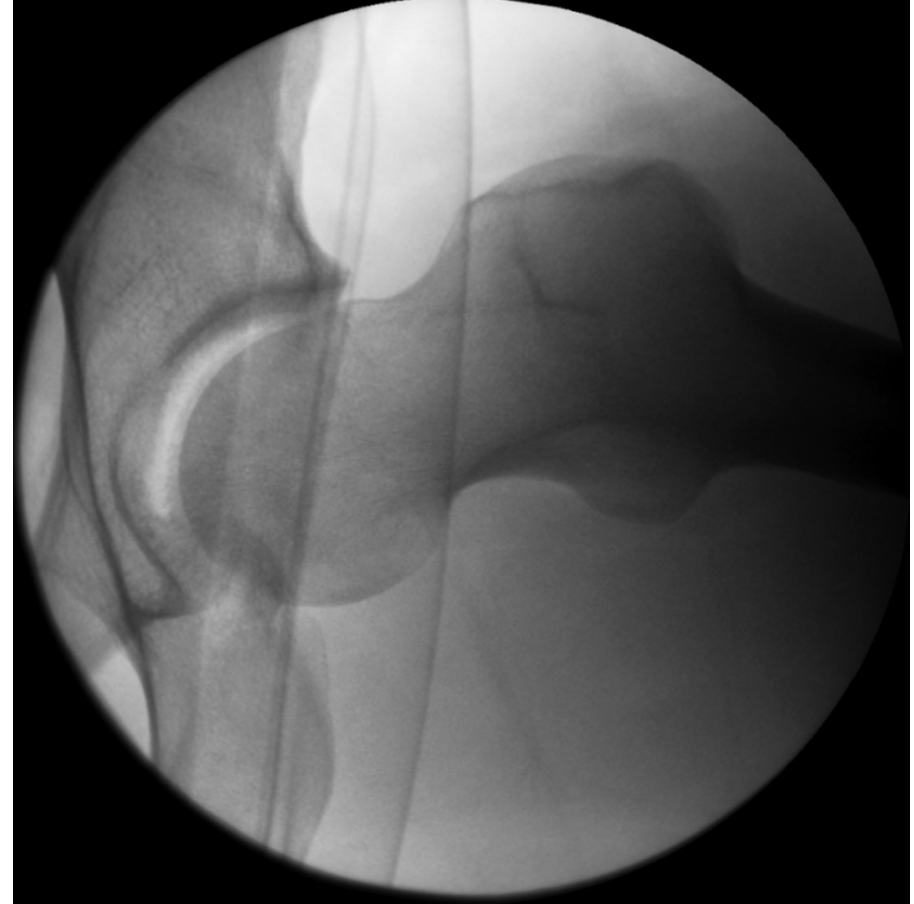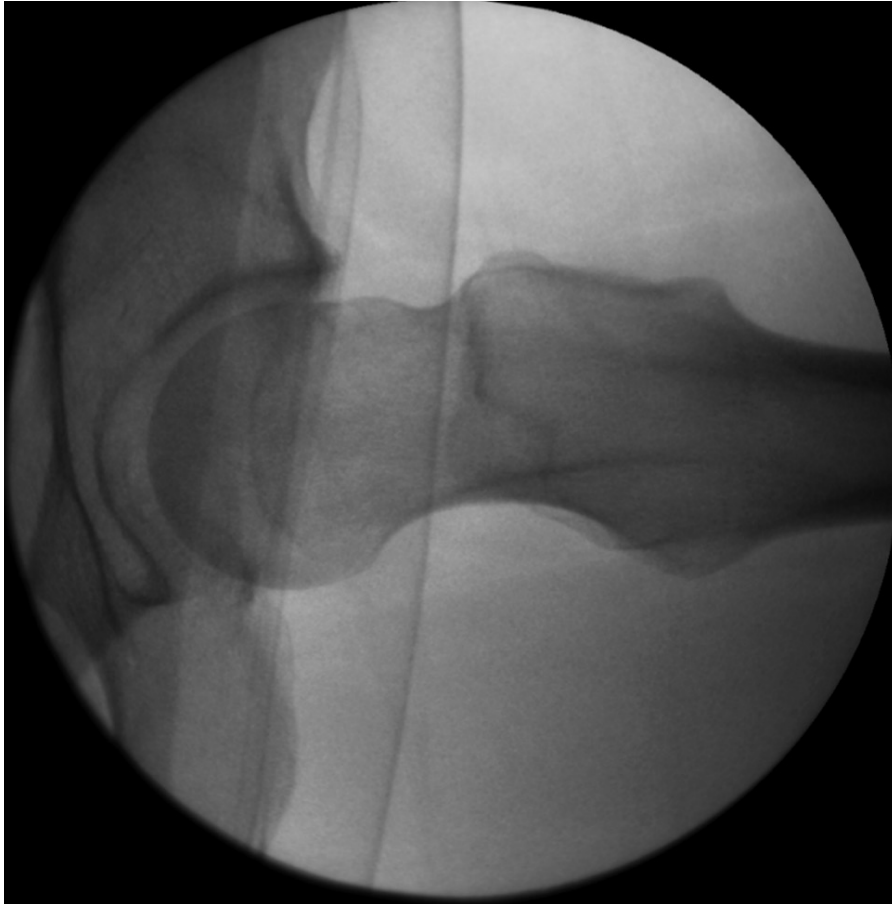
Small adjacent cartilage lesion

Levering out: Femoral Retrotorsion

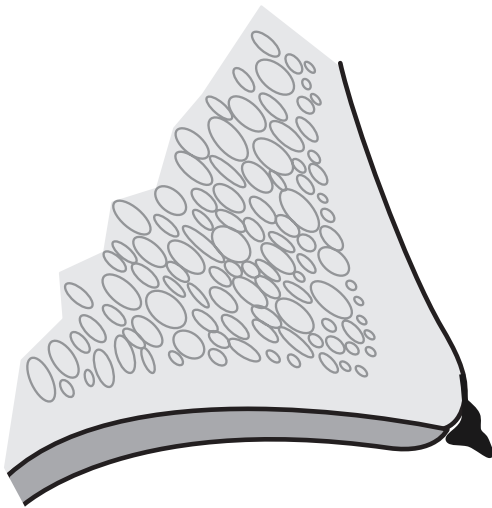


Steppacher et al, CORR, 2013
Tibor et al, BJJ, 2012

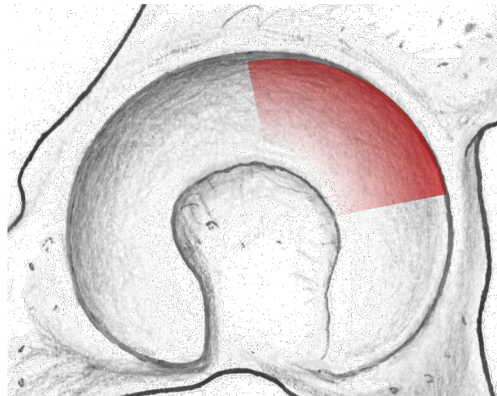
Levering out: Femoral Retrotorsion



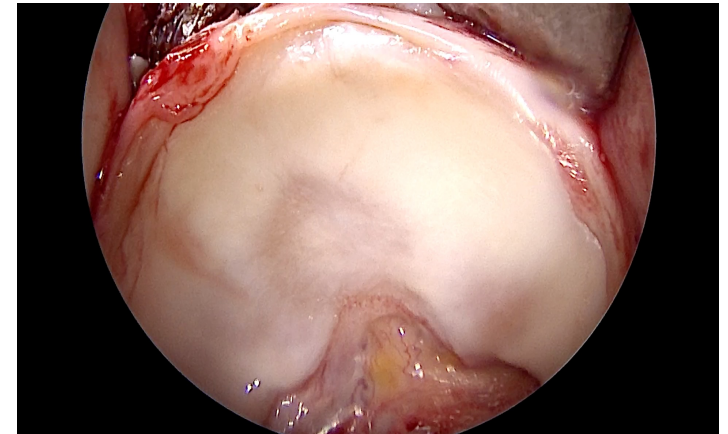
Femoral Retroversion: Intraarticular Damage Pattern



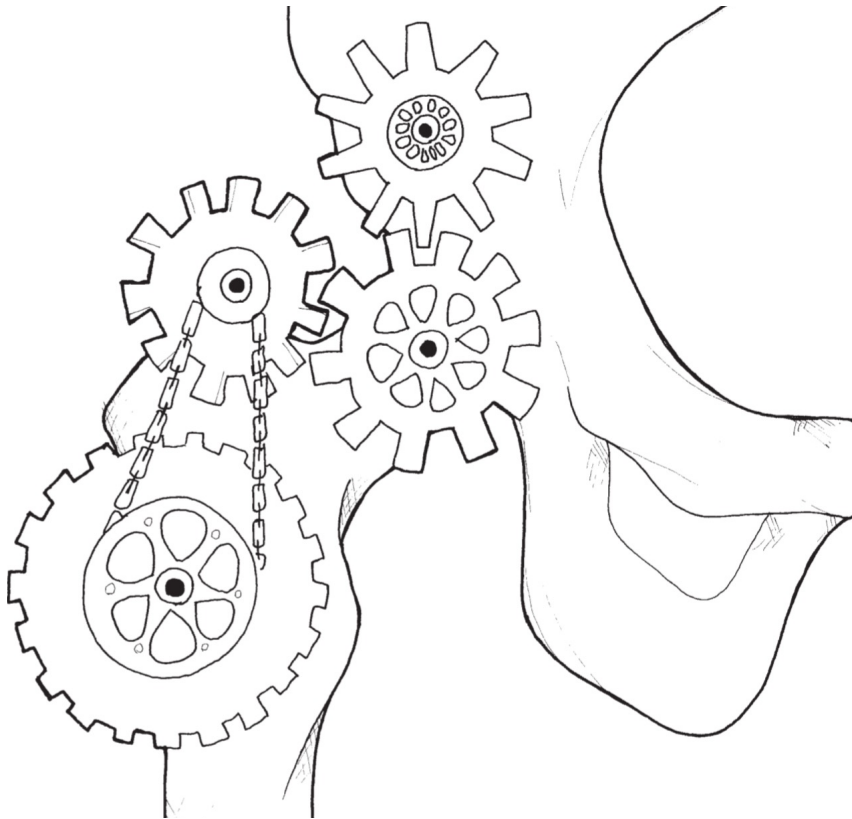
Characterization:
Very small or absent labrum
Adjacent cartilage lesion



Localization:
Anterosuperior



Overview



The Normal Hip

Dysplasia

Cam-Impingement

Pincer-Impingement

Femoral Maltorsion