

---

*u<sup>b</sup>*

# Bern Hip Symposium 2026

## **How it works:**

## Pathomechanisms of the hip

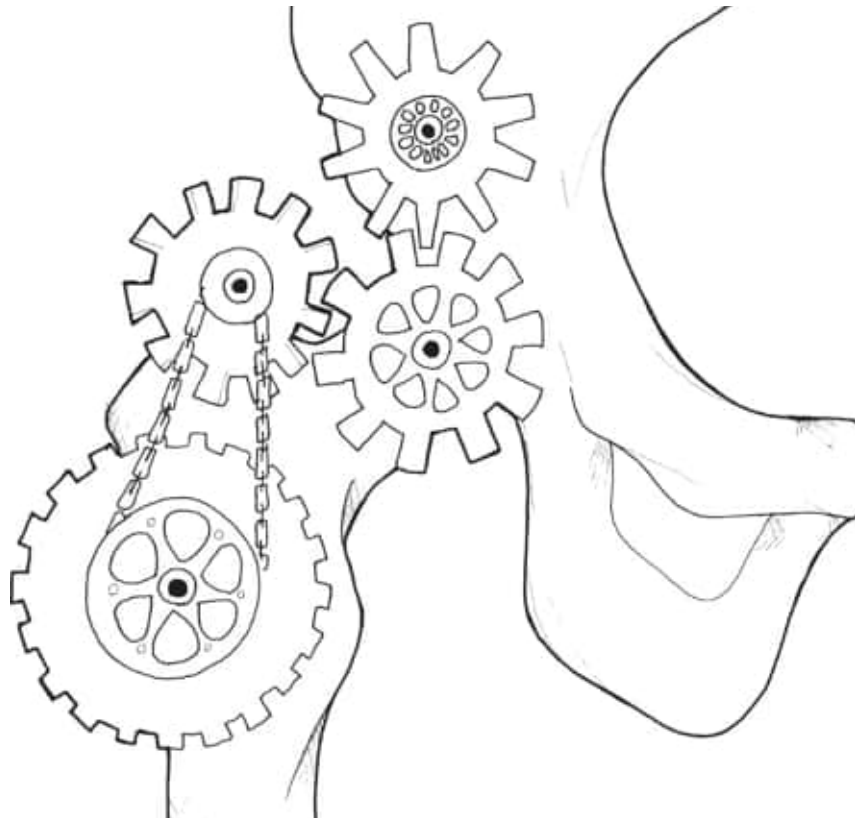
**Moritz Tannast**

Professor and Chairman

Department of Orthopaedic Surgery and Traumatology, Inselspital, University of Bern  
Switzerland

$u^b$

# Overview Pathomechanism Labral Tears

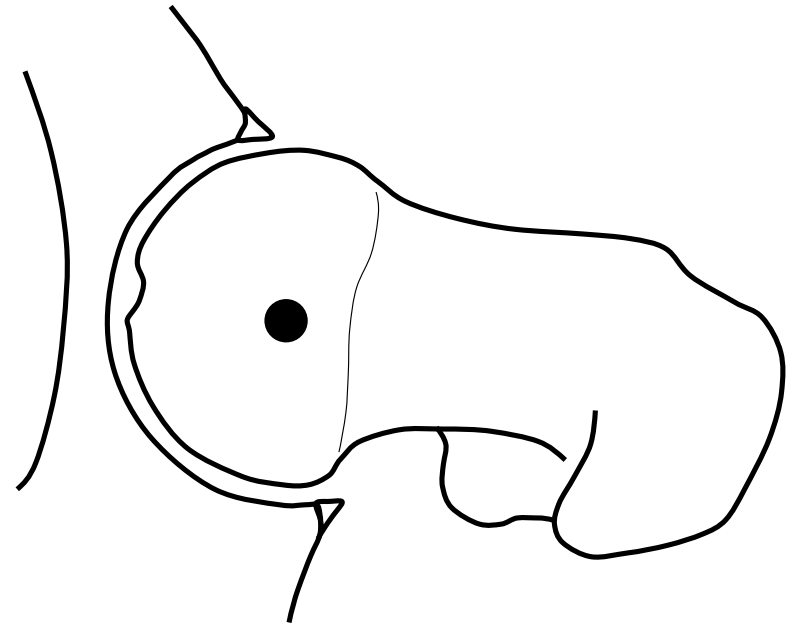


- The Normal Hip
- Dysplasia
- Cam-Impingement
- Pincer-Impingement
- Femoral Maltorsion

---

# $u^b$ The Normal Hip

- pain-free
- stable
- ‚unlimited‘ range of motion within physiological amplitudes
- single point of rotation without translation
- lasts a lifetime

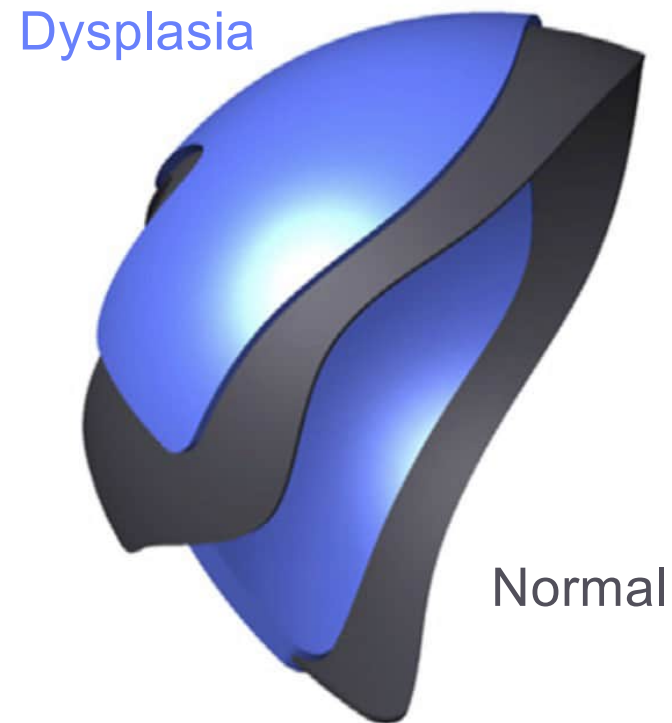


---

$u^b$  **Dysplasia**

- smaller lunate surface
- deficient femoral coverage

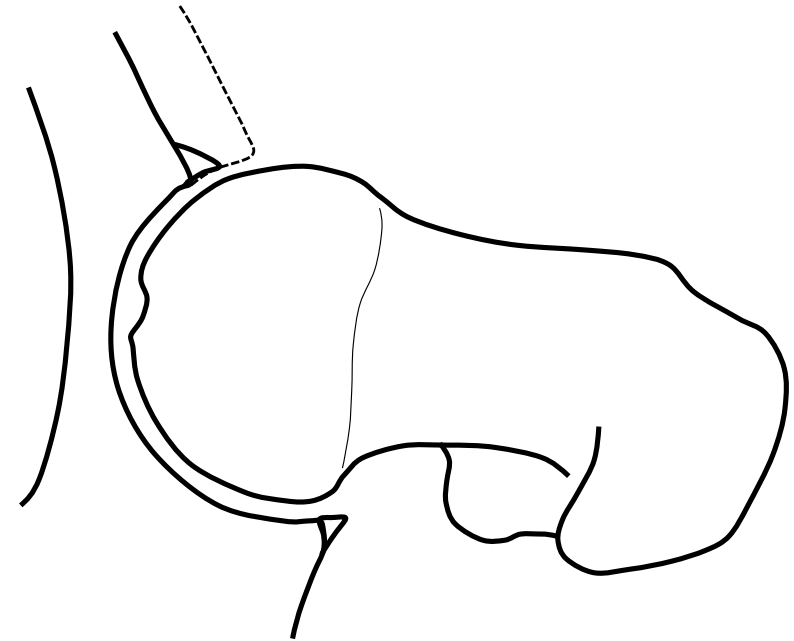
*Steppacher et al, Osteoarthritis Cartilage, 2014*  
*Babst et al, CORR, 2011*  
*Ward et al, CORR, 2000*  
*Haefeli et al, CORR, 2015*



---

# $u^b$ Dysplasia

- smaller lunate surface
- deficient femoral coverage



*Steppacher et al, Osteoarthritis Cartilage, 2014*

*Babst et al, CORR, 2011*

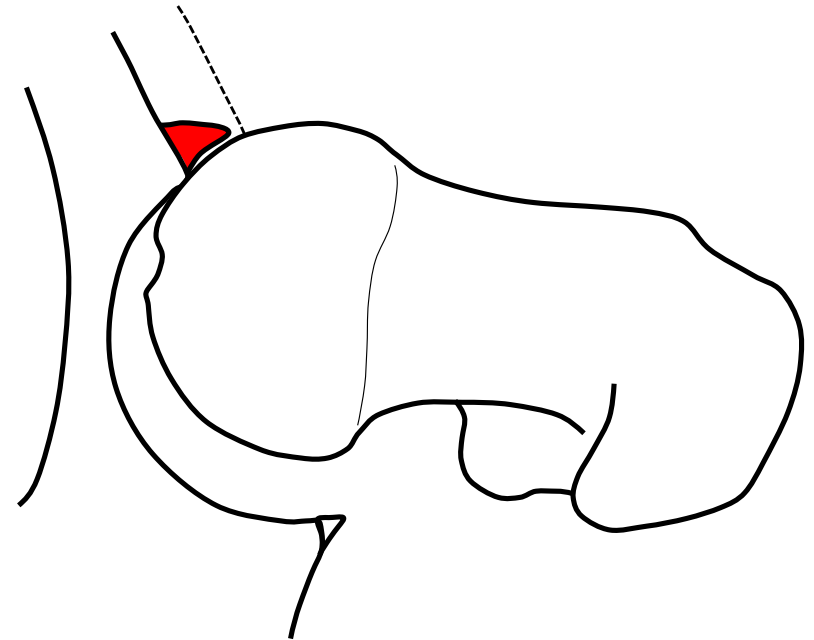
*Ward et al, CORR, 2000*

*Haefeli et al, CORR, 2015*

---

# $u^b$ Dysplasia

- smaller lunate surface
- deficient femoral coverage



*Steppacher et al, Osteoarthritis Cartilage, 2014*

*Babst et al, CORR, 2011*

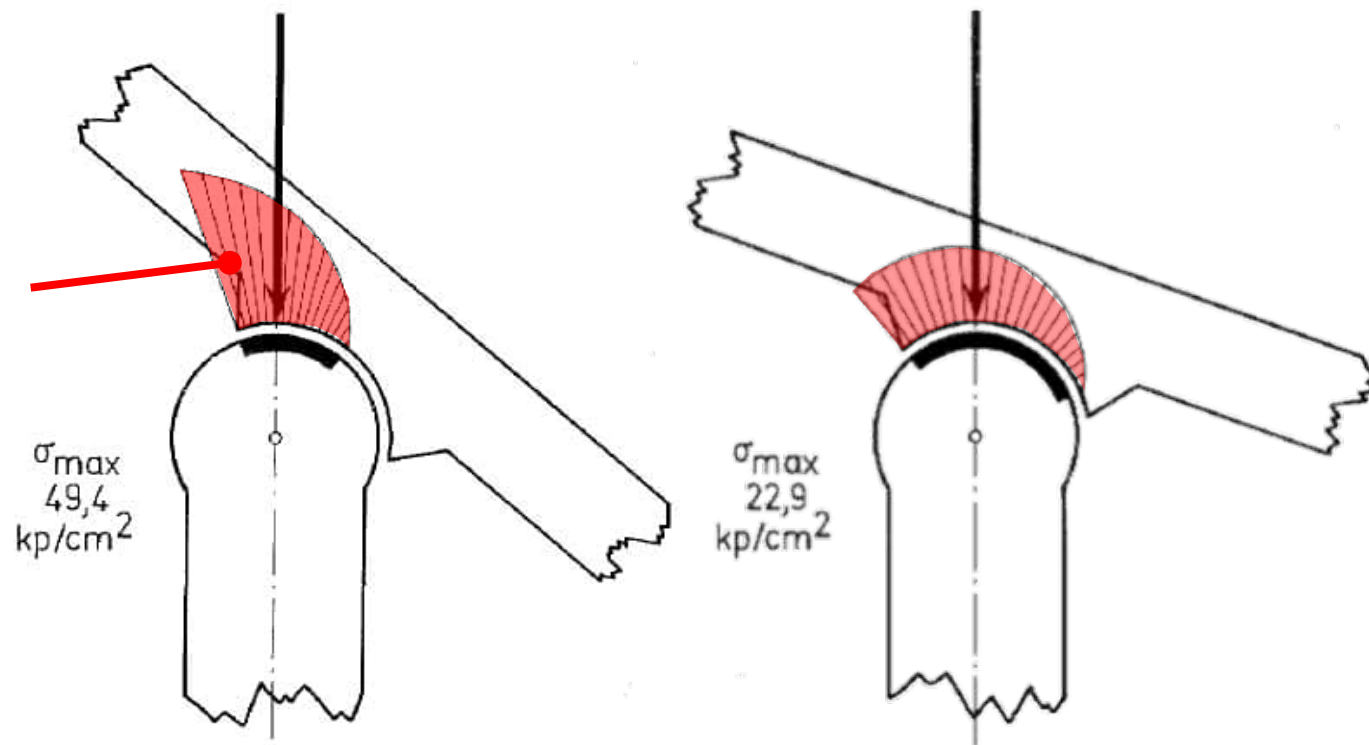
*Ward et al, CORR, 2000*

*Haefeli et al, CORR, 2015*

---

$u^b$  Residual Dysplasia of the Hip  
Static Overload

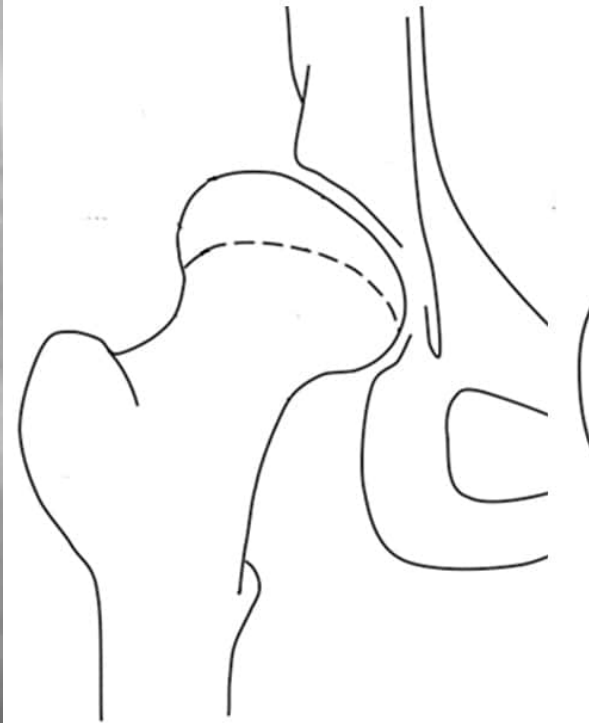
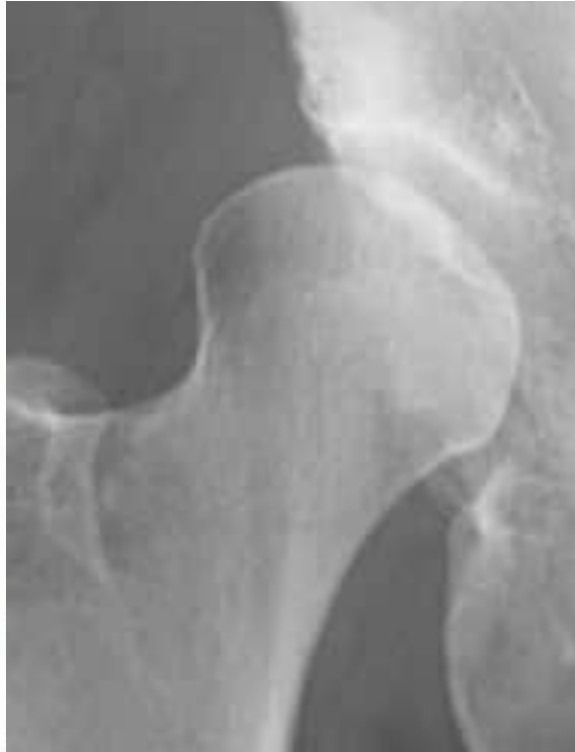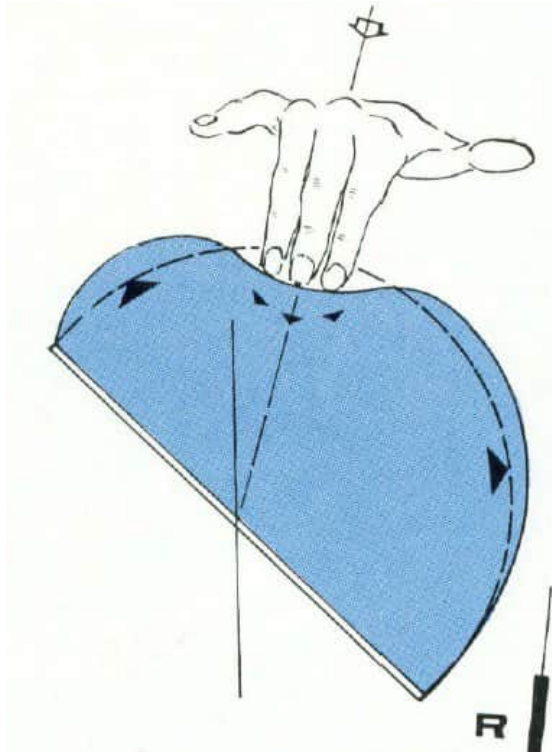
Reactive  
subchondral  
sclerosis



*Pauwels, 1976*

---

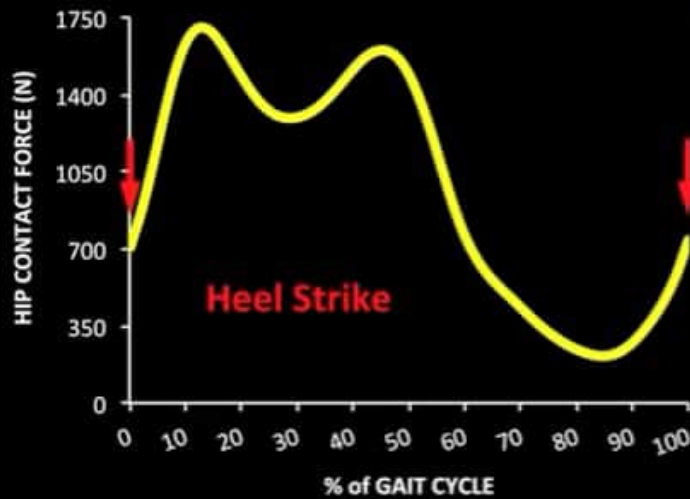
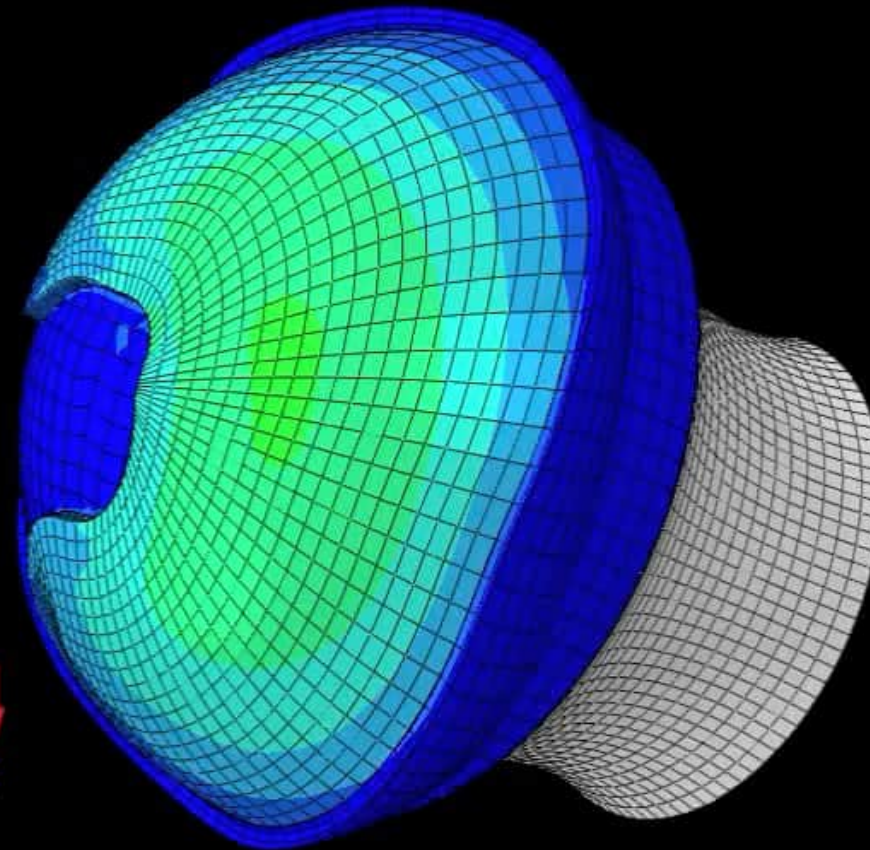
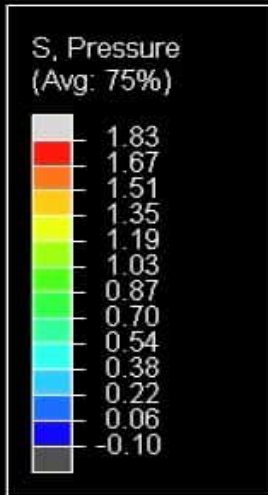
$u^b$  **Residual Dysplasia of the Hip**  
Static Overload



*Bombelli, 1983*  
*Steppacher, CORR 2008*

# Normal - Walking

Posterosuperior view of a right hip joint

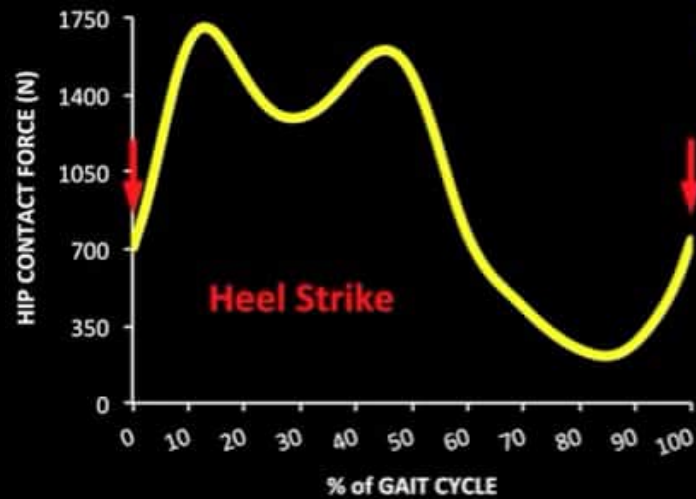
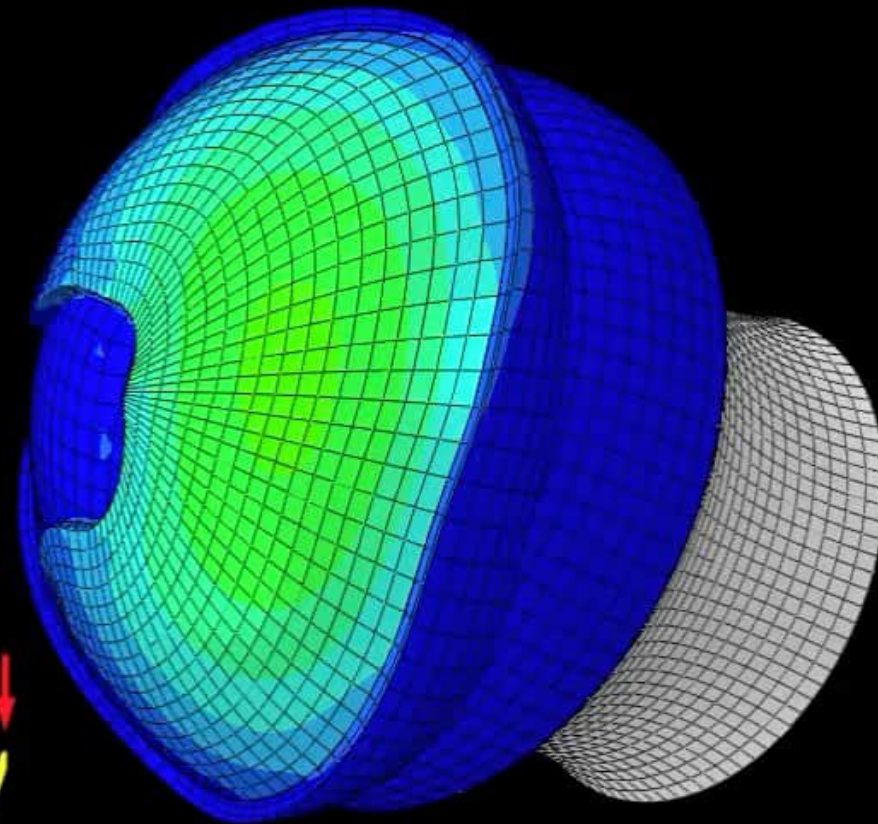


Liechti et al, J Orthop Res, 2014

# Dysplasia - Walking

Posterosuperior view of a right hip joint

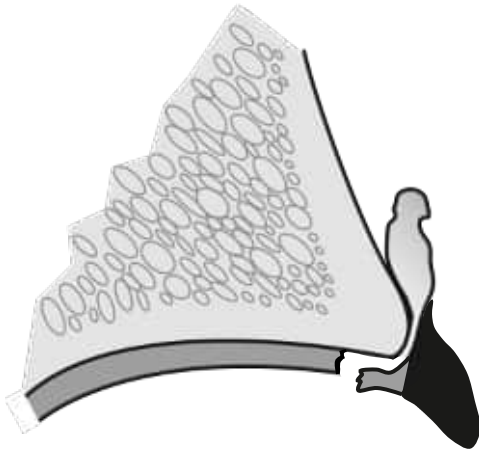
S, Pressure  
(Avg: 75%)



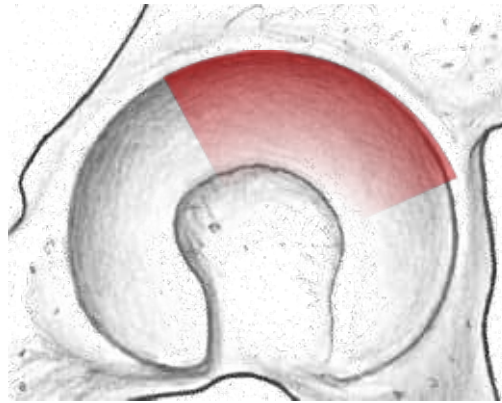
Liechti et al, J Orthop Res, 2014

---

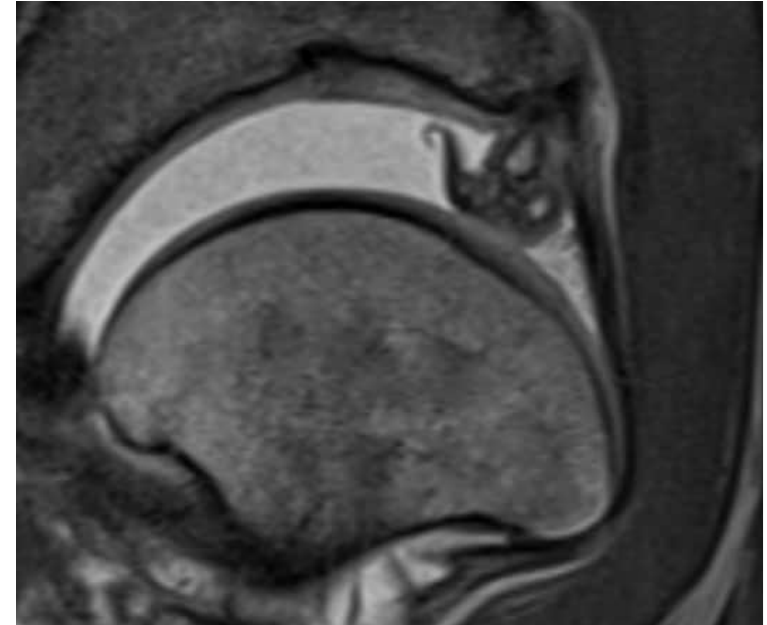
$u^b$  **Dysplasia**  
Intraarticular Damage Pattern



**Characterization:**  
Large labrum with cysts/ganglion  
Part of the hyaline cartilage remains  
attached to the labrum

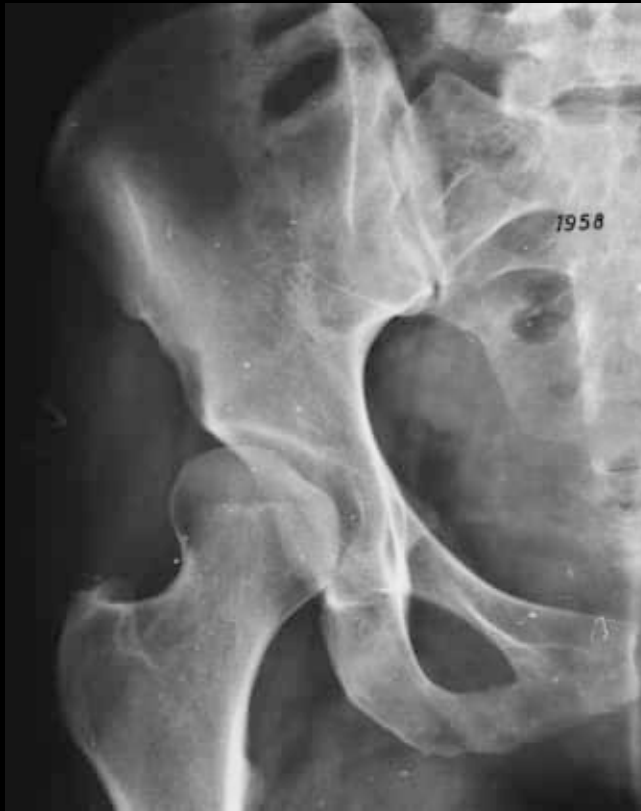

**Localization:**  
Superior/anterosuperior

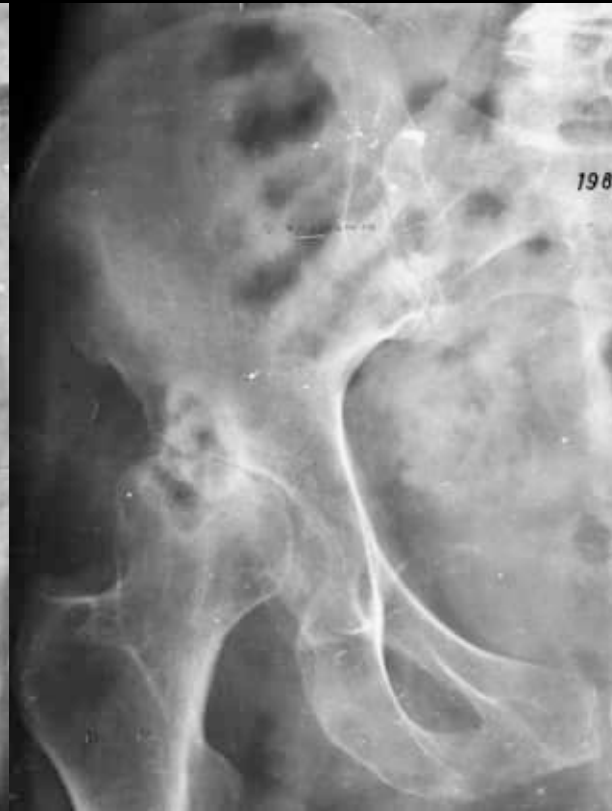

*w<sup>b</sup>*

# Hip Dysplasia Natural Course



1958



1984

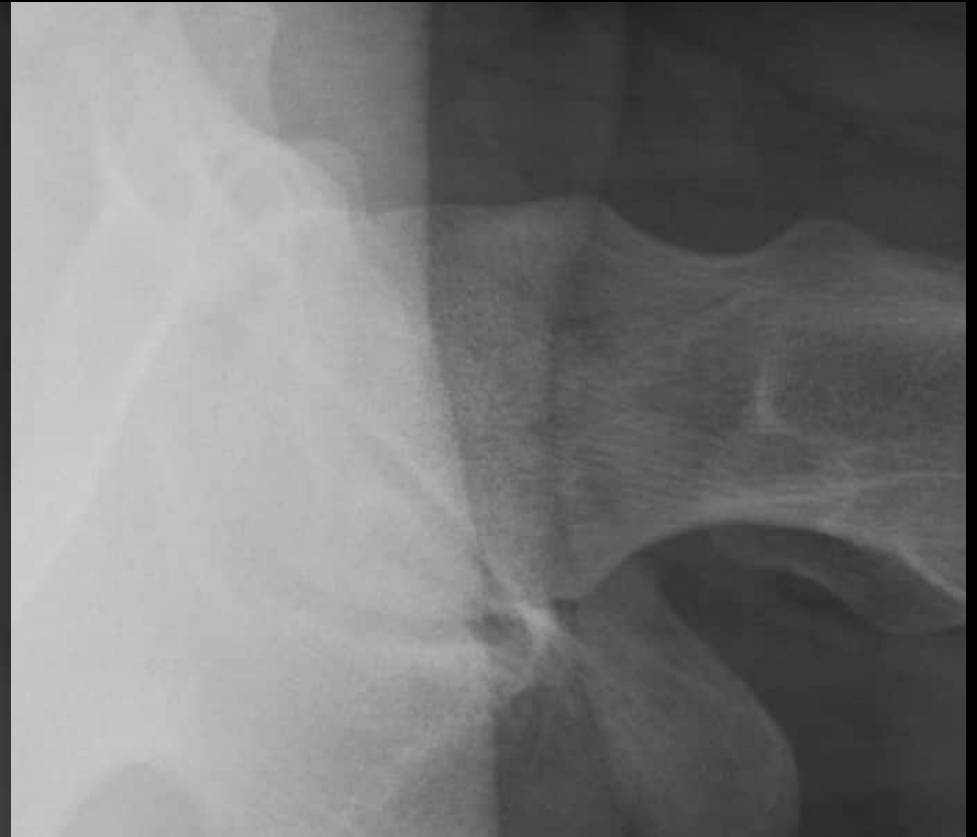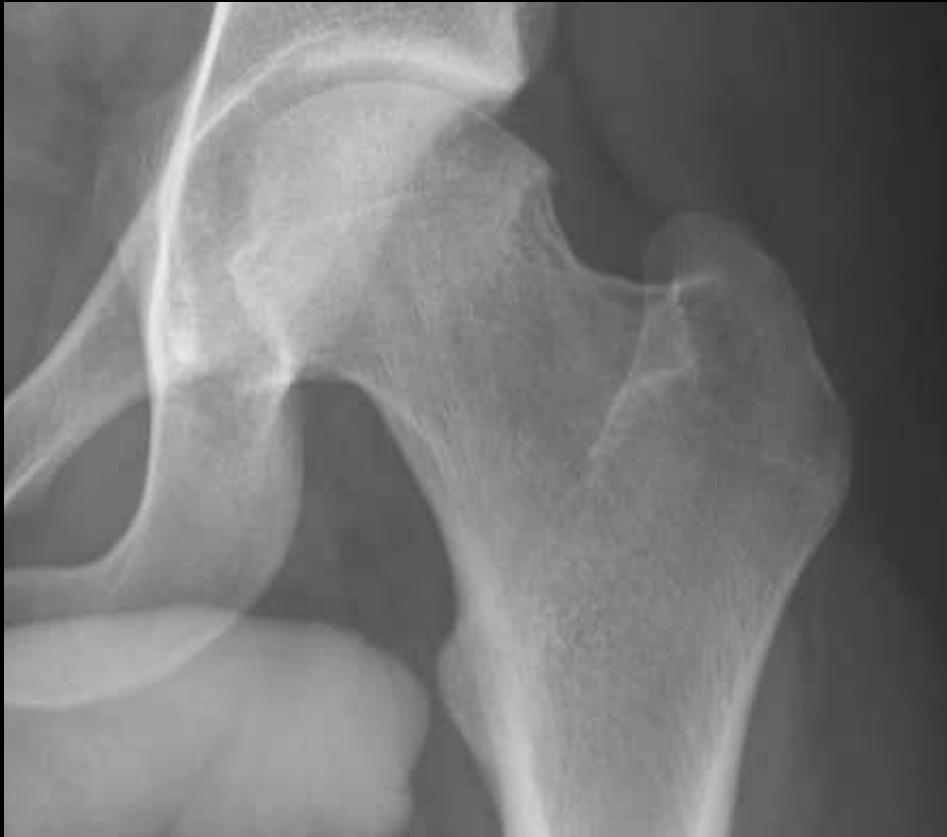---

$u^b$  Impingement: Cam



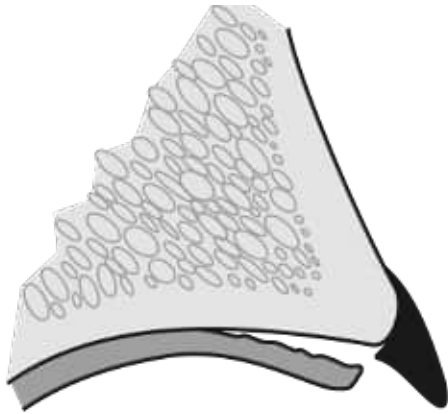
*w<sup>b</sup>*

# Impingement: Cam



---

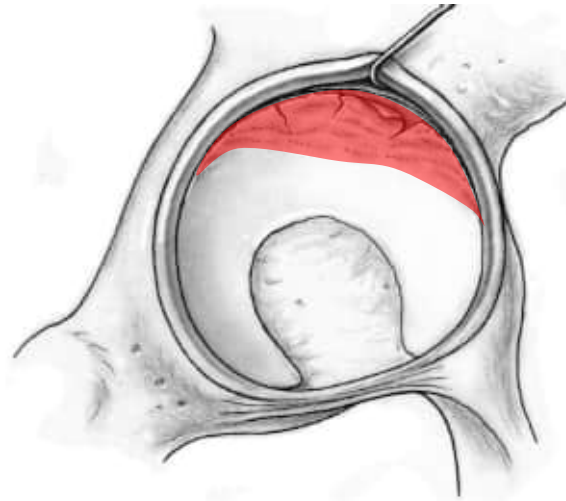
$u^b$  **Impingement: Cam**  
Intraarticular Damage Pattern



**Characterization:**

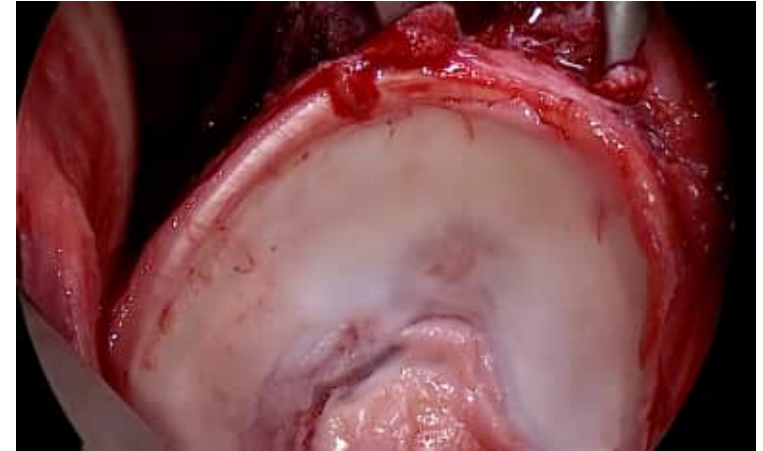Disruption of chondolabral  
junction

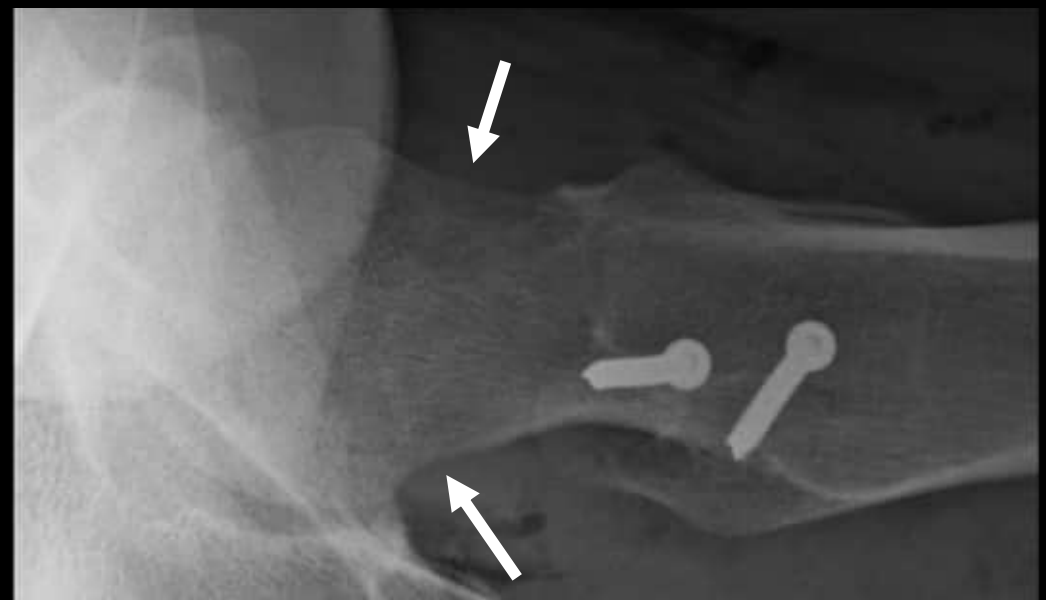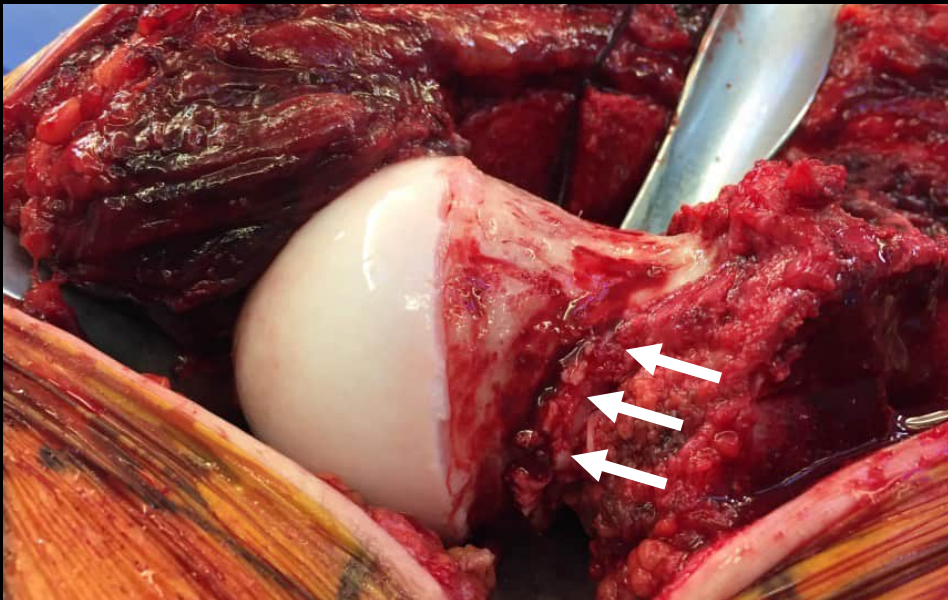
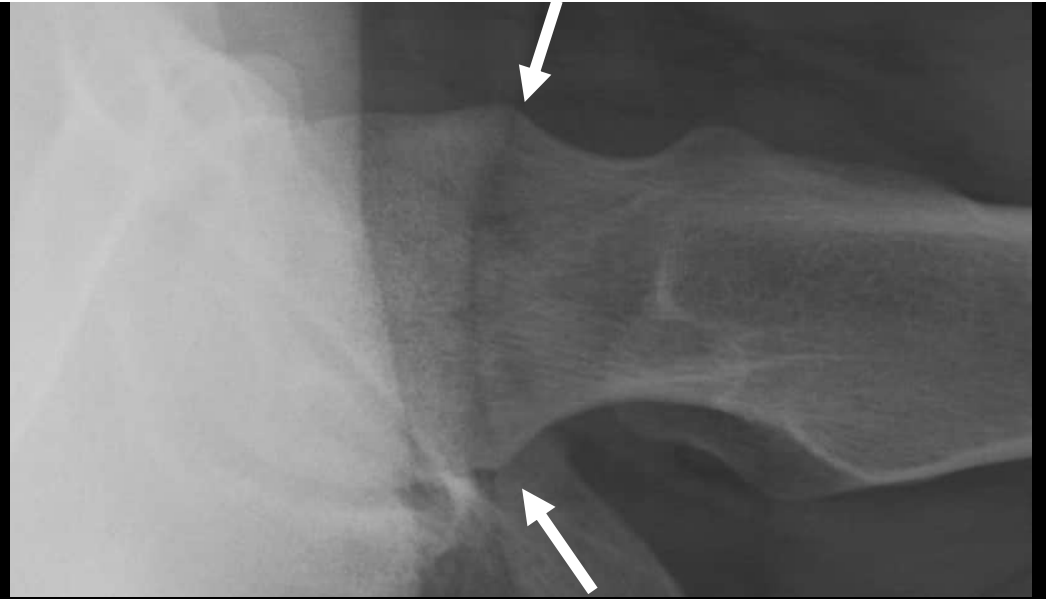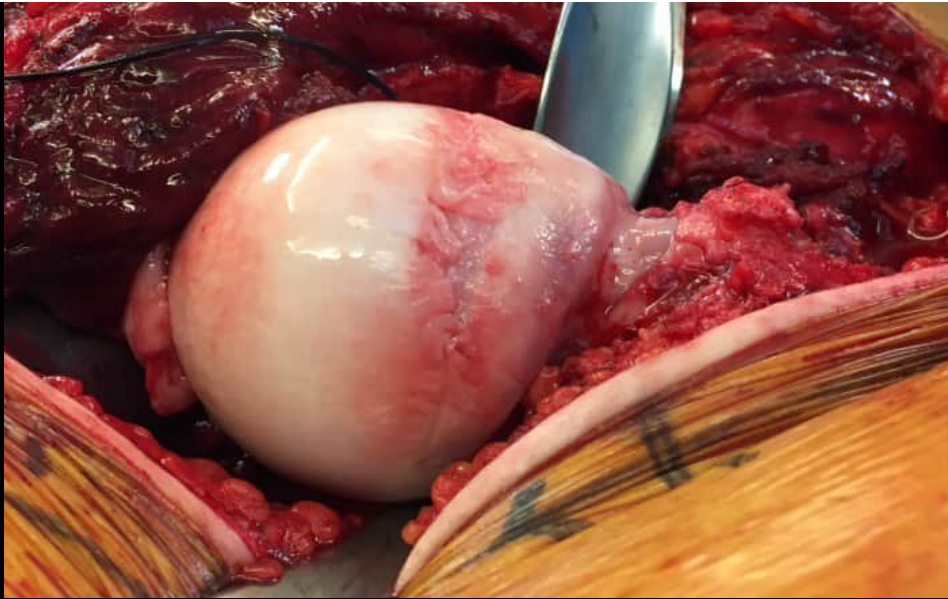Deep cartilage damage with flap  
formation



**Localization:**

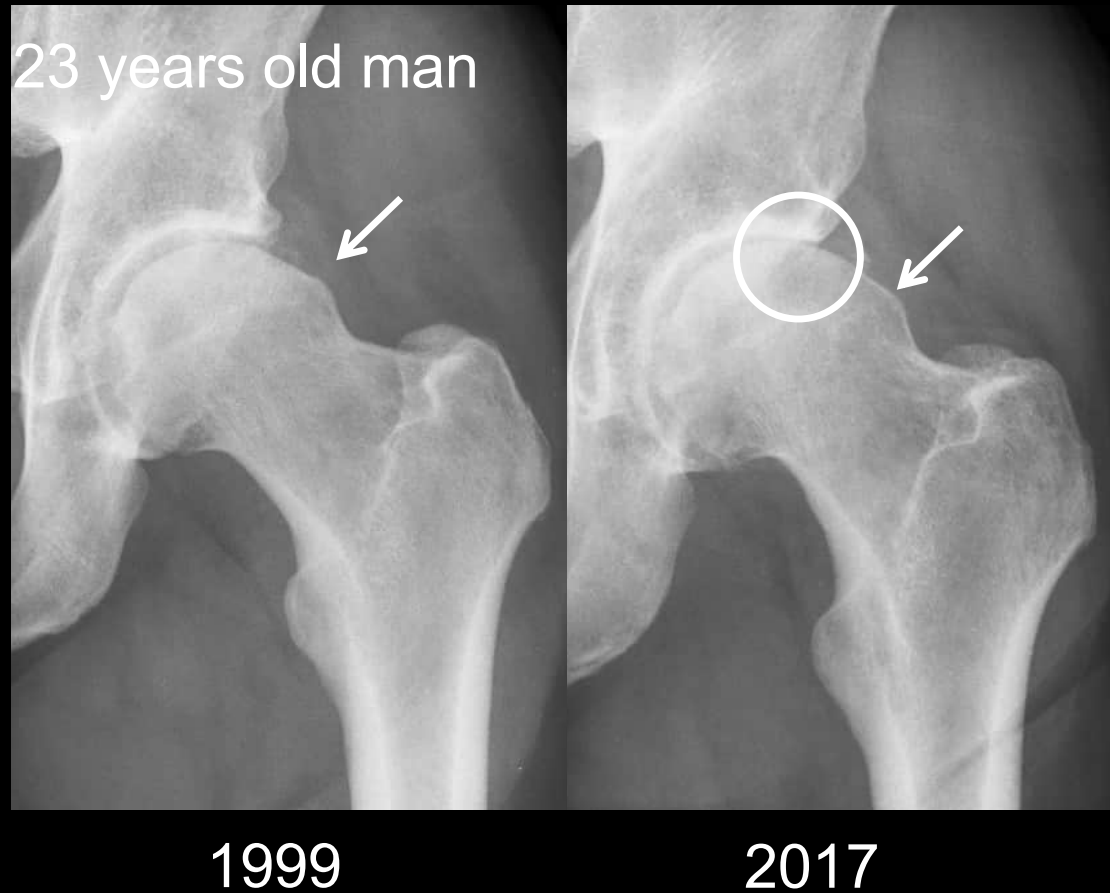
Superior/anterosuperior





*w<sup>b</sup>*

# Impingement Cam Natural Course



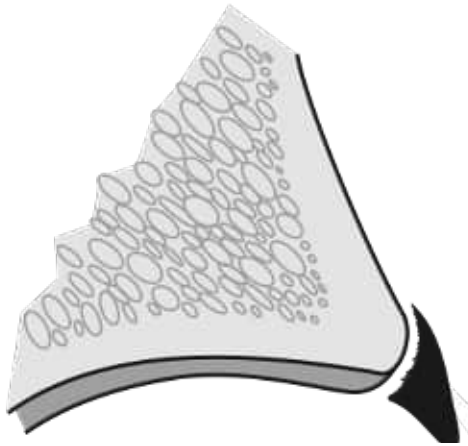
---

$u^b$  Impingement: Pincer



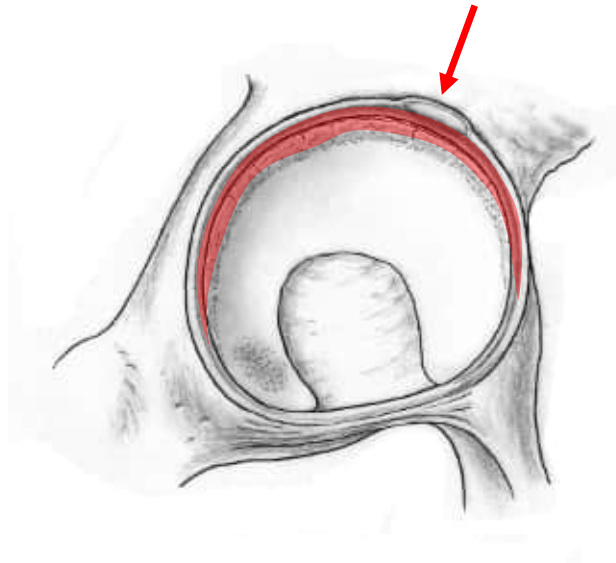
---

$u^b$  Impingement: Pincer  
Intraarticular Damage Pattern



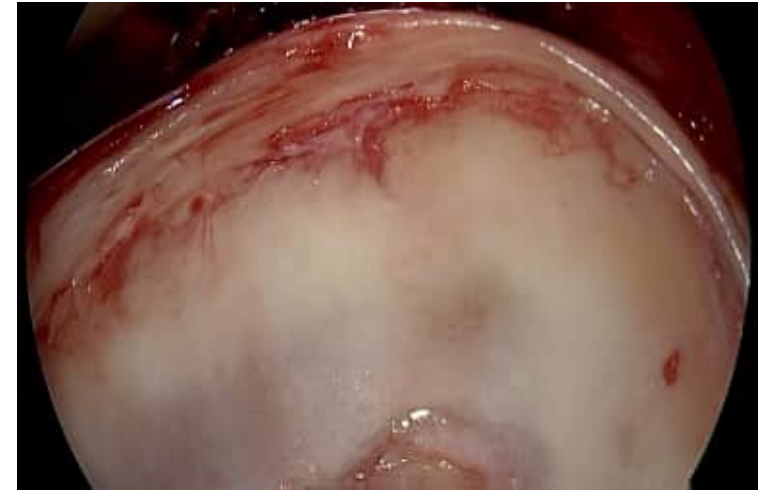**Characterization:**

Full labral lesion, calcification and ossification  
Adjacent small, circumferential cartilage lesion



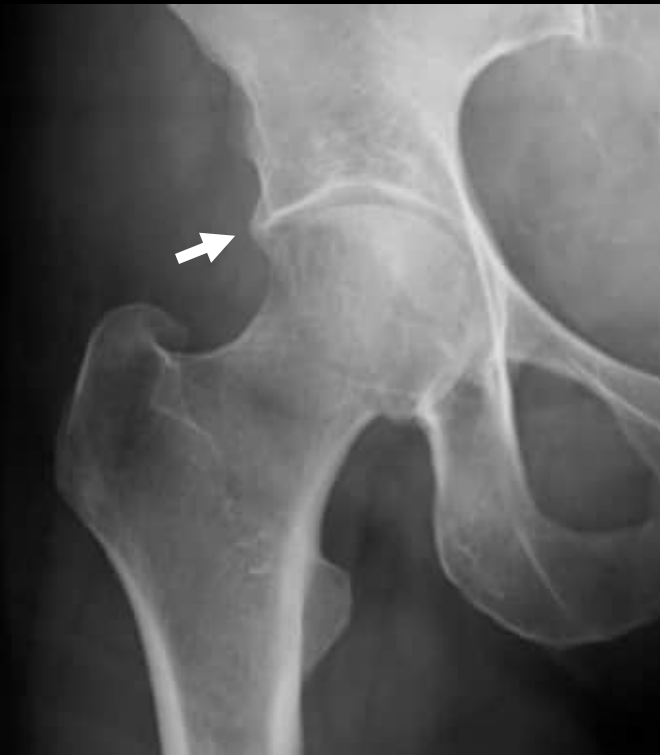**Localization:**

Superior/anterosuperior

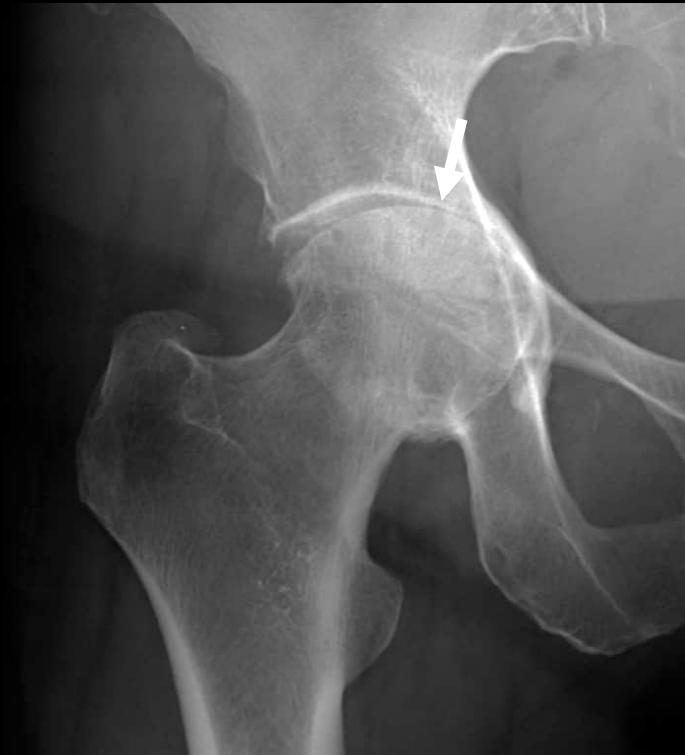

*w<sup>b</sup>*

# Protrusio: Natural Course



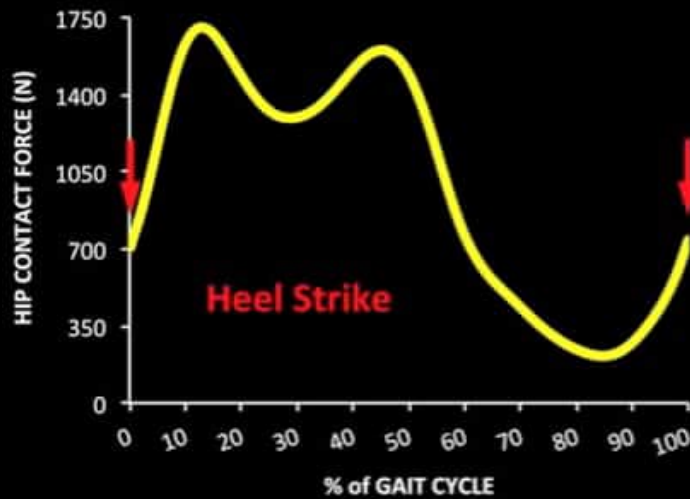
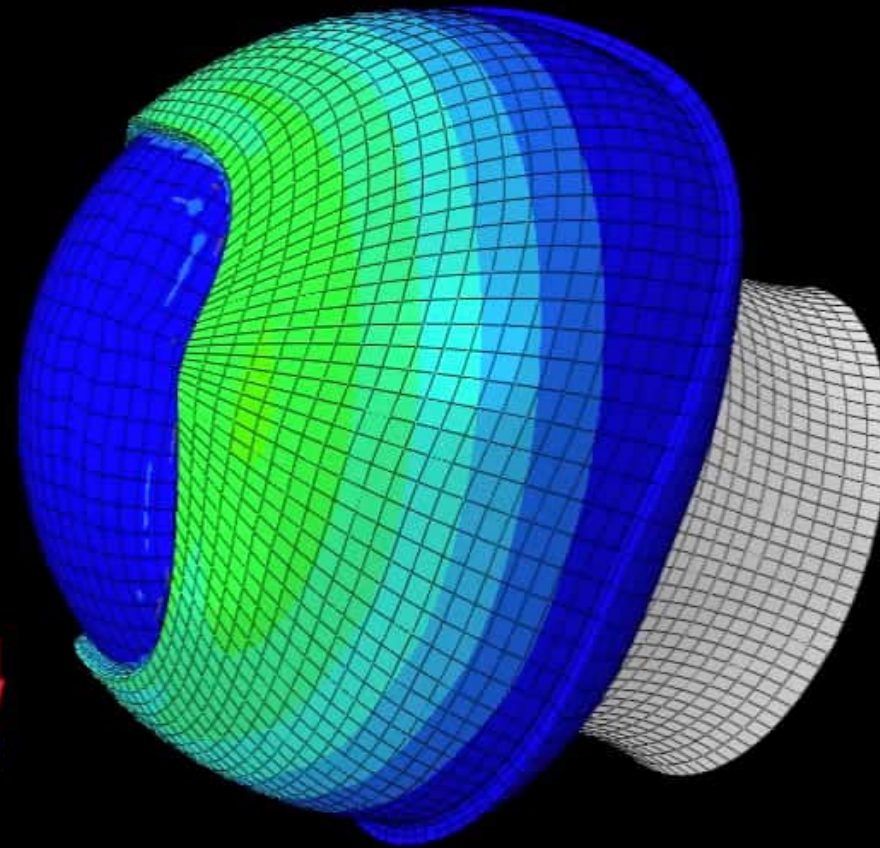
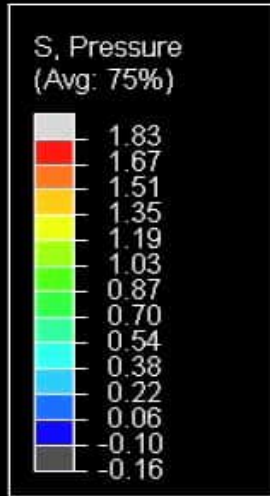
39-years old patient



15 years later...

# Protrusio - Walking

Posterosuperior view of a right hip joint

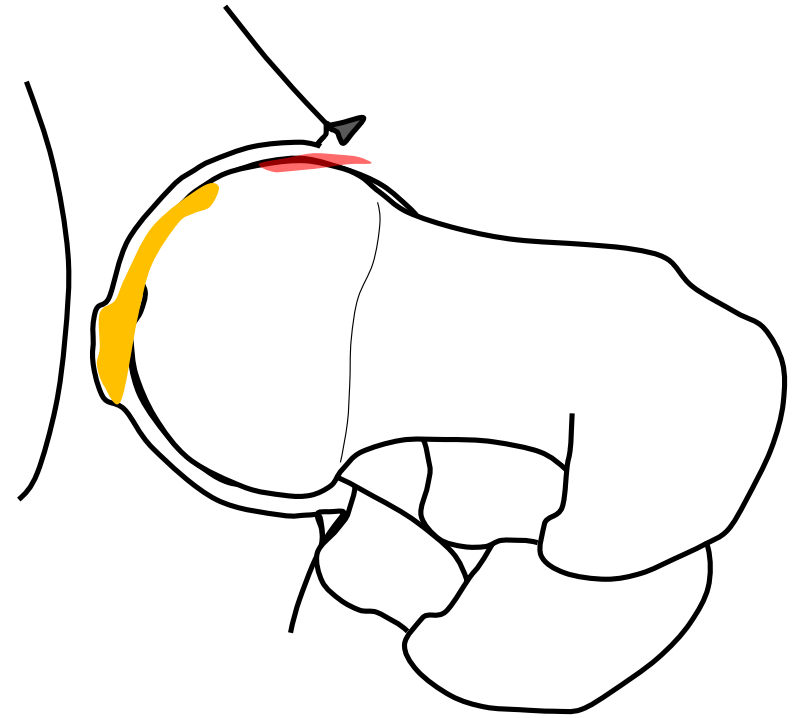
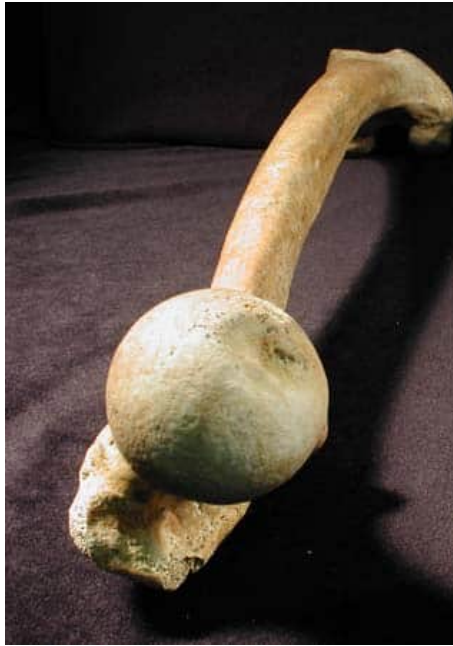

---

$u^b$

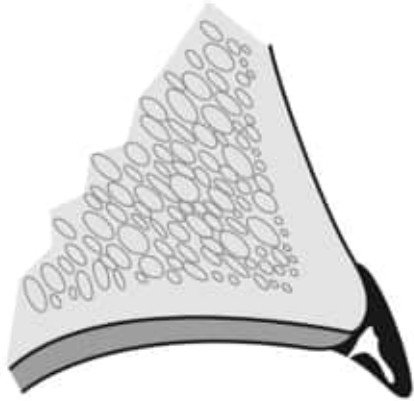# Femoral Maltorsion

## Levering Out



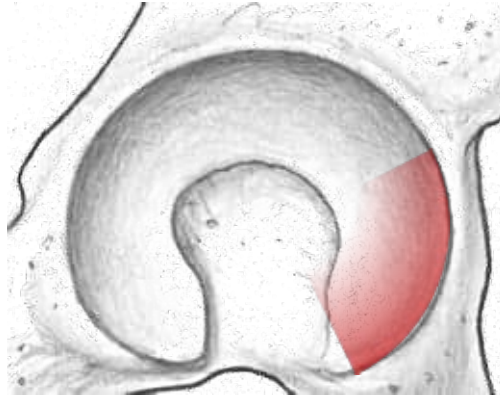
---

$u^b$  **Femoral Antetorsion**  
Intraarticular Damage Pattern

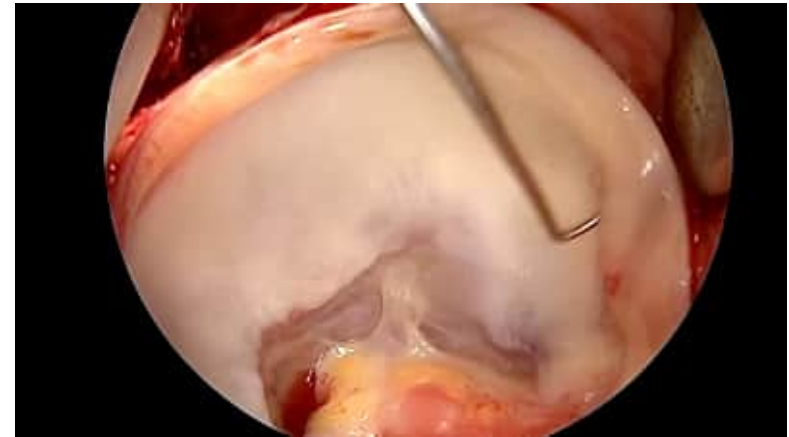

**Characterization:**  
Large labrum  
which appears 'empty'

Small adjacent cartilage lesion

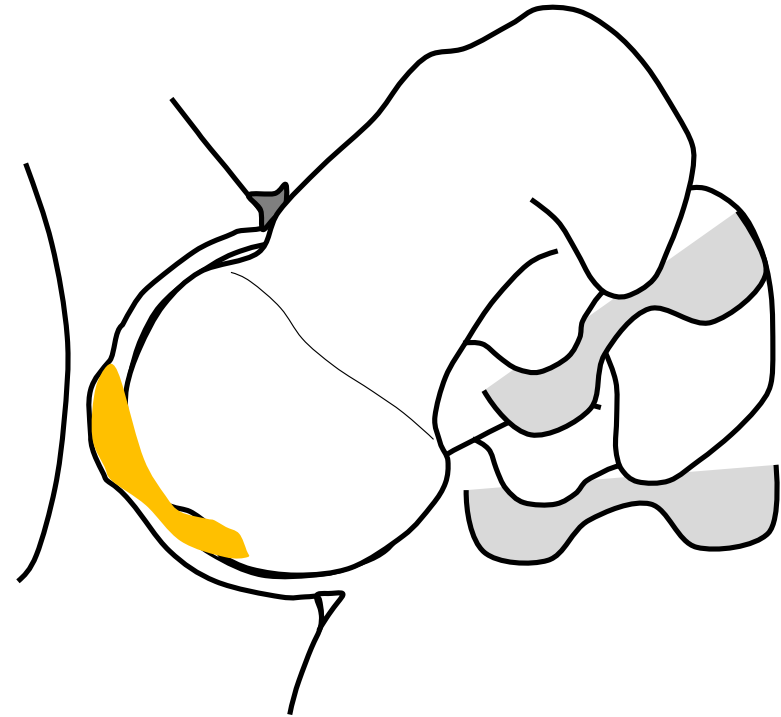


**Localization:**  
Anteroinferior (contre coup)



$u^b$

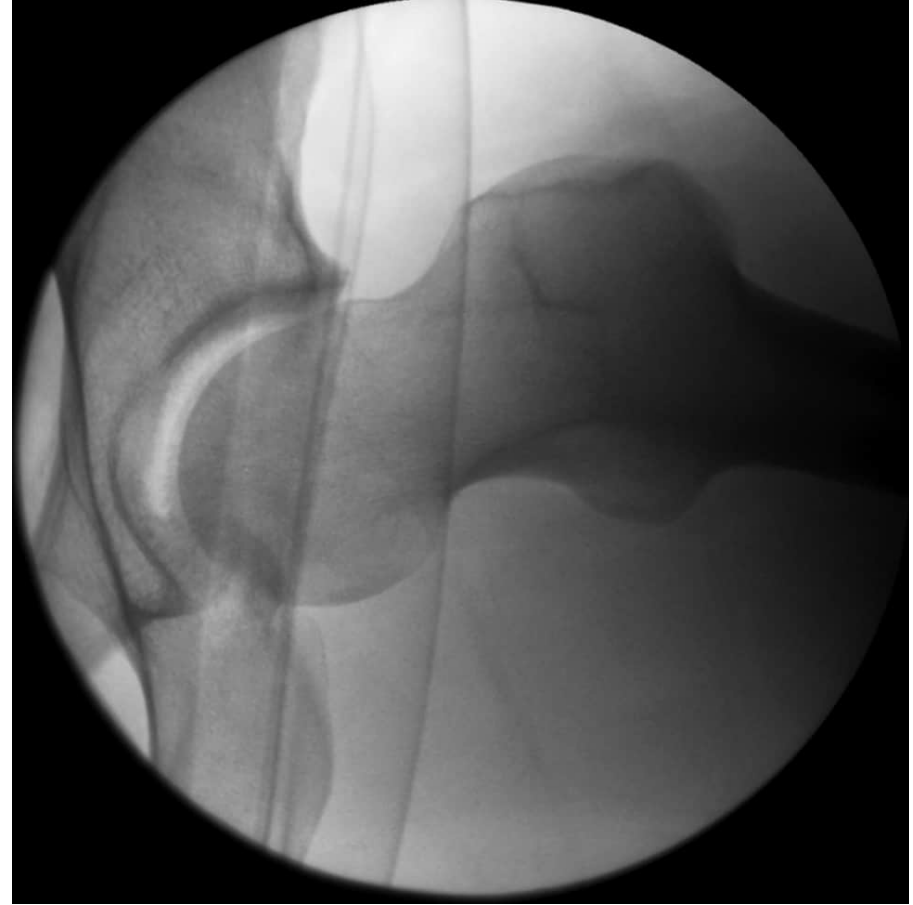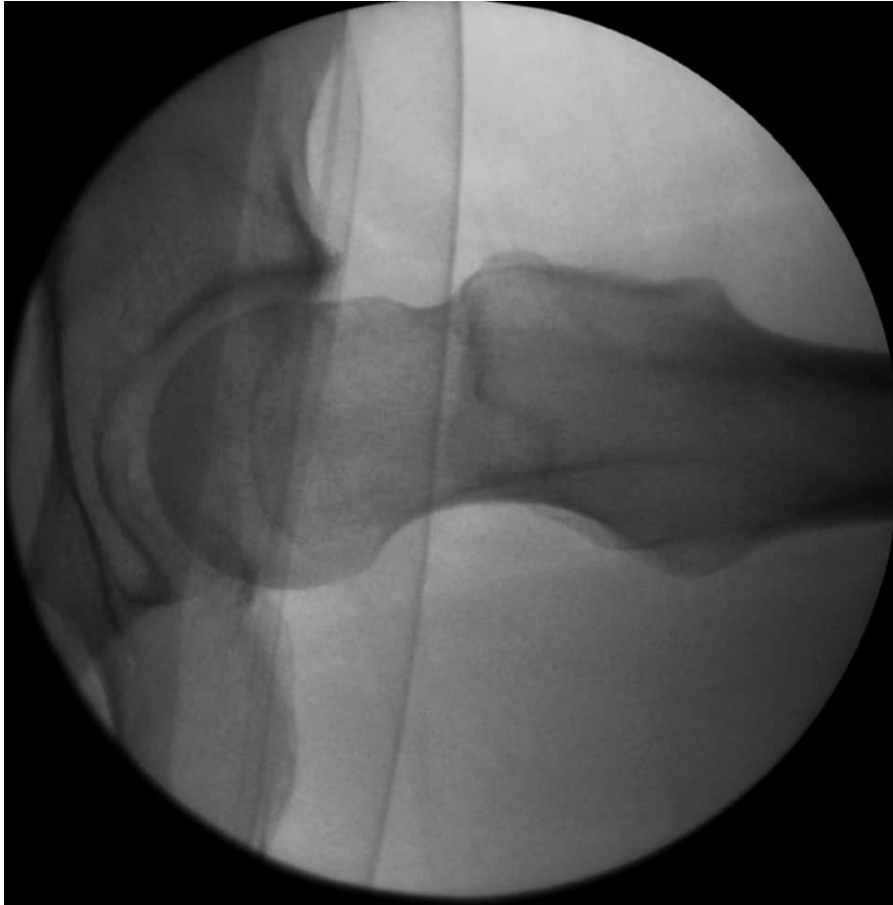
# Femoral Retrotorsion Levering Out



*Steppacher et al, CORR, 2013*  
*Tibor et al, BJJ, 2012*

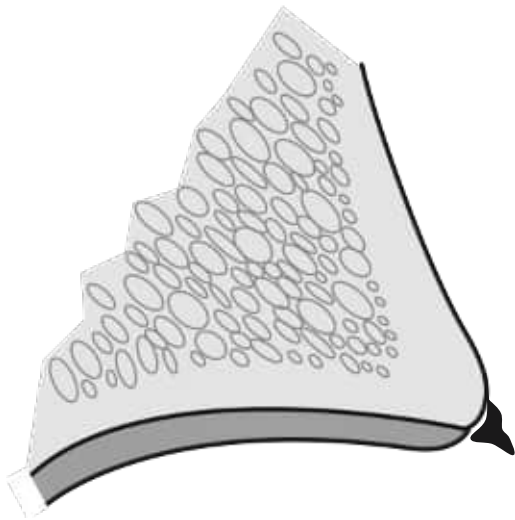
---

$u^b$  Levering Out: Femoral Retrotorsion

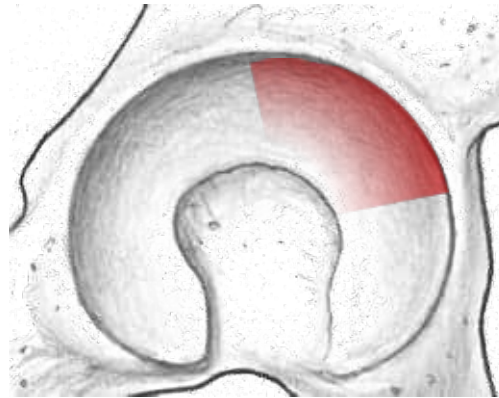


---

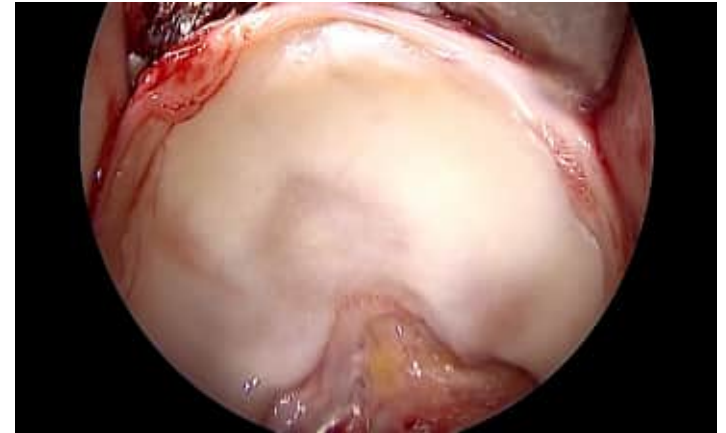
$u^b$  **Femoral Retrotorsion**  
Intraarticular Damage Pattern



**Characterization:**  
Very small or absent labrum  
Adjacent cartilage lesion



**Localization:**  
Anterosuperior



---

$u^b$

## Summary

Labral tear  $\neq$  Labral tear



Distinct differences in size, shape, location



Careful radiographic preoperative evaluation  
and interpretation necessary for appropriate surgical treatment