
u^b

Precourse Hip Symposium Bern 2026

What to do: Cam Impingement

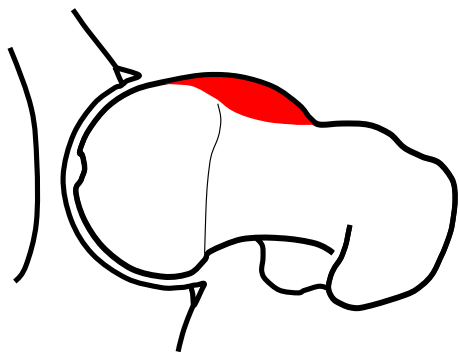
Alexander F. Heimann

Department of Orthopaedic Surgery and Traumatology, HFR, University of Fribourg, Switzerland

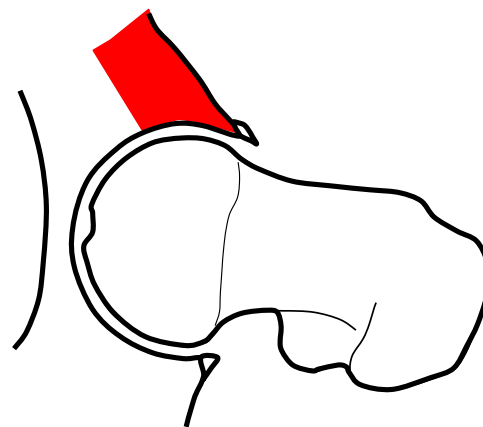
u^b

Femoroacetabular Impingement

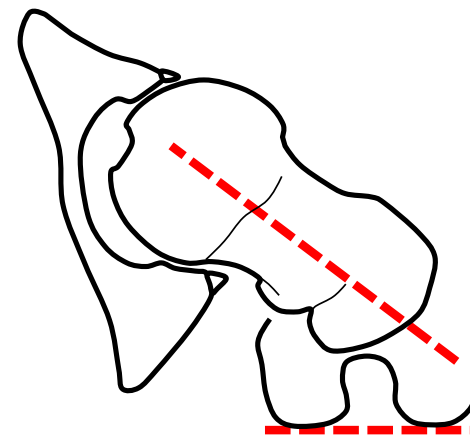
Cam



Pincer



Torsional Deformities



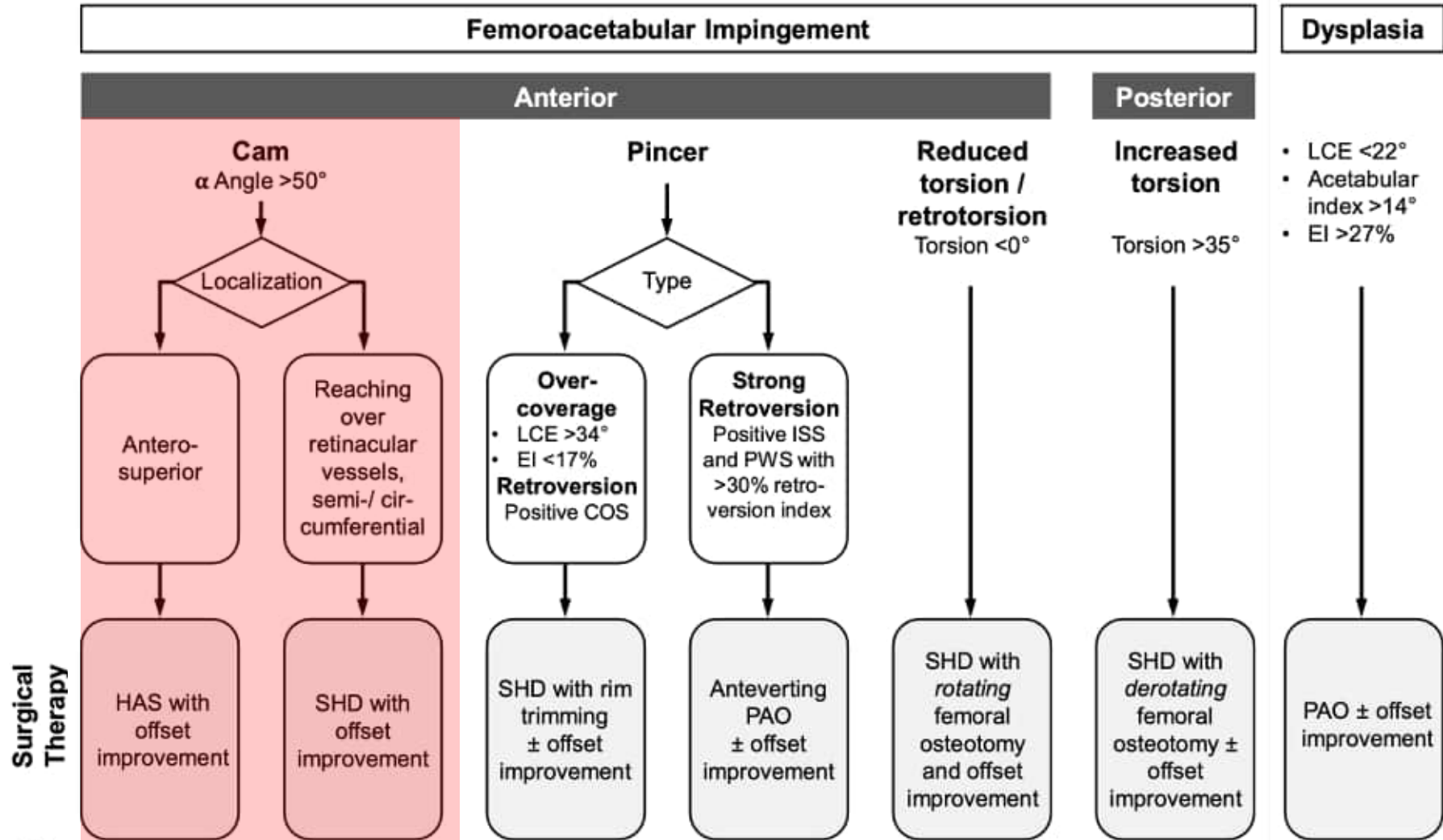
u^b

Aim

Presenting the Bernese treatment concept for **cam**
Impingement

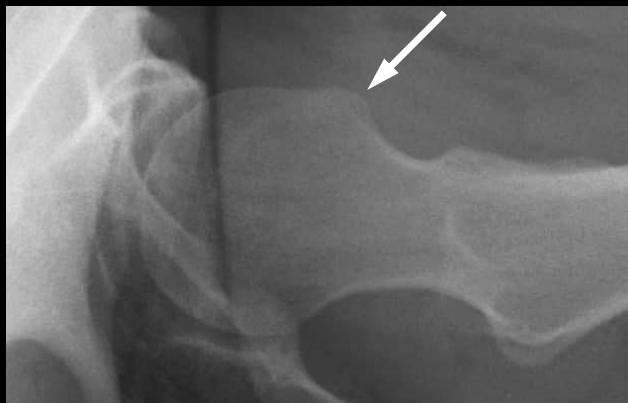u^b

Treatment Algorithm

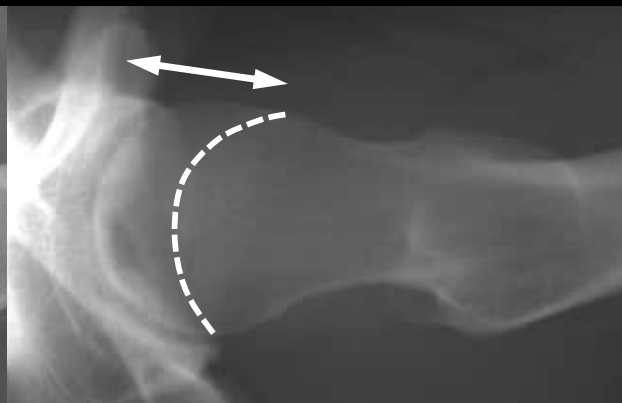


w^b Etiology of Cam Morphology

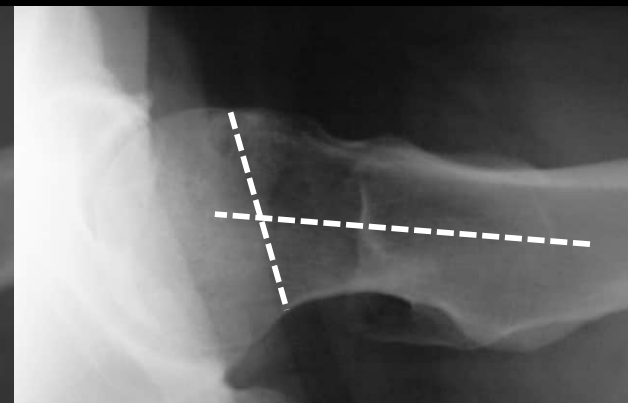
Exostosis



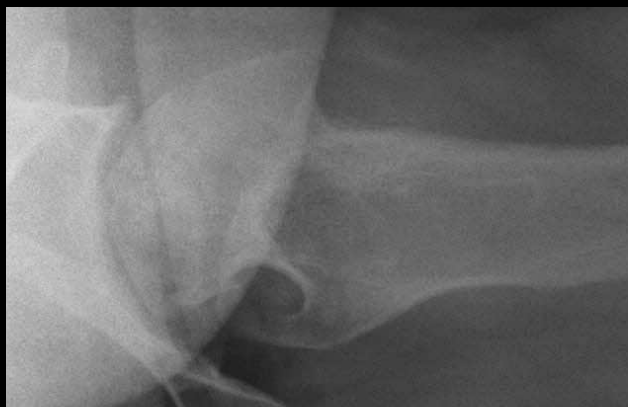Extended Growth Plate



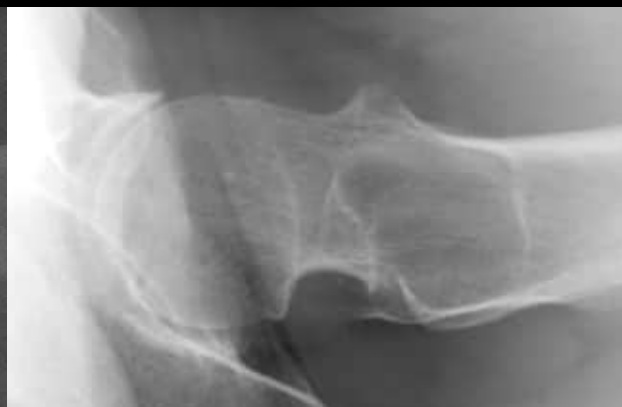SCFE



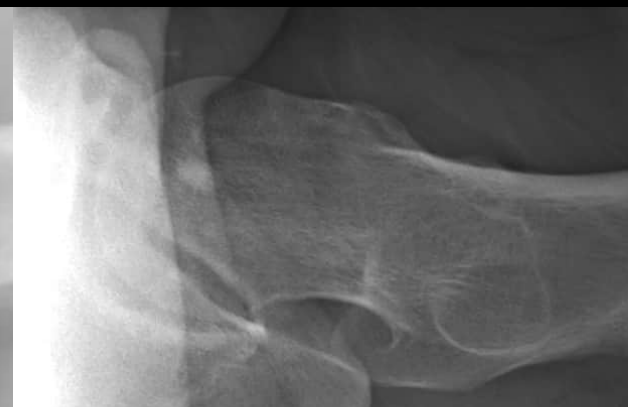LCPD



Posttraumatic

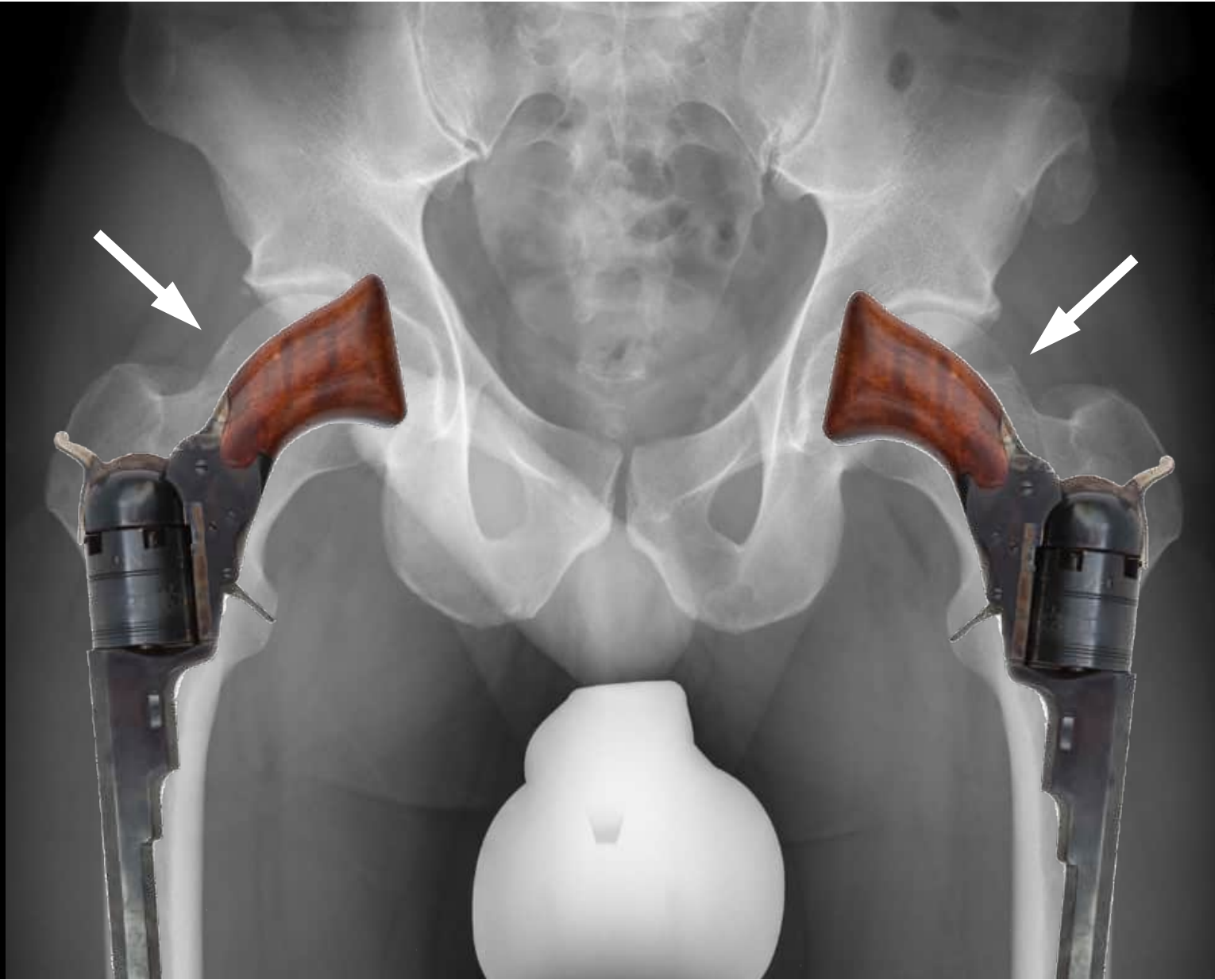


Tumor (osteochondroma)

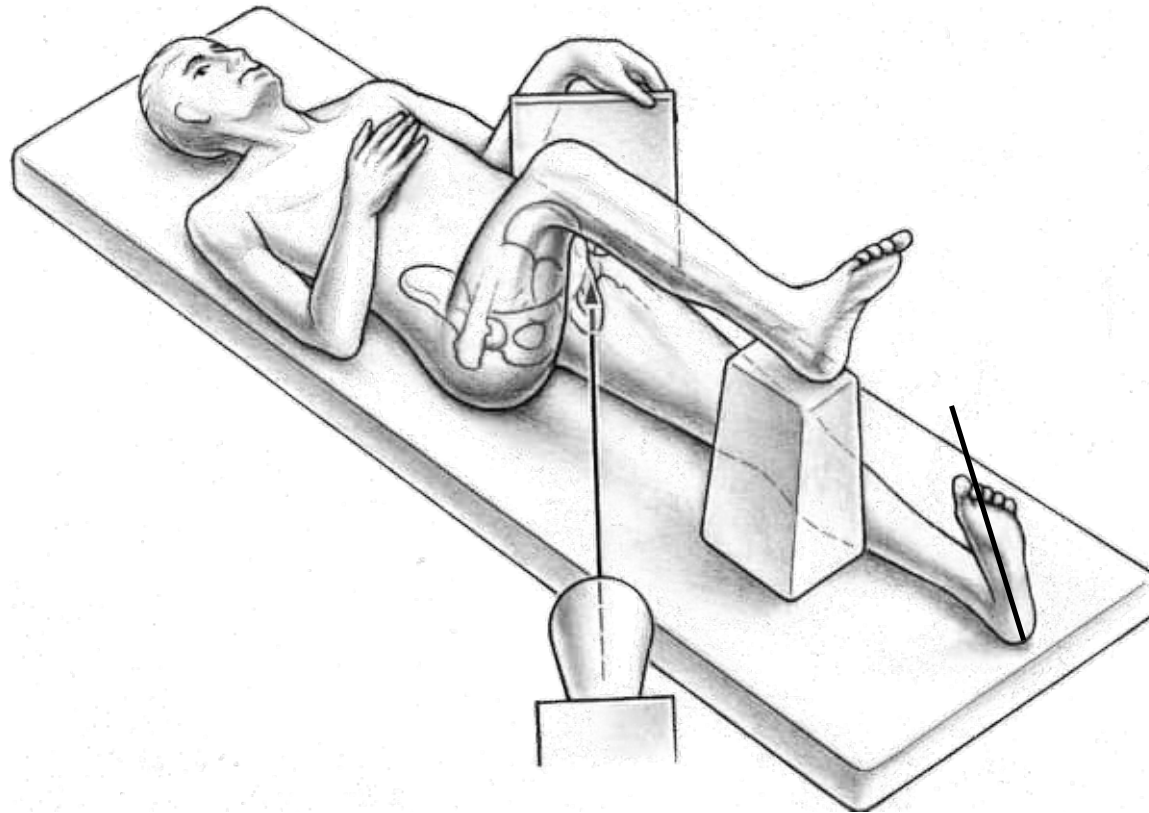


u^b Imaging for Cam Deformity

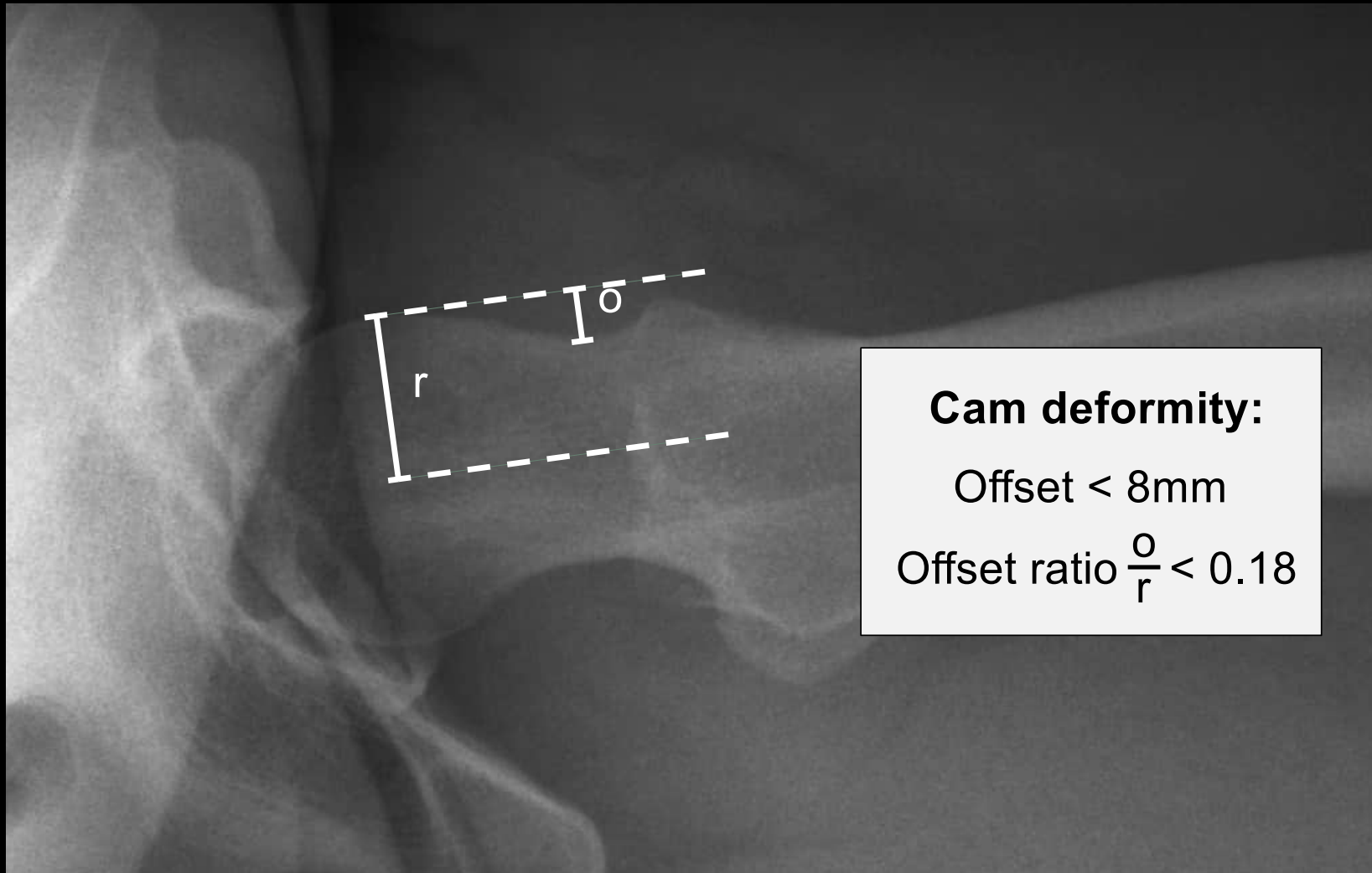
Modality	
Conventional	<ul style="list-style-type: none">- Pelvis anteroposterior (AP)- Axial view (cross-table, Dunn, Lauenstein, modified Budin)
Arthro-MRI	<ul style="list-style-type: none">- Cartilage and labrum damage- Localisation and extension of the cam lesion
Computed Tomography	<ul style="list-style-type: none">- Computer-based animation of hip range of motion



u^b Axial View (Cross-Table View)



Anterior



Cam deformity:

Offset < 8mm

Offset ratio $\frac{o}{r} < 0.18$

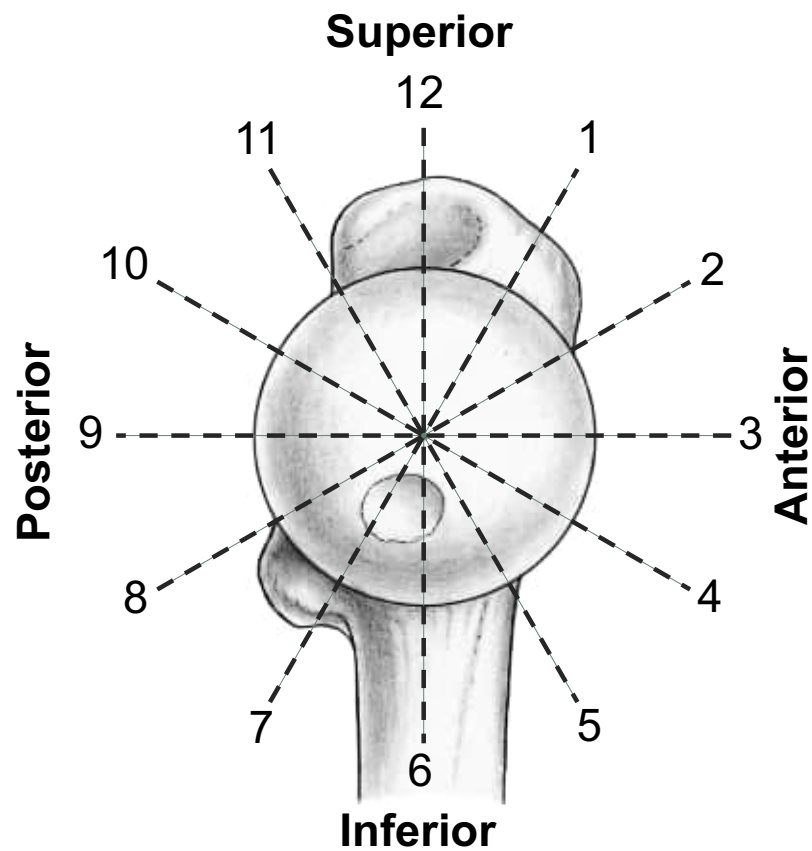
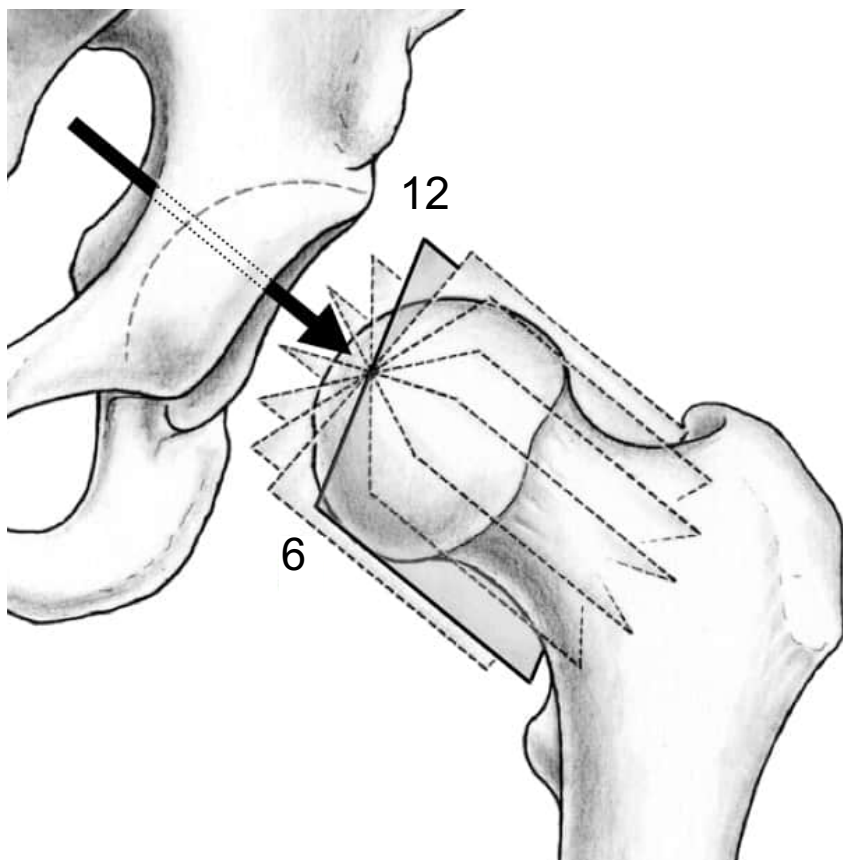
Posterior

u^b Imaging for Cam Deformity

Modality	
Conventional	<ul style="list-style-type: none">- Pelvis anteroposterior (AP)- Axial view (cross-table, Dunn, Lauenstein, modified Budin)
Arthro-MRI	<ul style="list-style-type: none">- Cartilage and labrum damage- Localisation and extension of the cam lesion
Computed Tomography	<ul style="list-style-type: none">- Computer-based animation of hip range of motion

u^b

Arthro MRI of the Hip



u^b Imaging for Cam Deformity

Modality	
Conventional	<ul style="list-style-type: none">- Pelvis anteroposterior (AP)- Axial view (cross-table, Dunn, Lauenstein, modified Budin)
Arthro-MRI	<ul style="list-style-type: none">- Cartilage and labrum damage- Localisation and extension of the cam lesion
Computed Tomography	<ul style="list-style-type: none">- Computer-based animation of hip range of motion

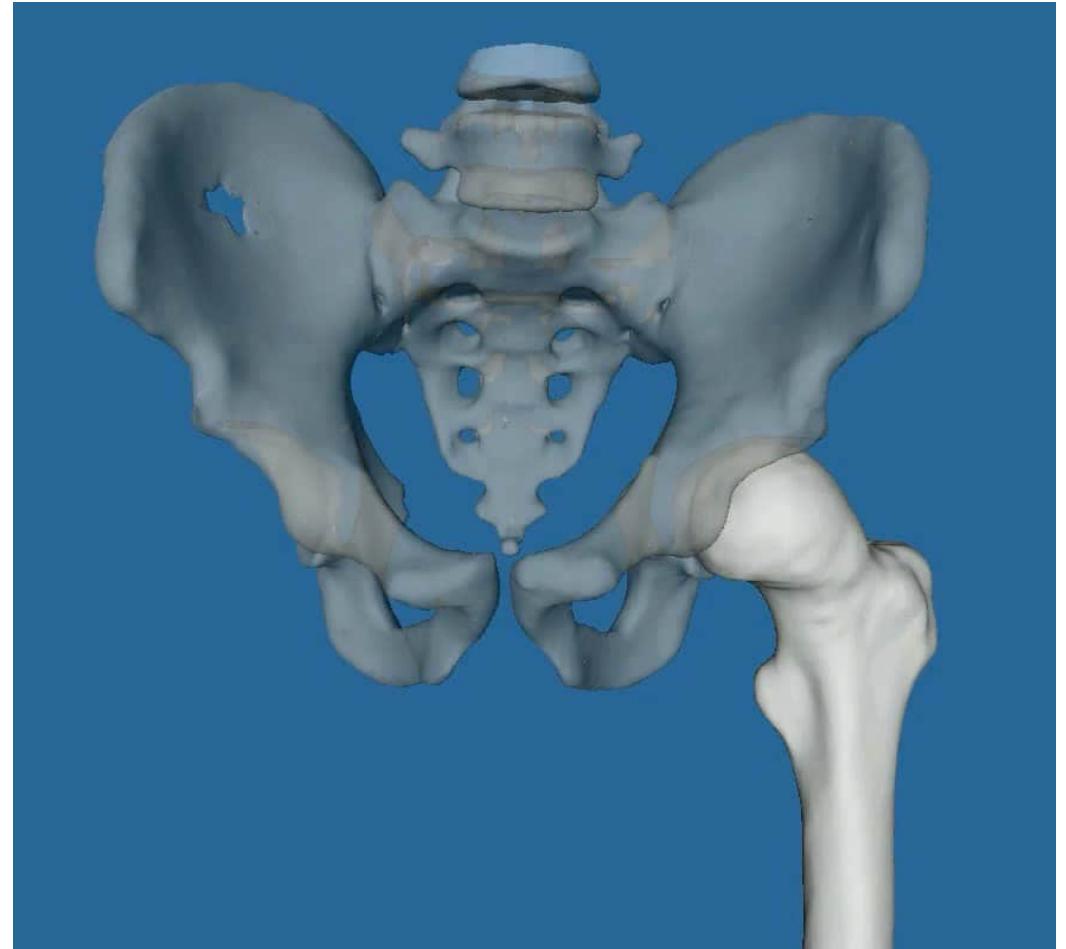
u^b

Computed Tomography

Segmentation and dynamic evaluation

Simulation of range of motion, impingement zones and surgical resection

Not indicated for isolated cam deformity



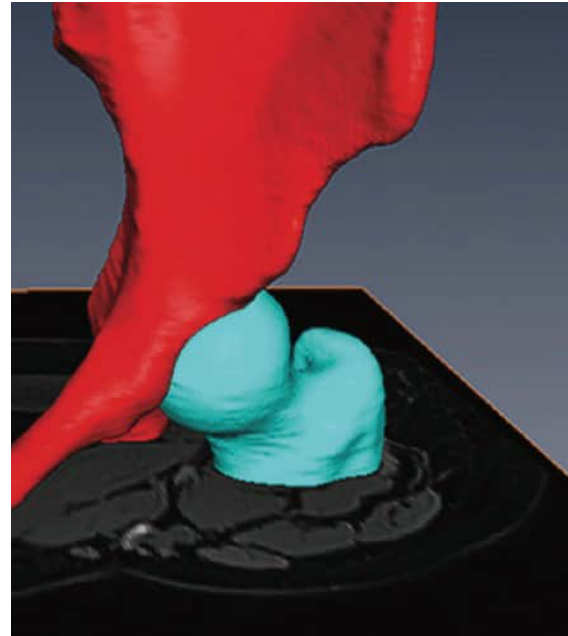
u^b

3D Segmentation

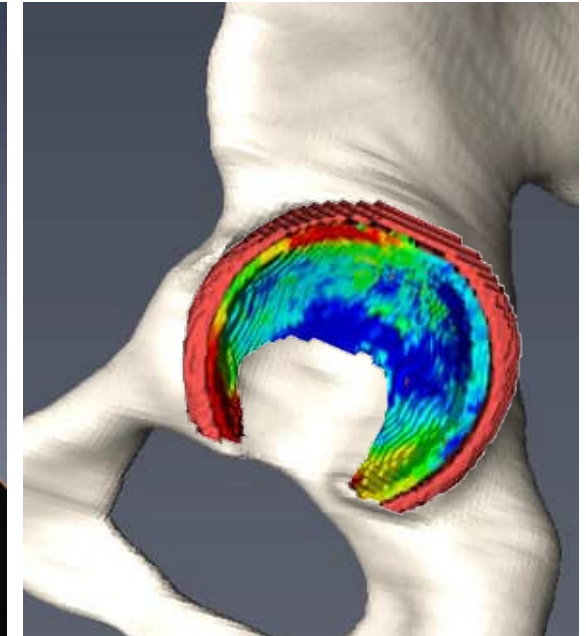
**MRI-based 3D models
using machine-learning
and AI**

Segmentation of

- bone
- cartilage
- labrum
- integration of quantitative cartilage quality information



Bone



Cartilage and Labrum

*Lerch et al, Orthop J Sports Med. 2025
Meier et al, Am J Sports Med, 2025
Zeng et al, Orth J Sports Med, 2021*

u^b

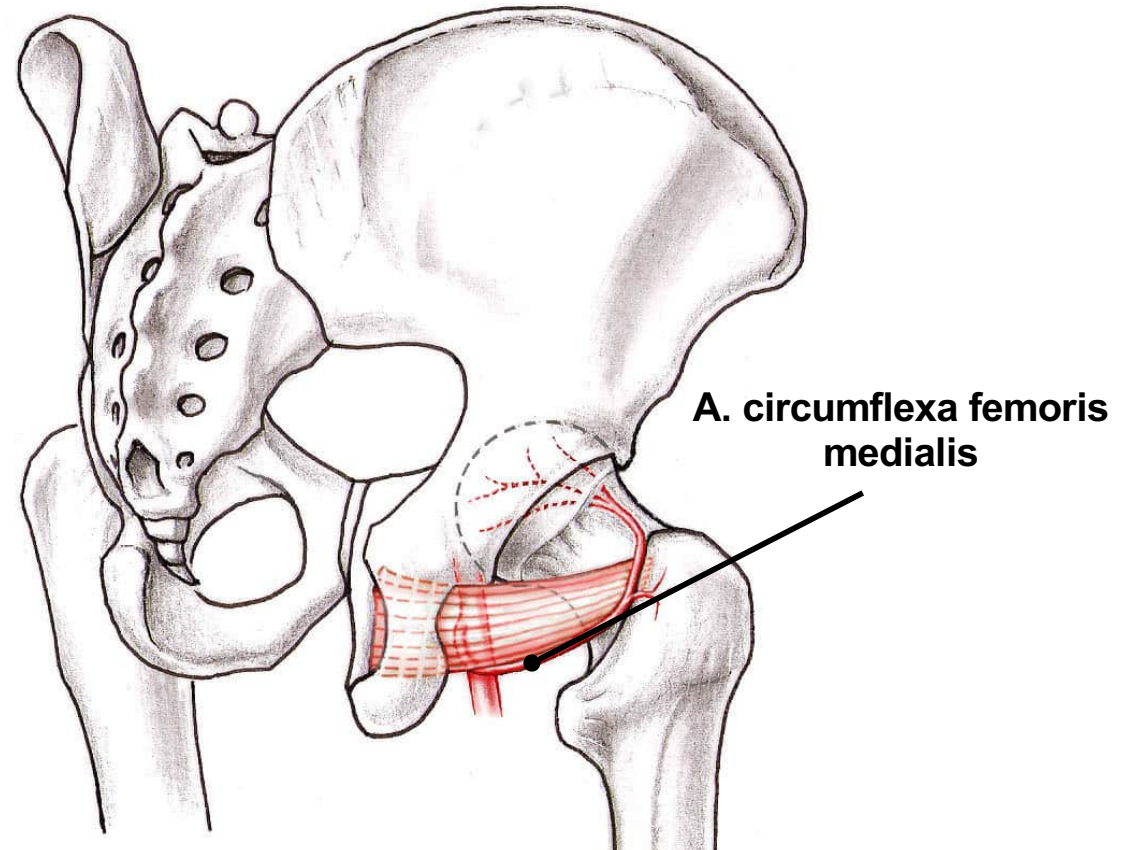
Surgical Therapy of the Cam Deformity

Options:

- Hip arthroscopy
- Open surgery

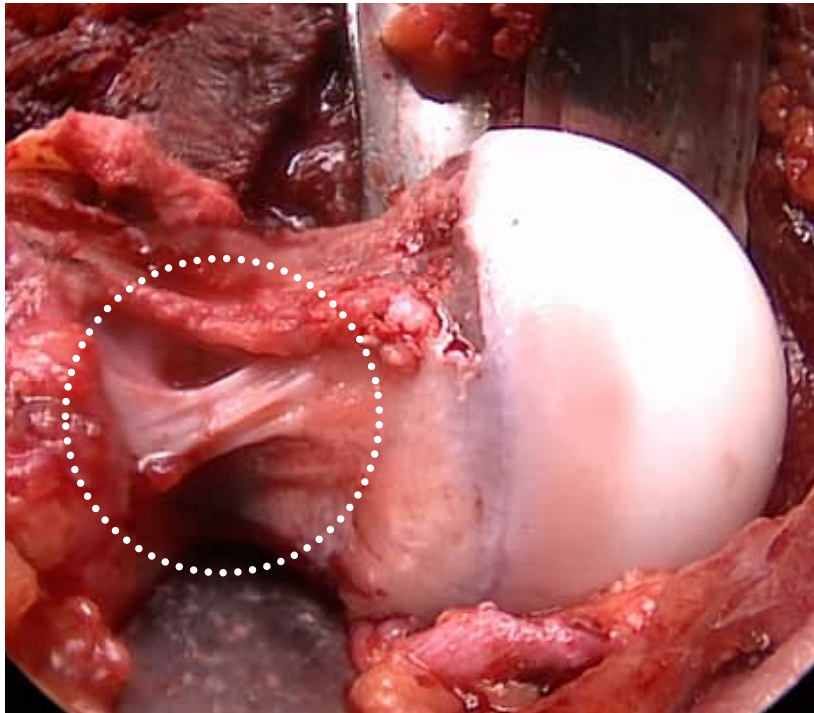
Indication dependent on:

- **Localisation**
- **Extension**
- Relation to the **retinacular vessels**

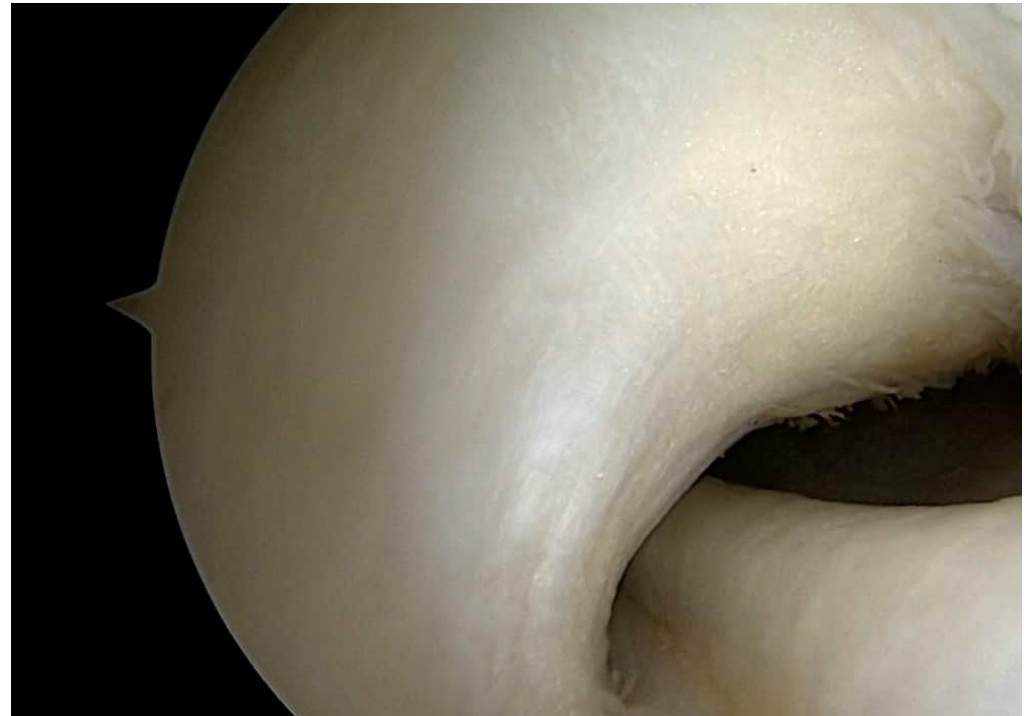

u^b

Retinacular Vessels



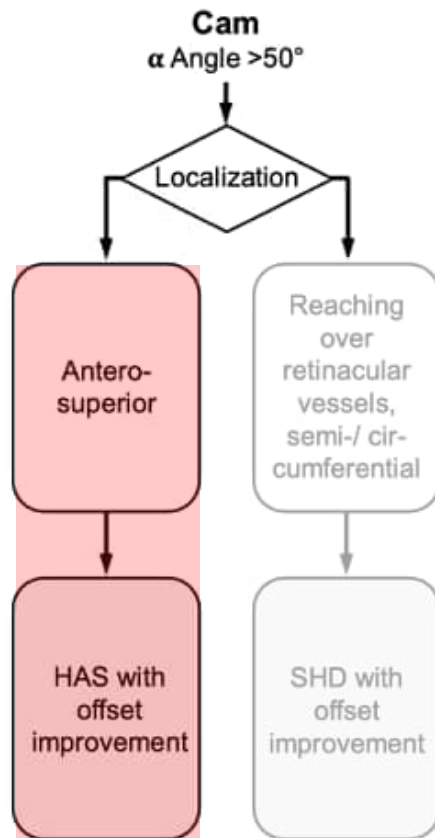
Open Surgery



Arthroscopy

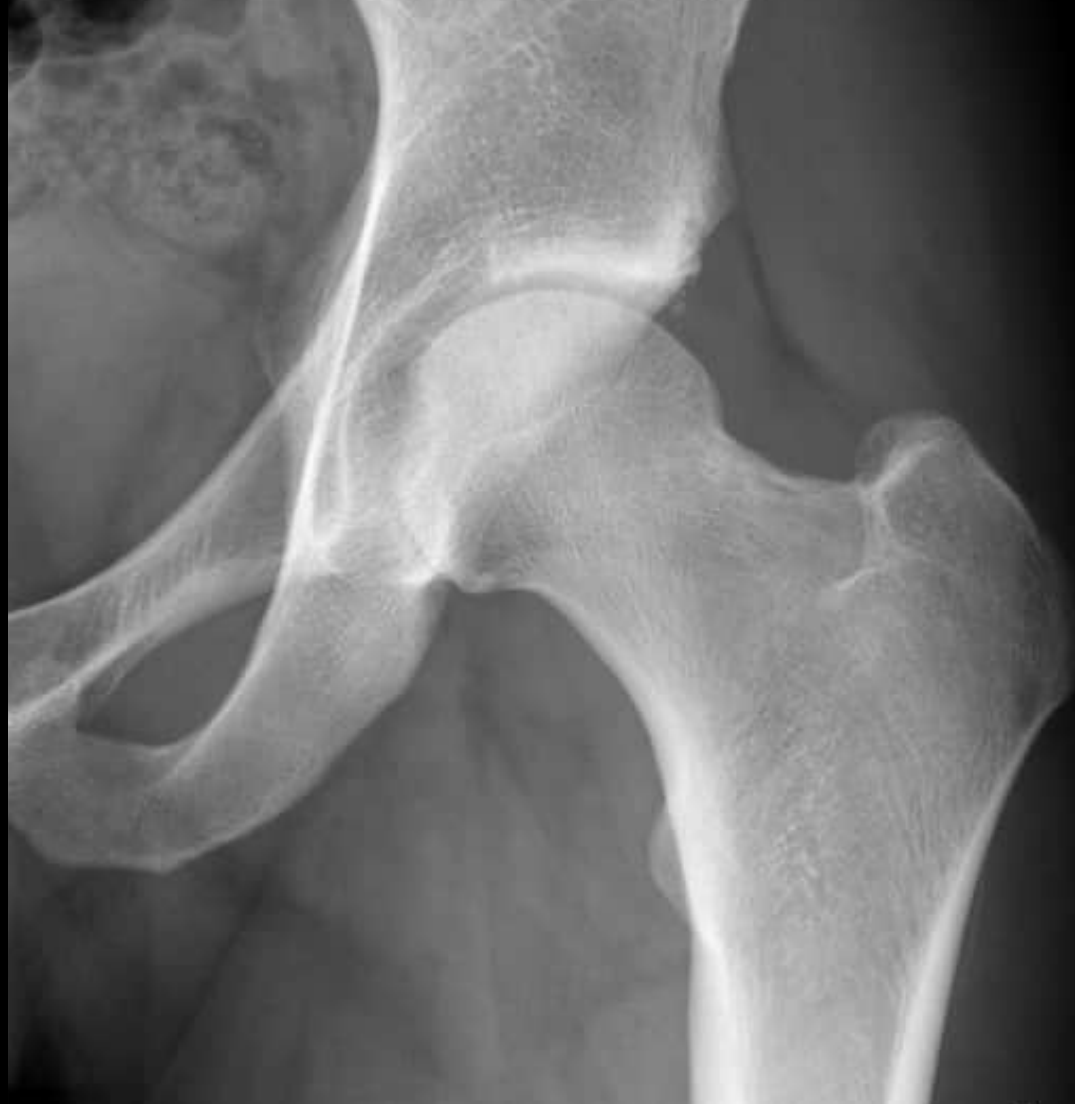u^b

Treatment Concept Cam Deformity

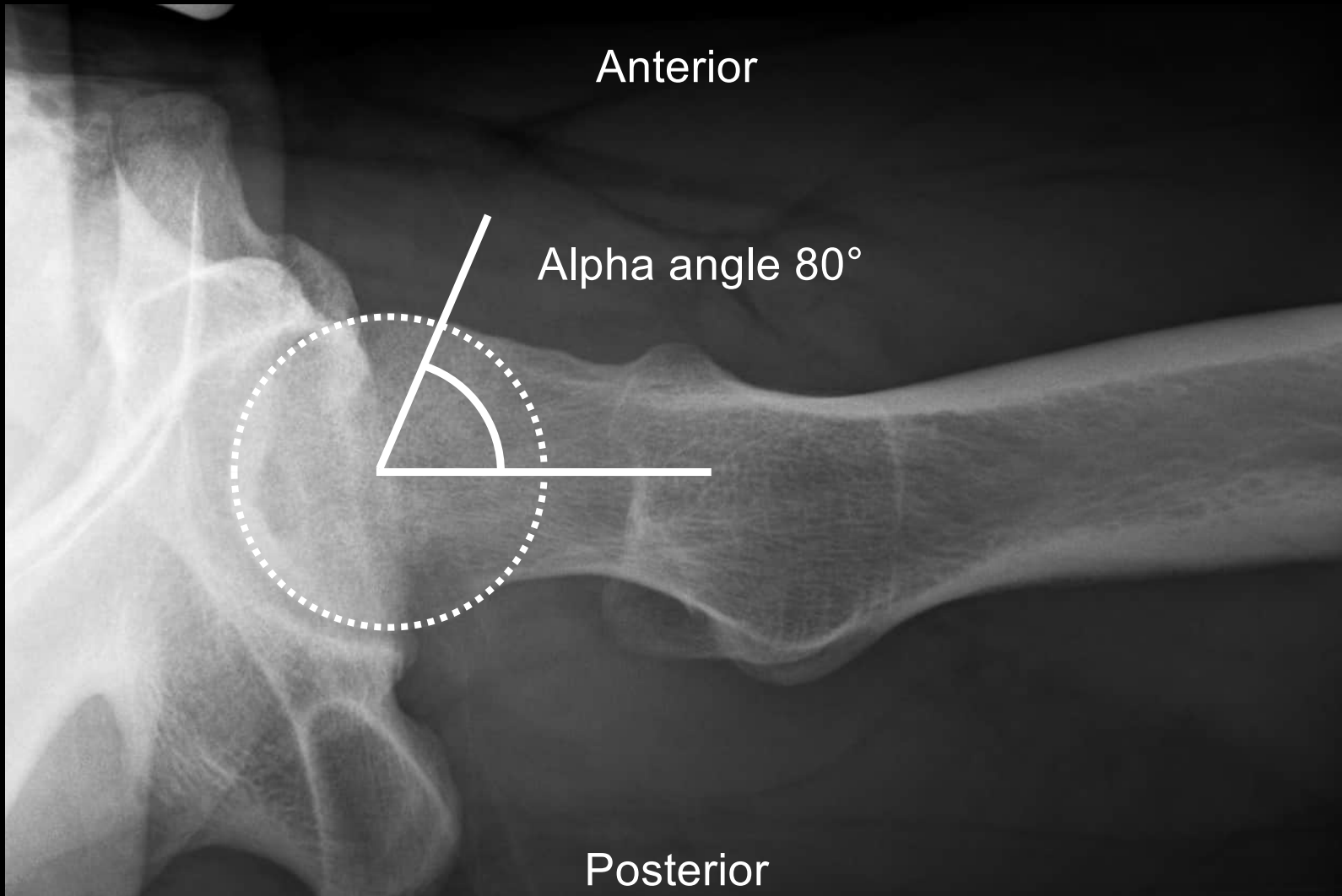


Hip arthroscopy

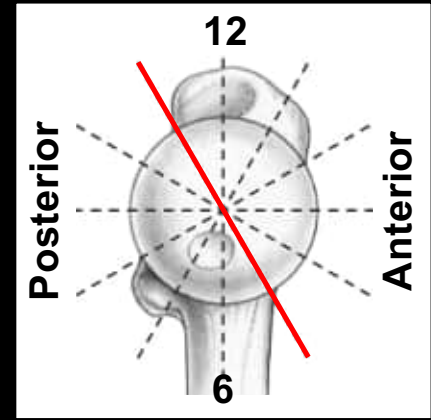
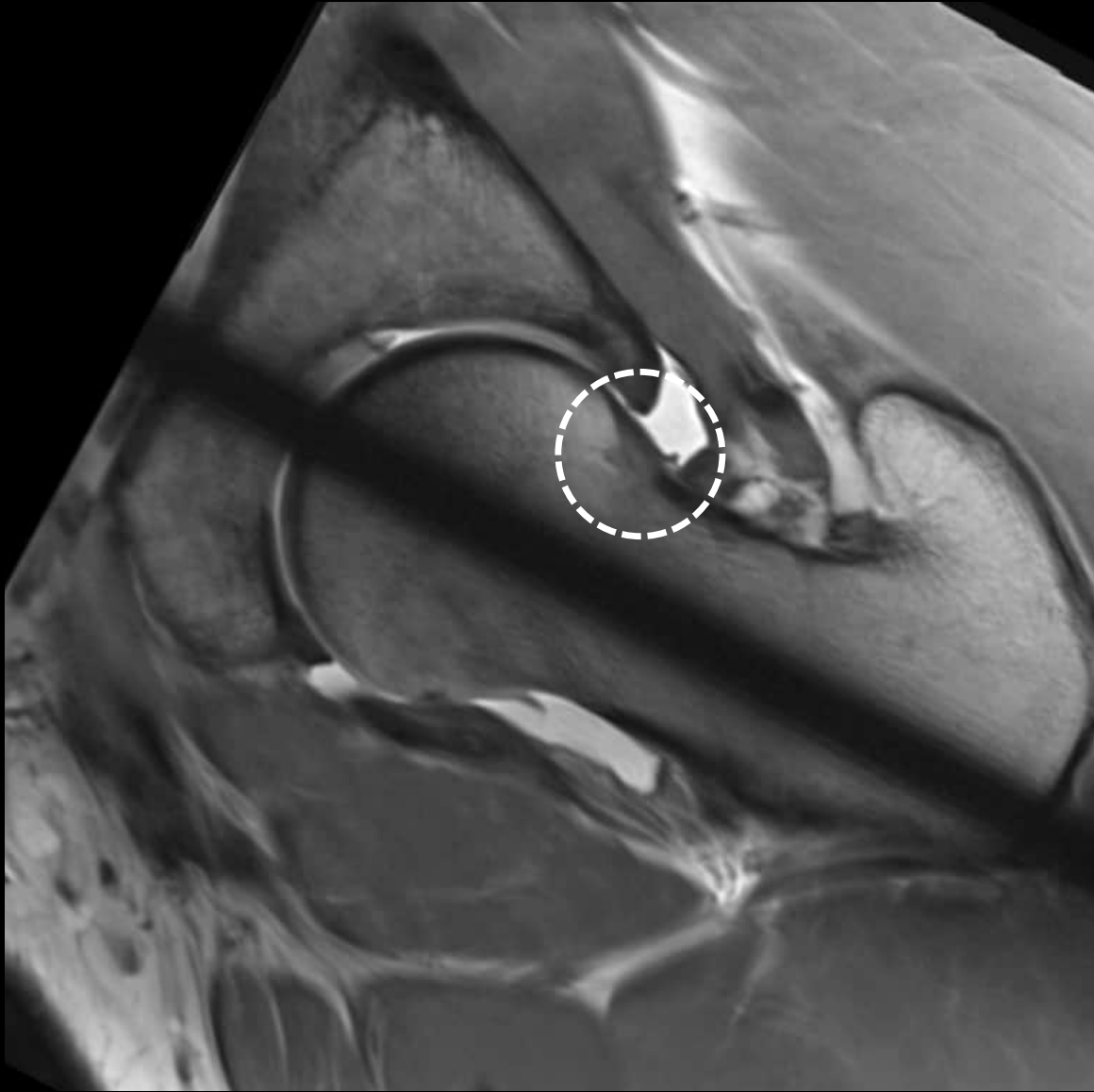
- > Localisation:
 - Anterosuperior
- > Extension:
 - local
- > Relation to the retinacular vessels:
 - Distant

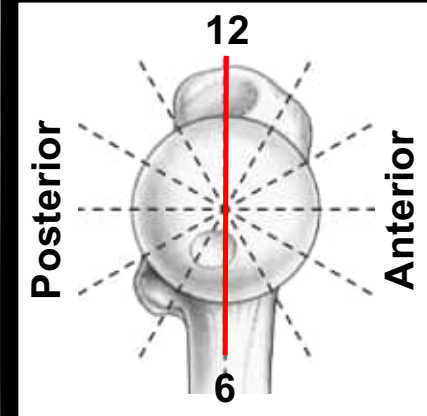
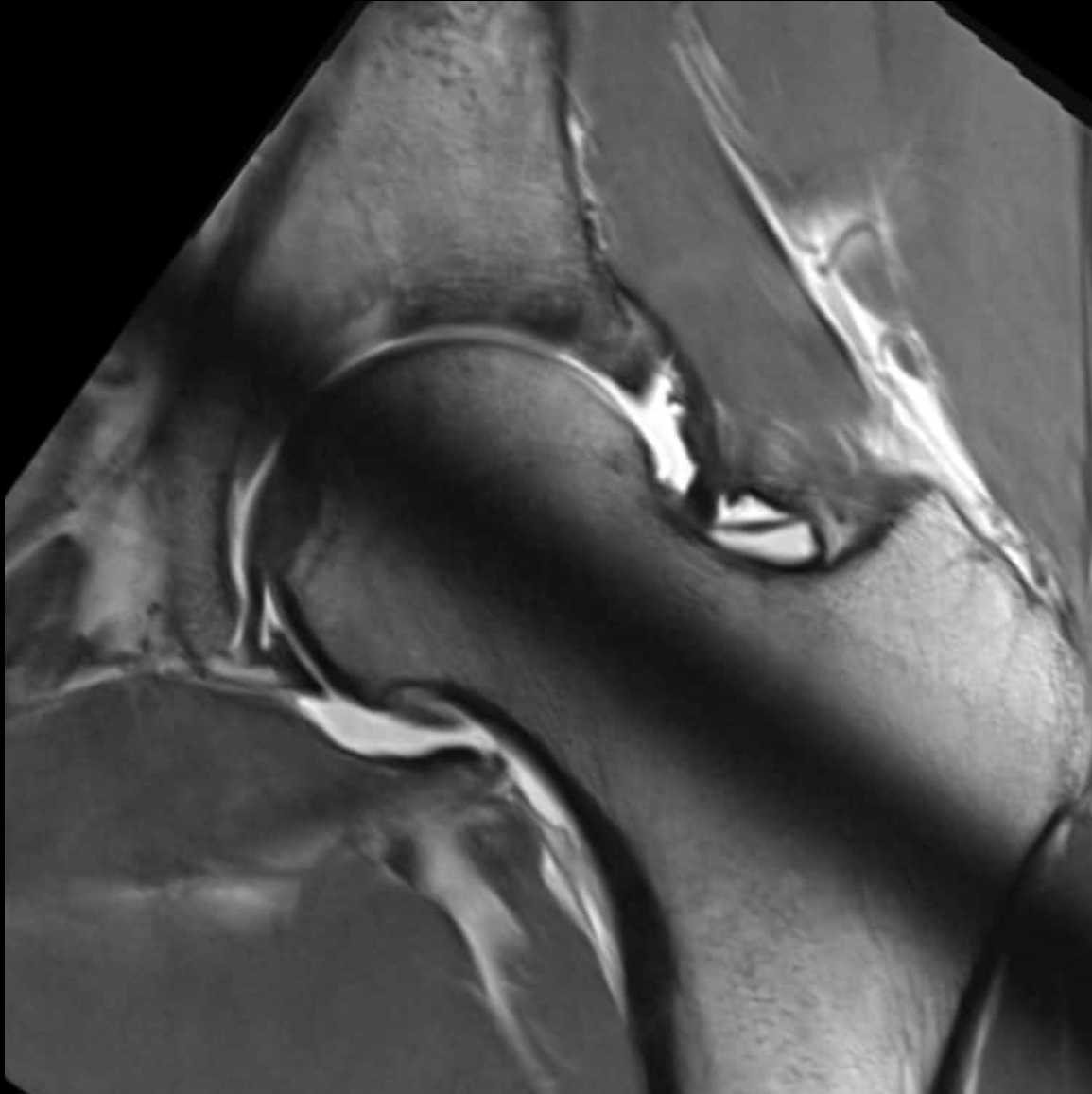


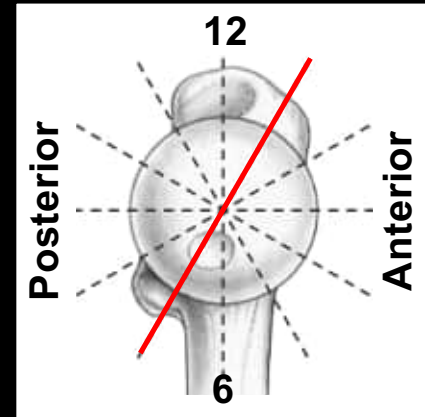
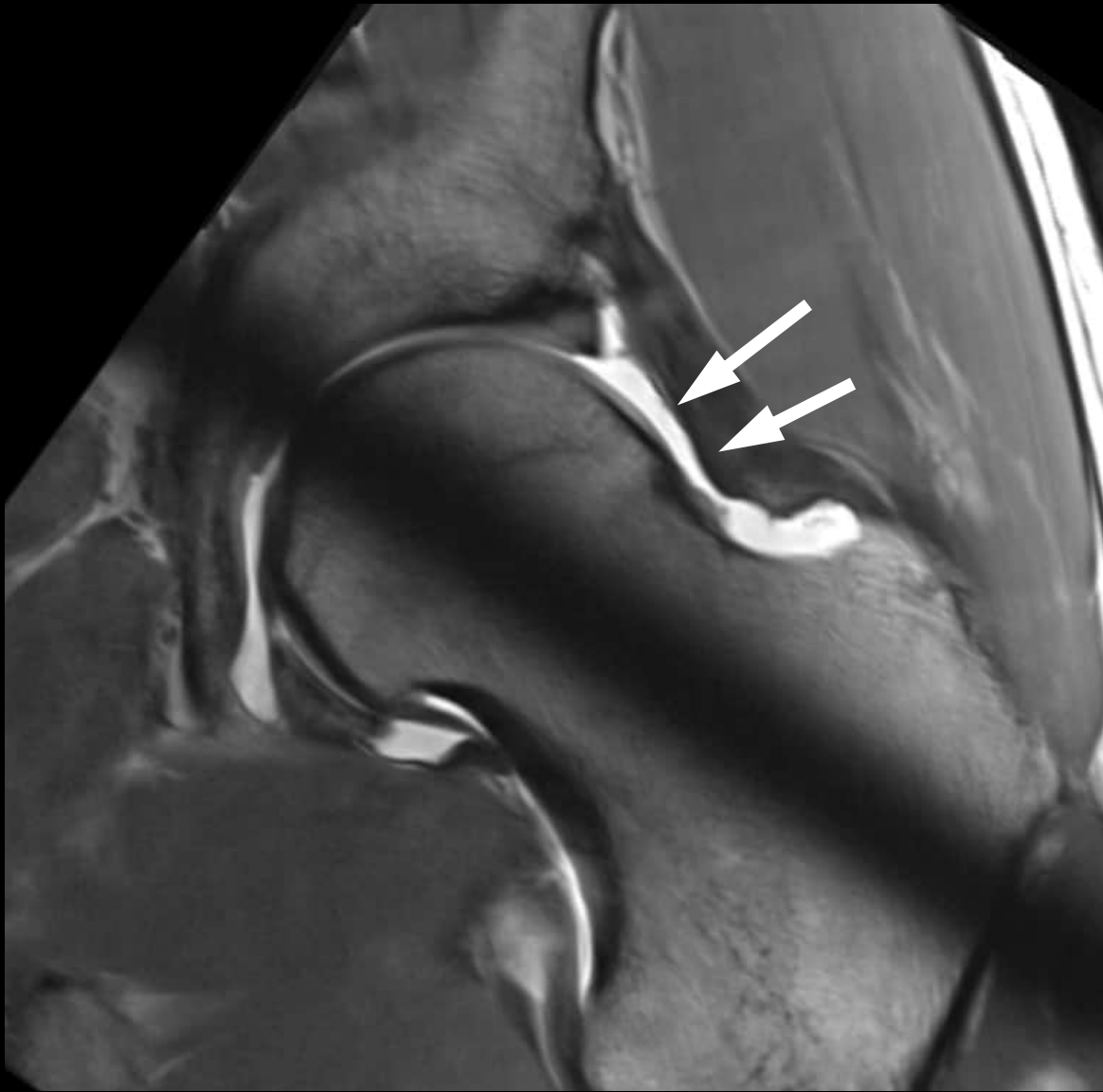
23 year old patient with hip pain

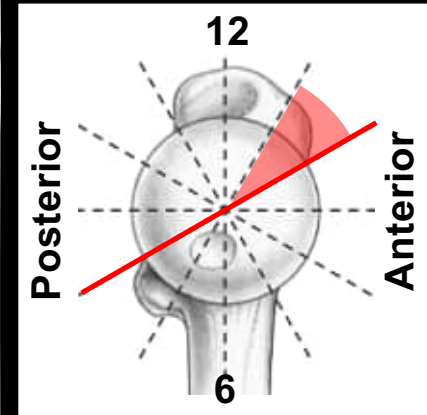
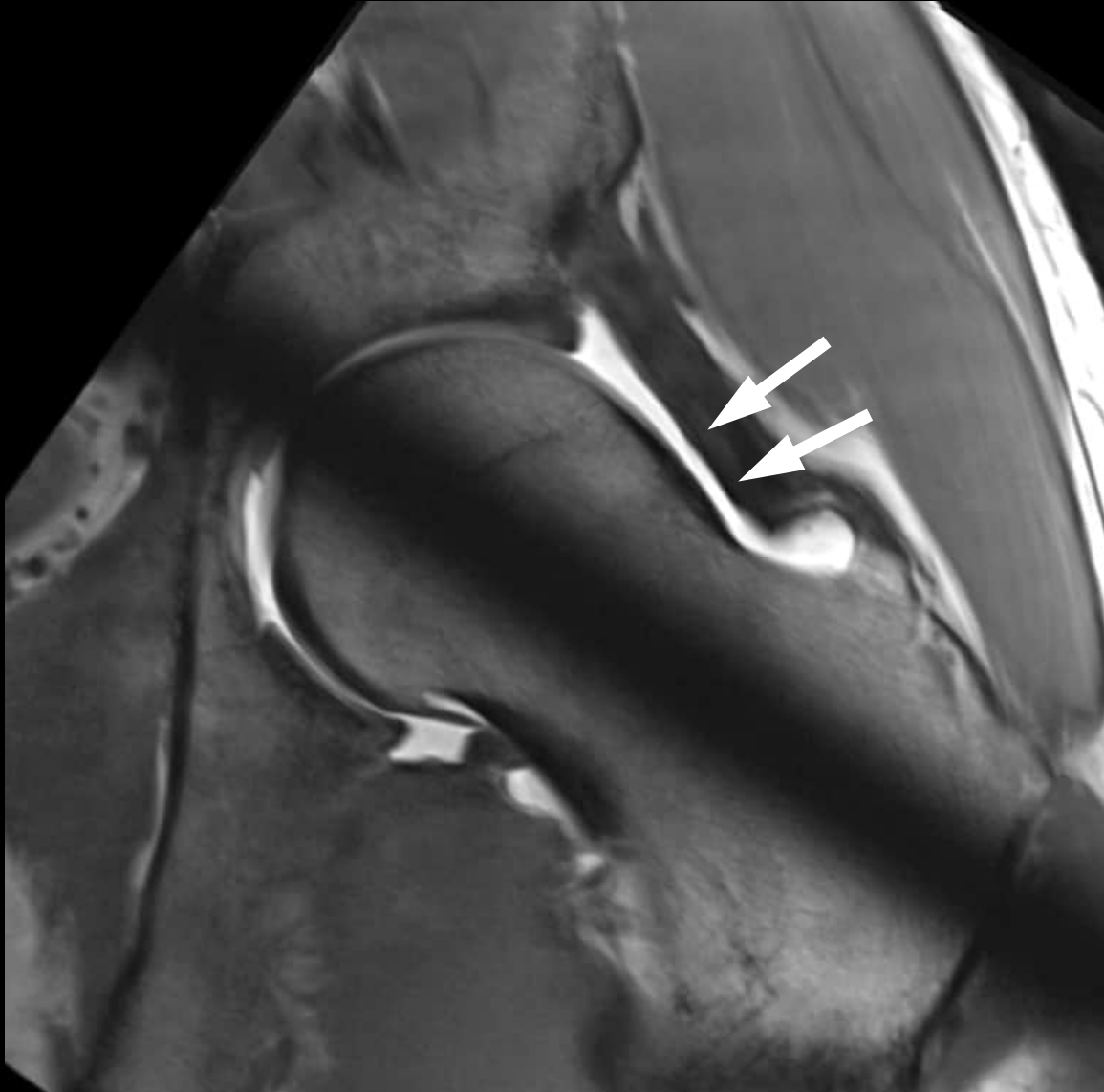


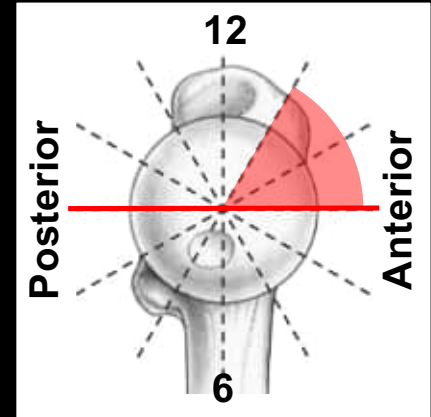
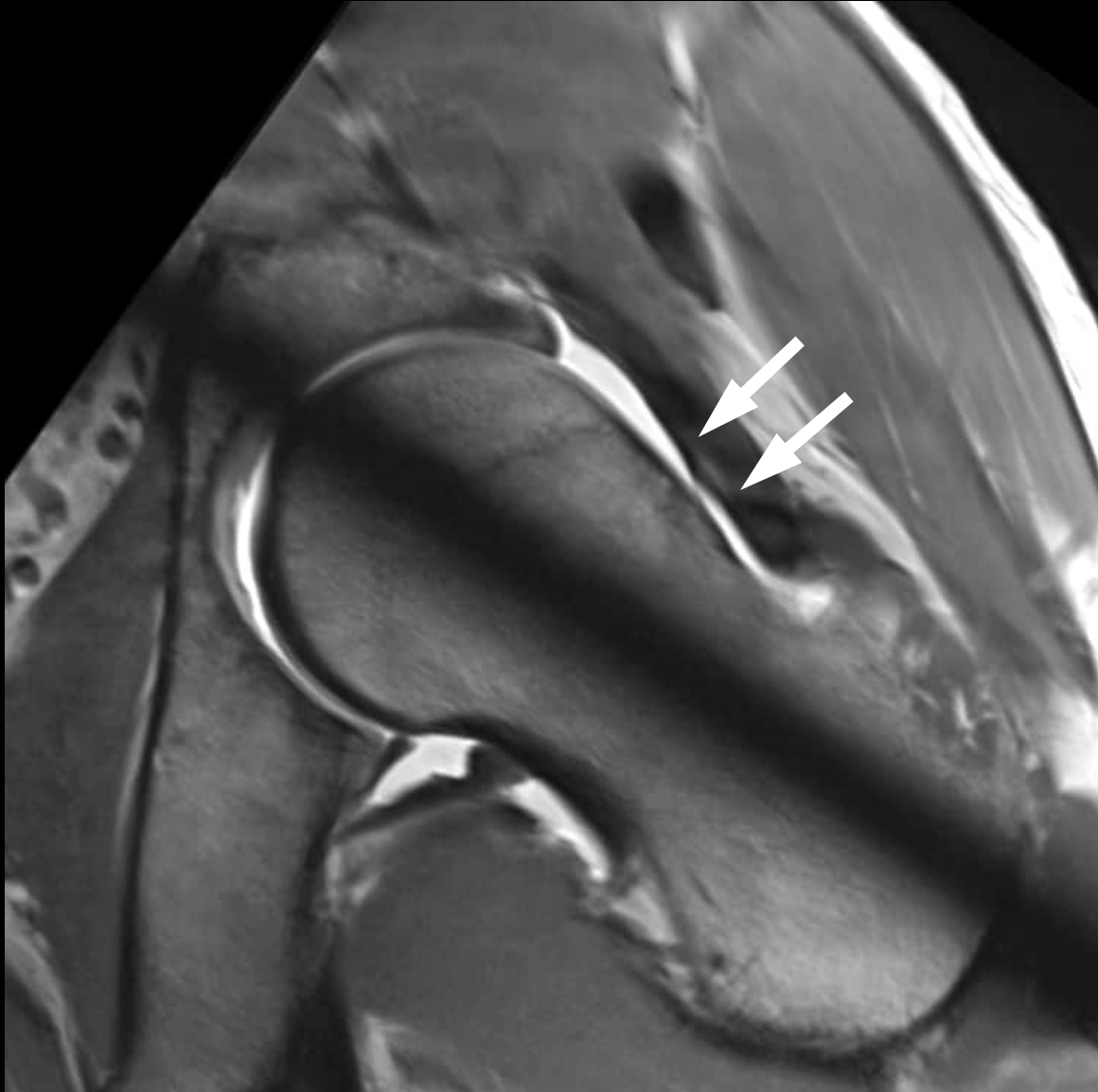
23 year old patient with hip pain

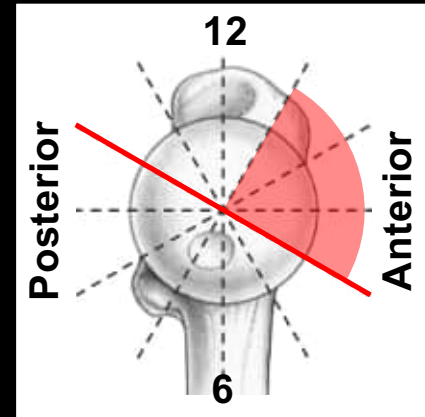
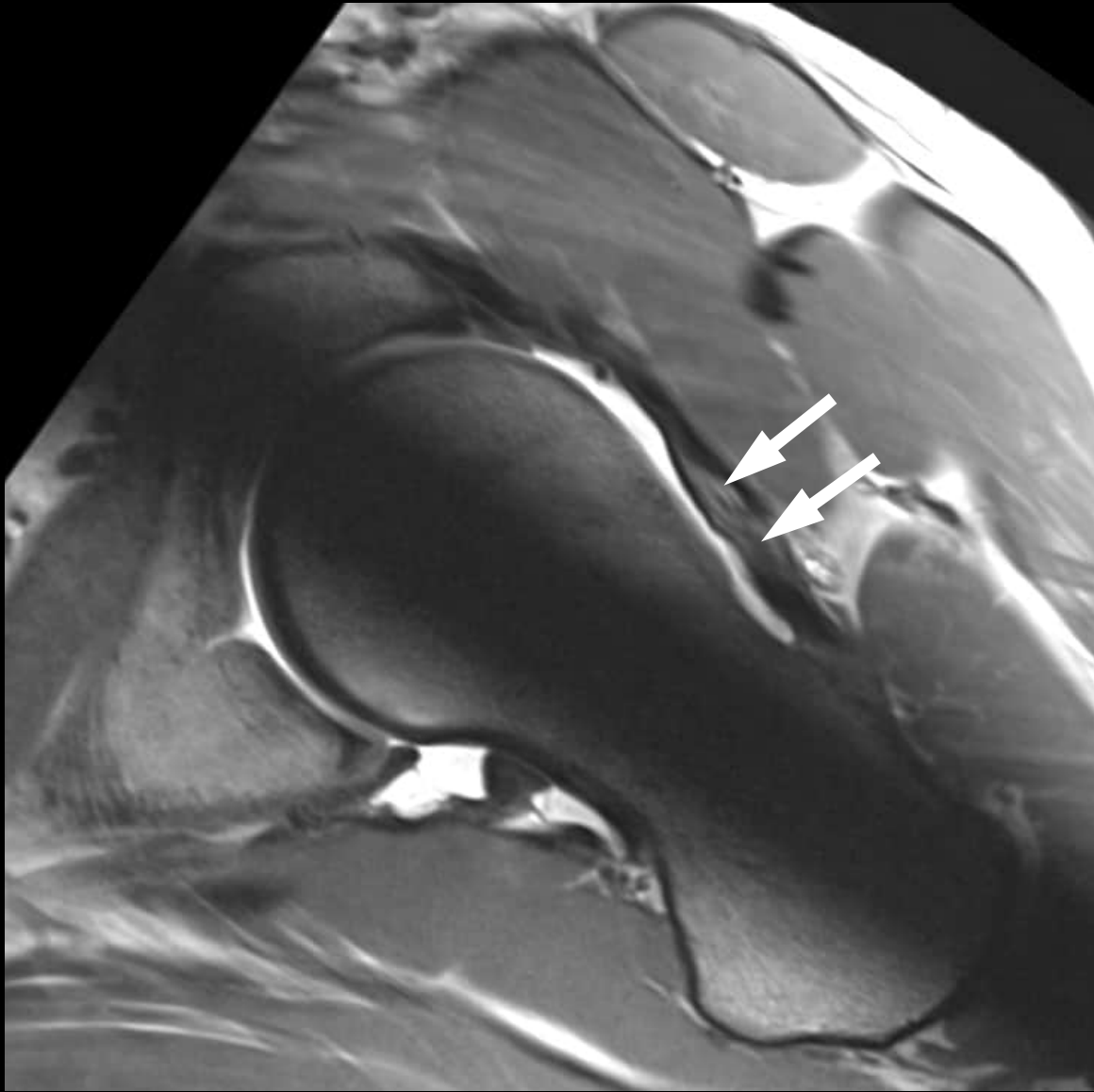


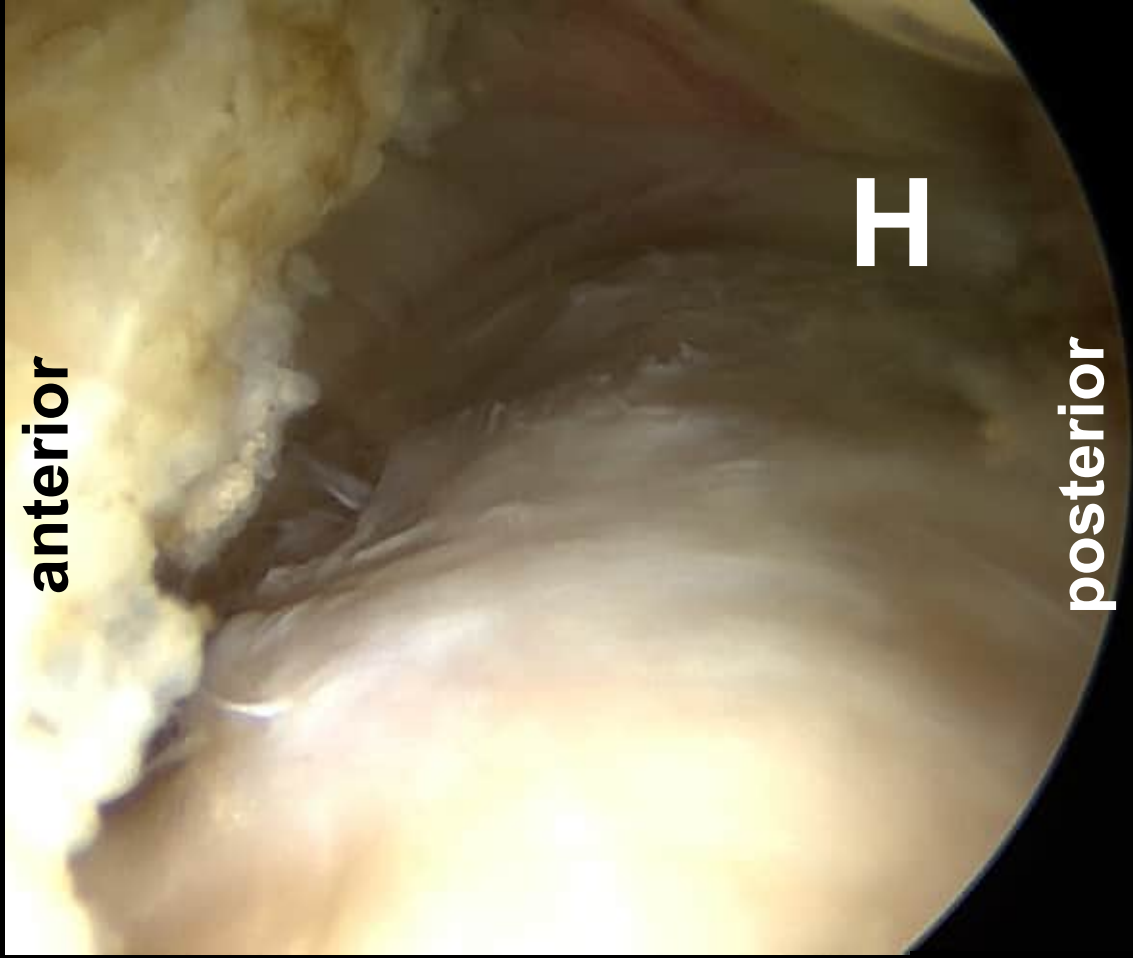
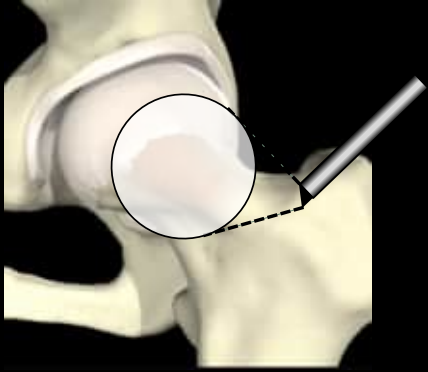


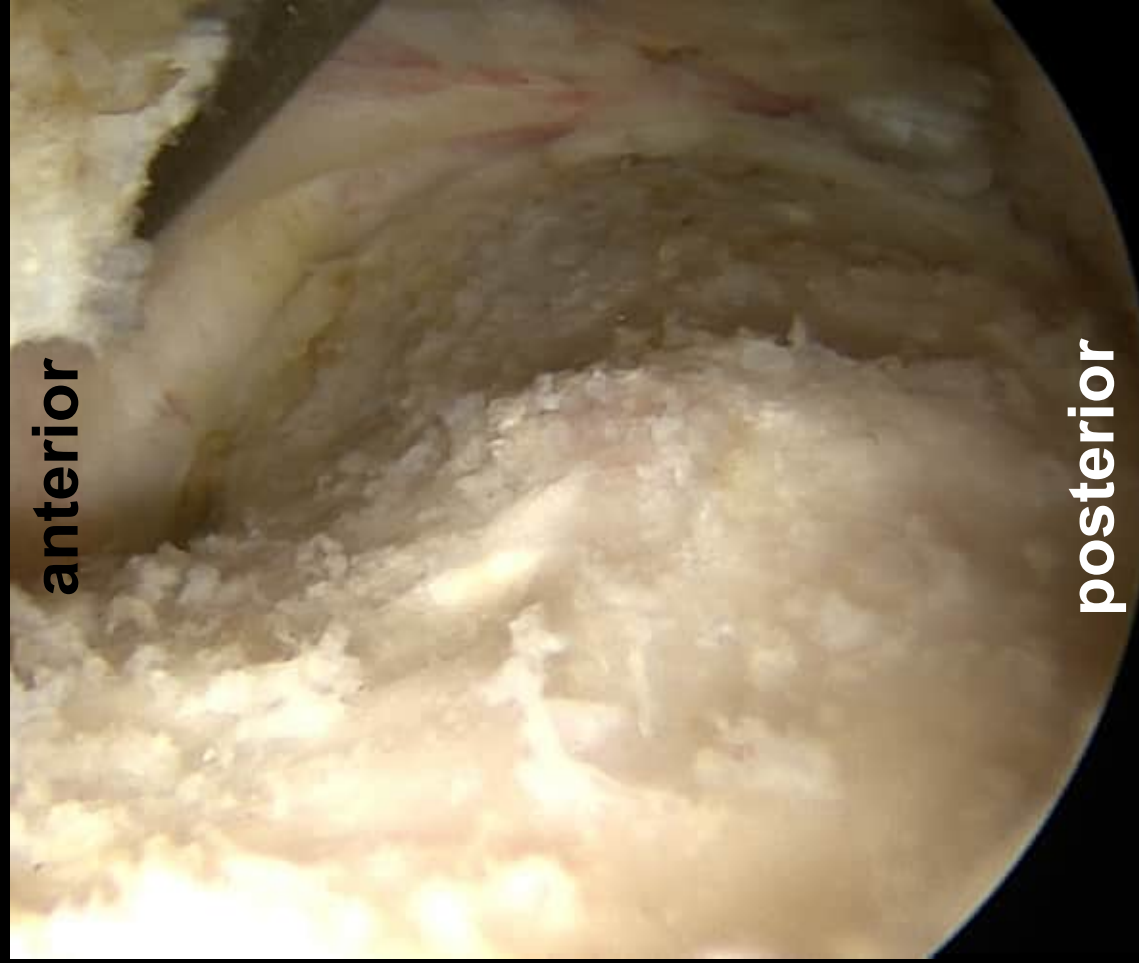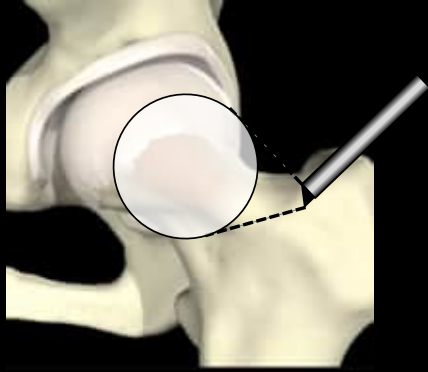


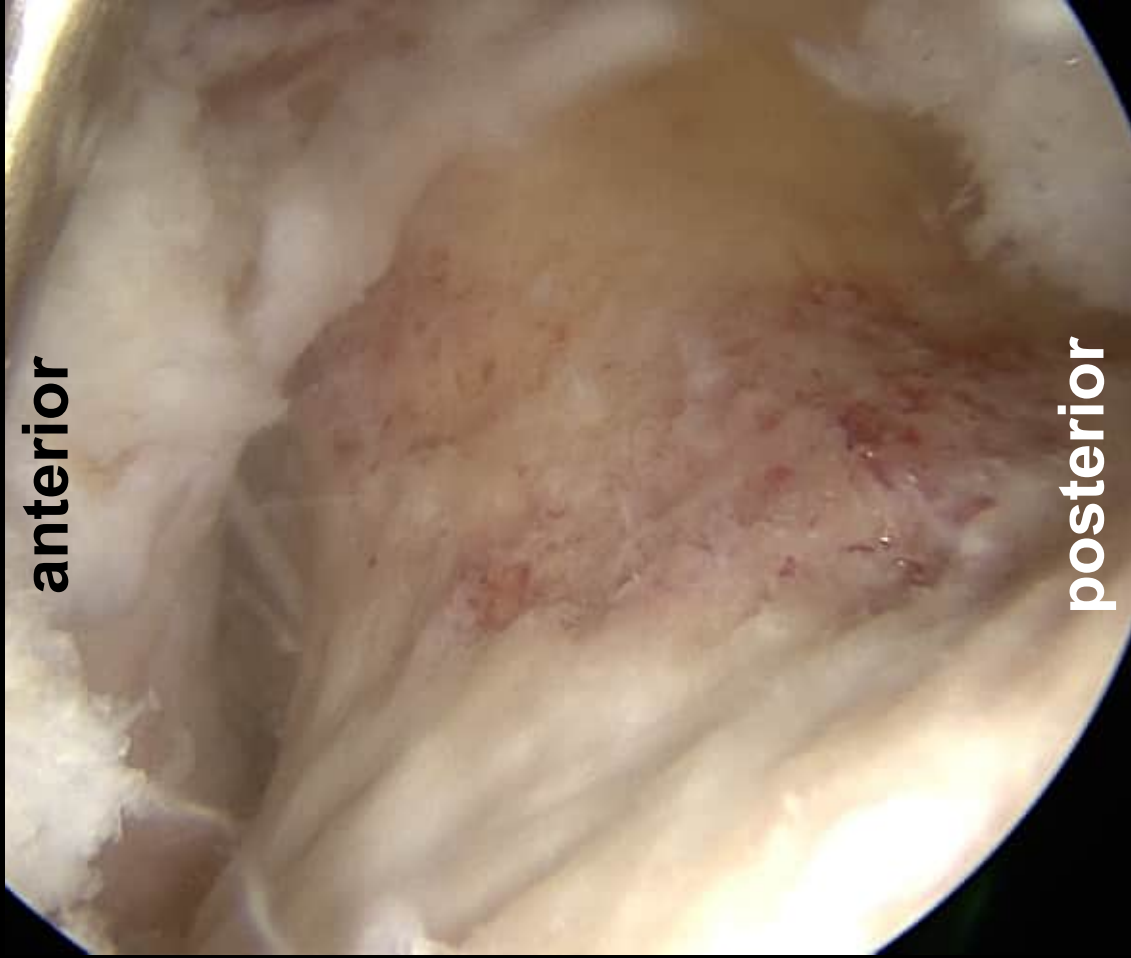
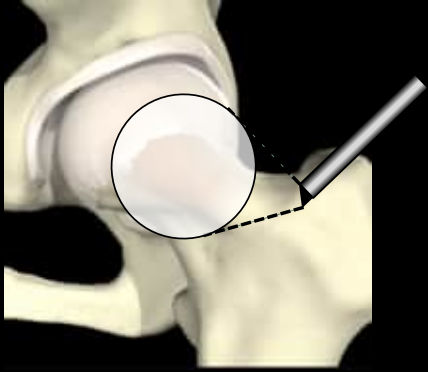





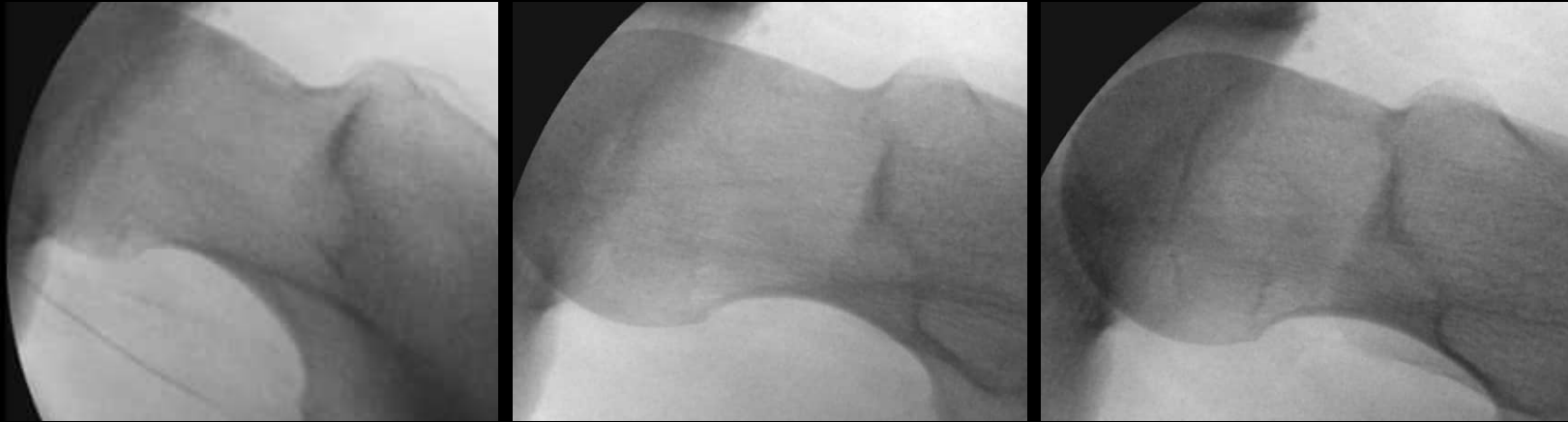




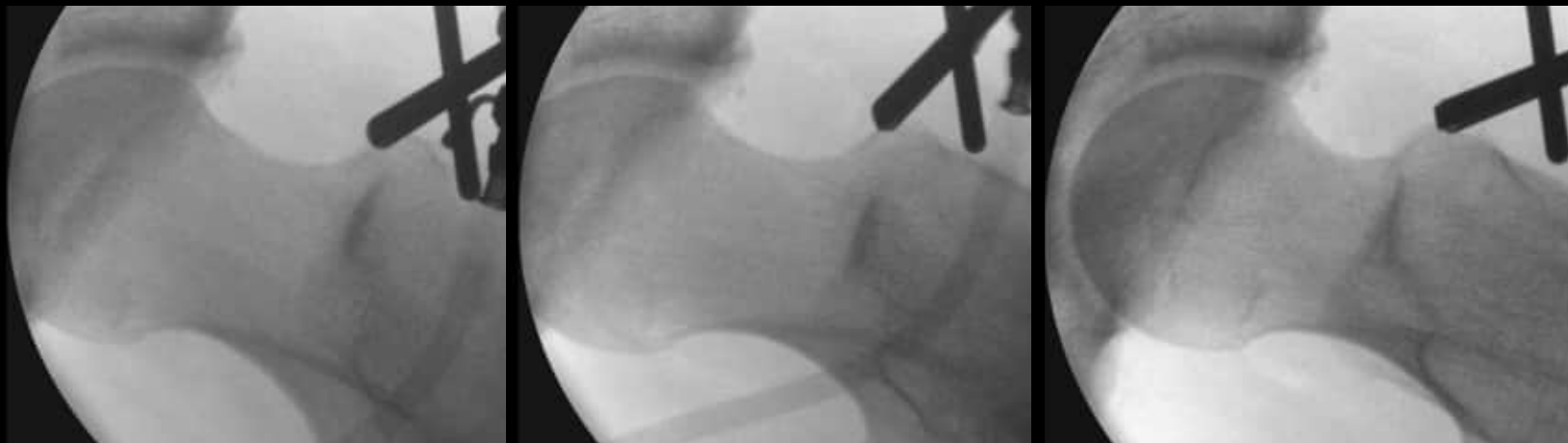

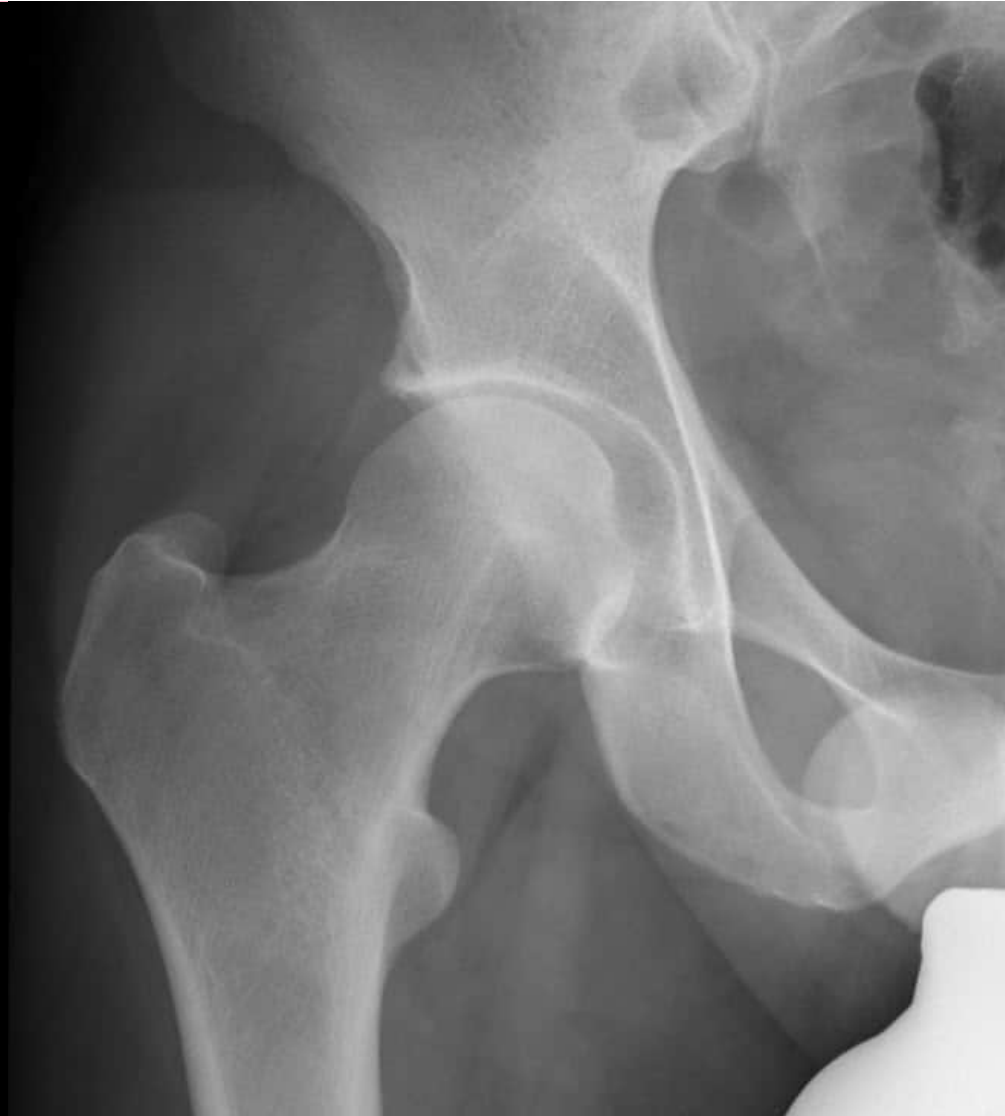Cam Deformity

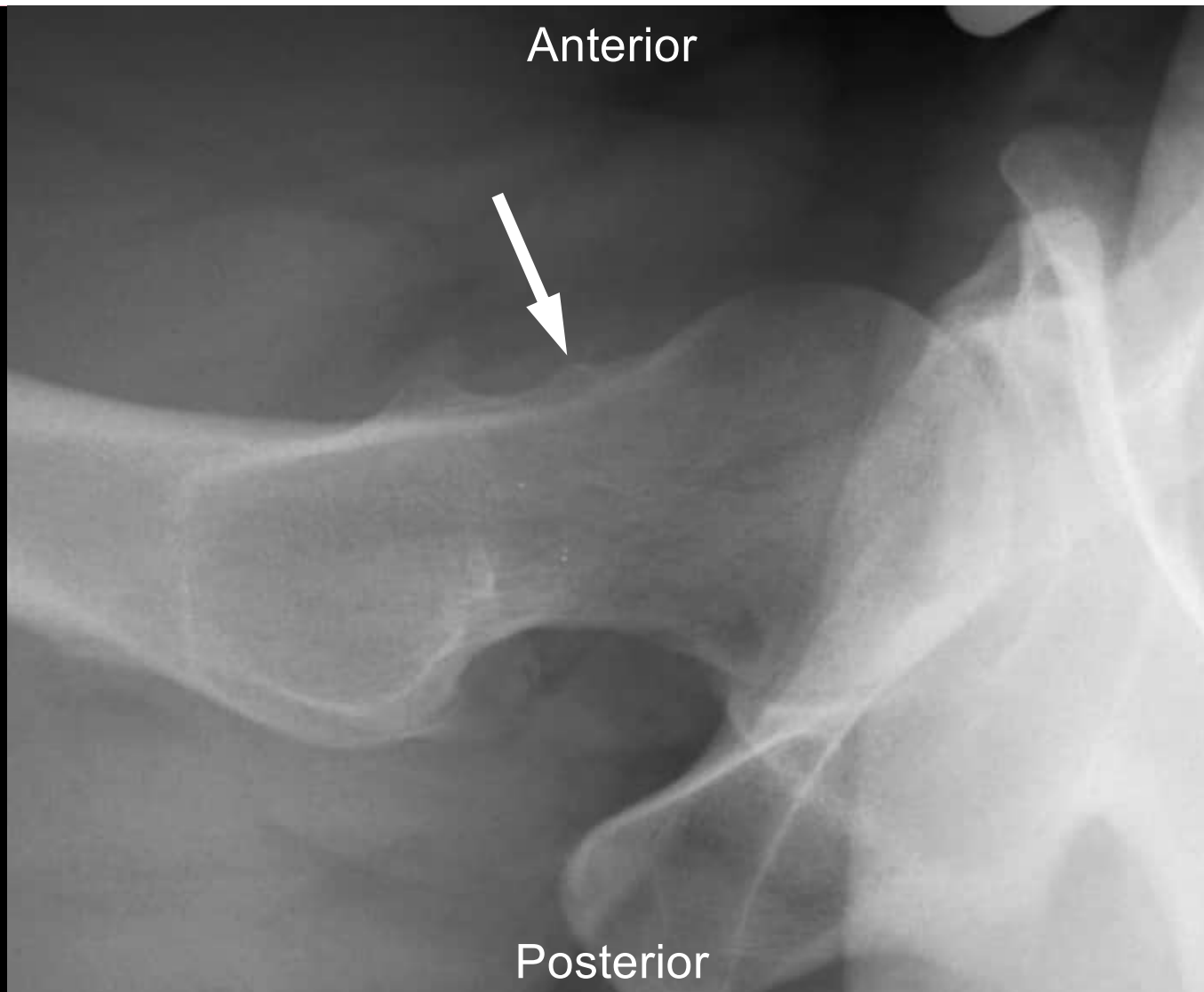


After Offset Improvement

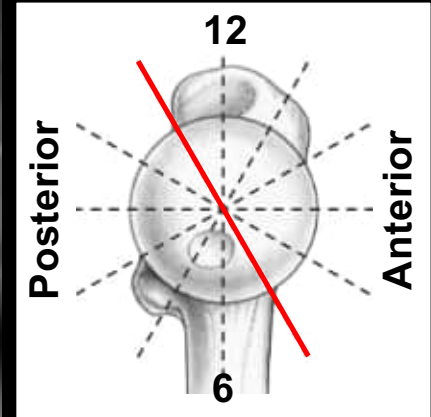
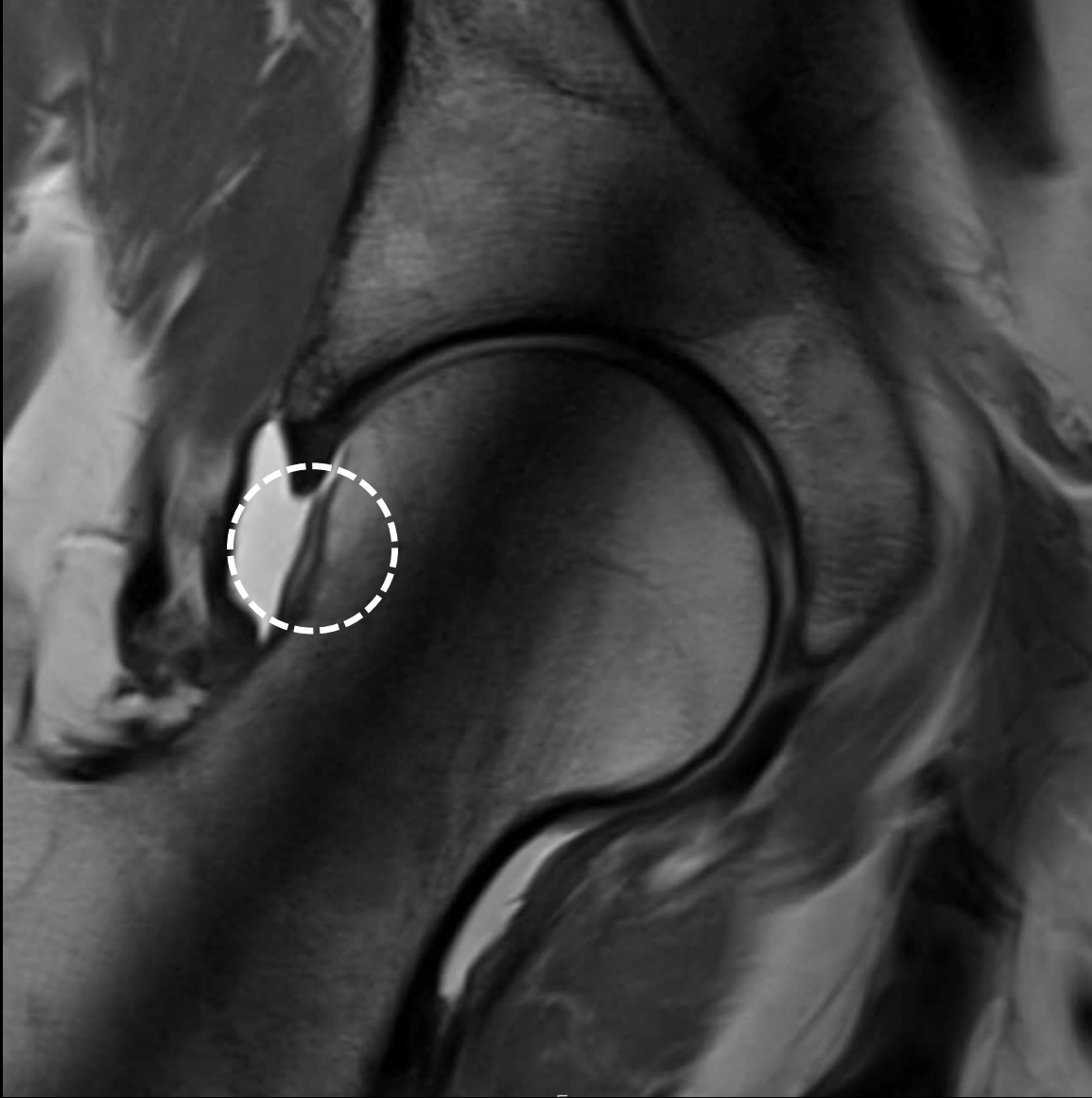

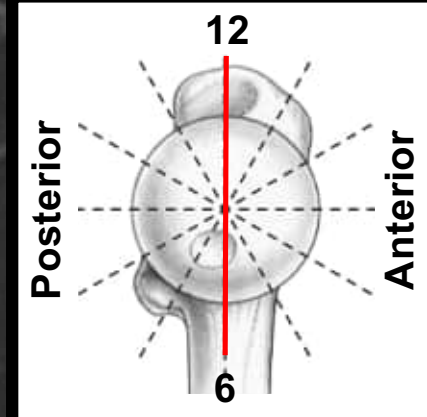
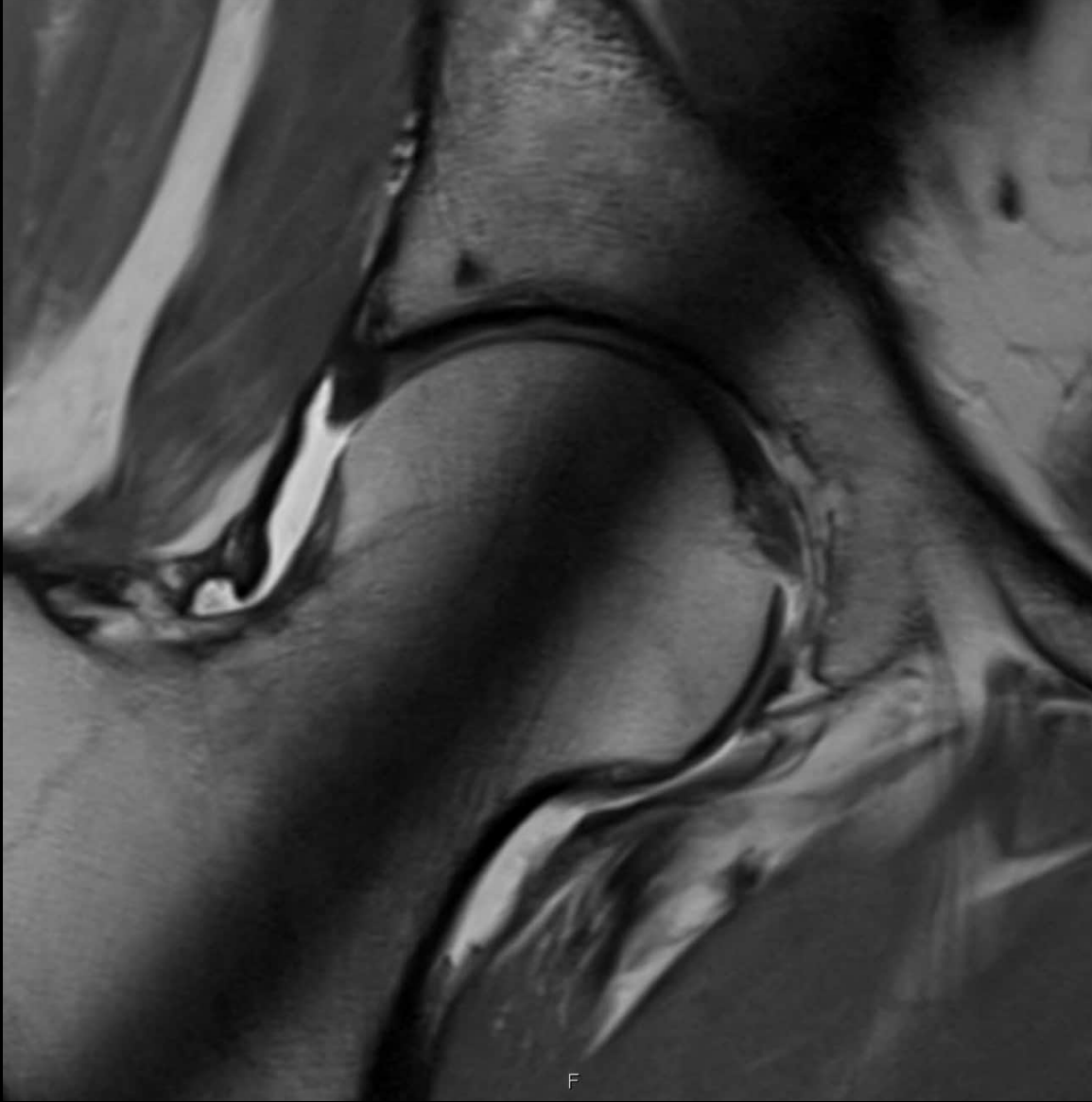


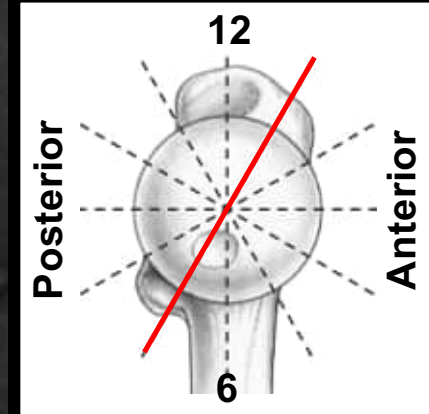
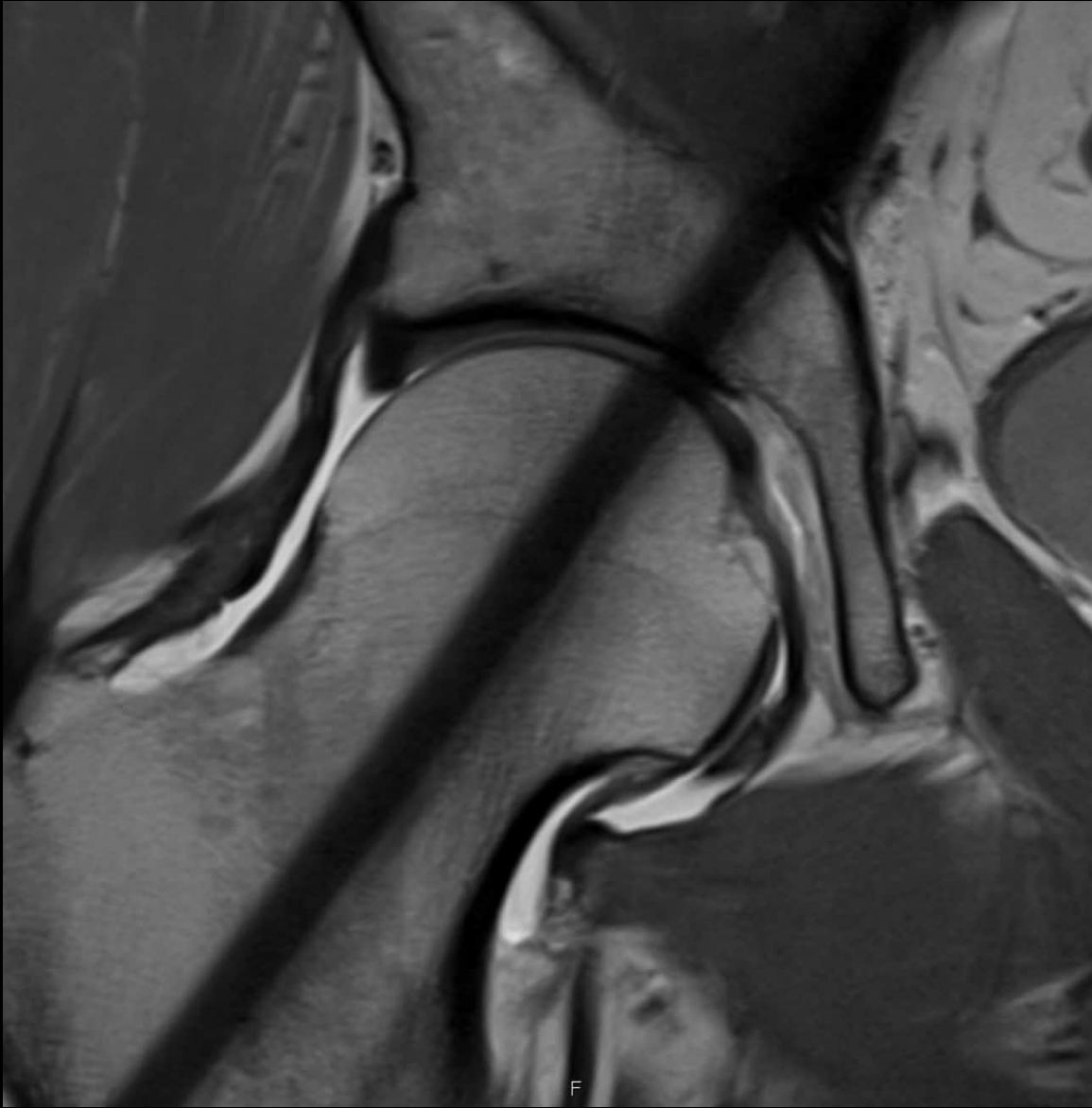
32 year old patient with hip pain

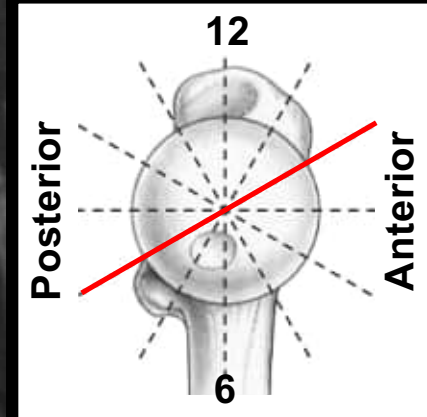
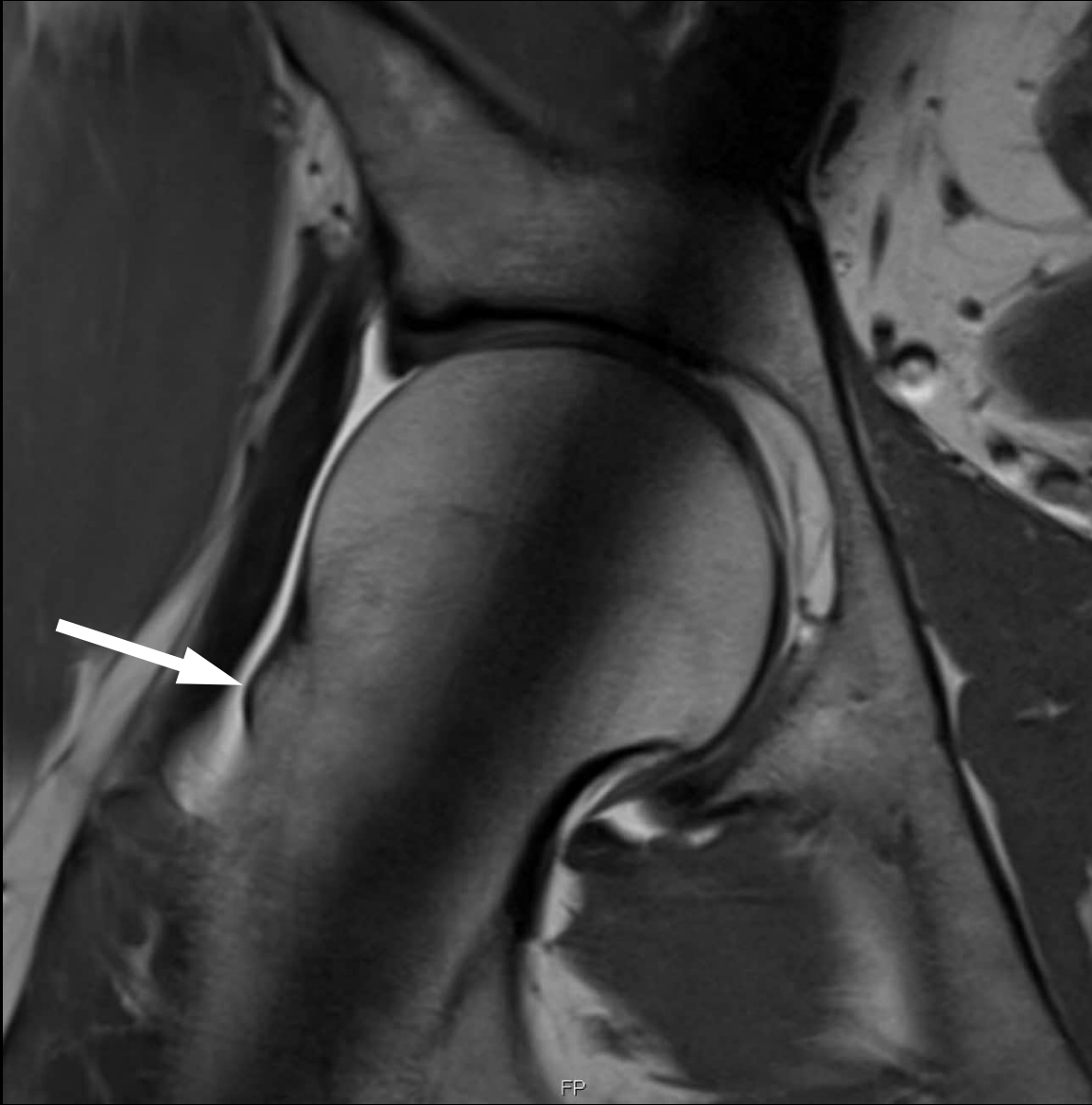


32 year old patient with hip pain

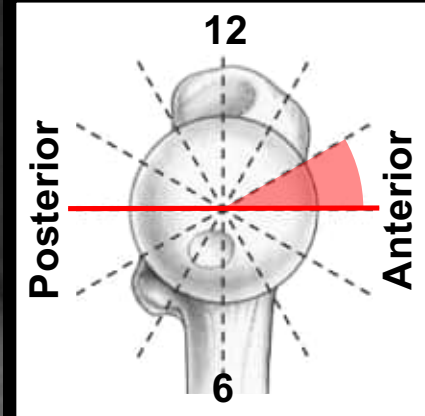
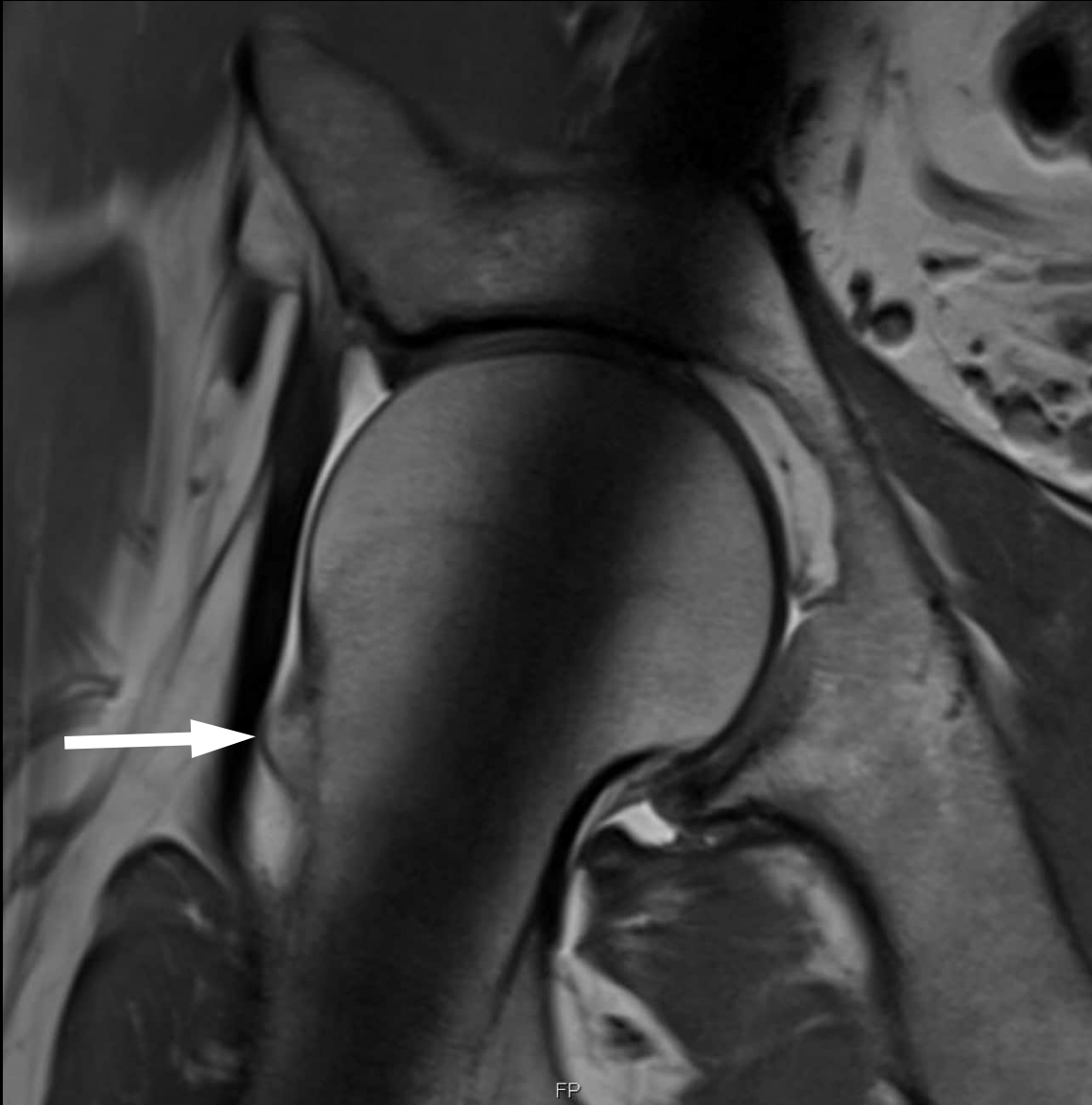


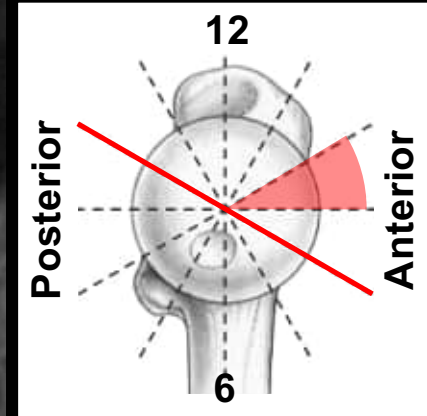
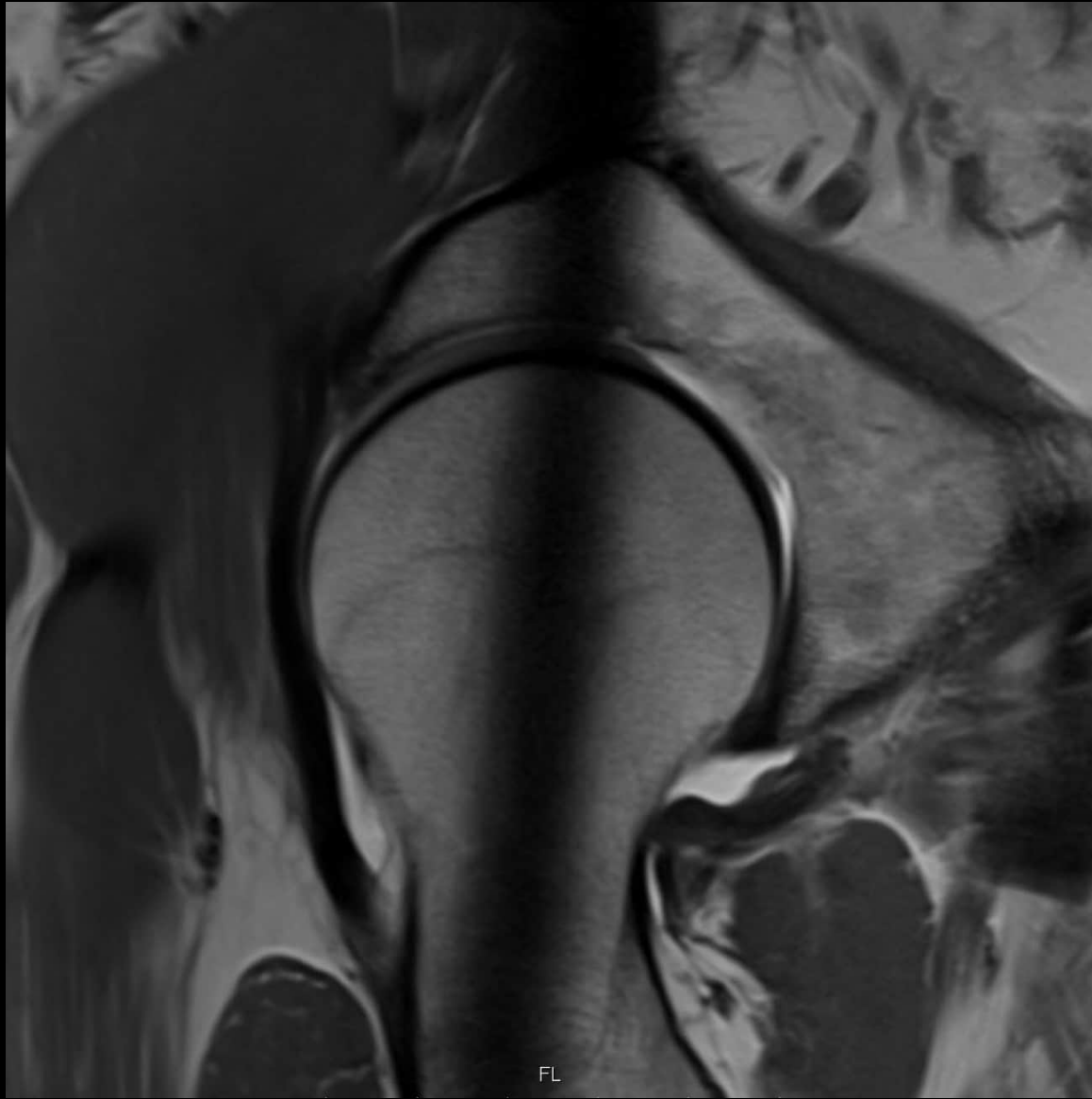



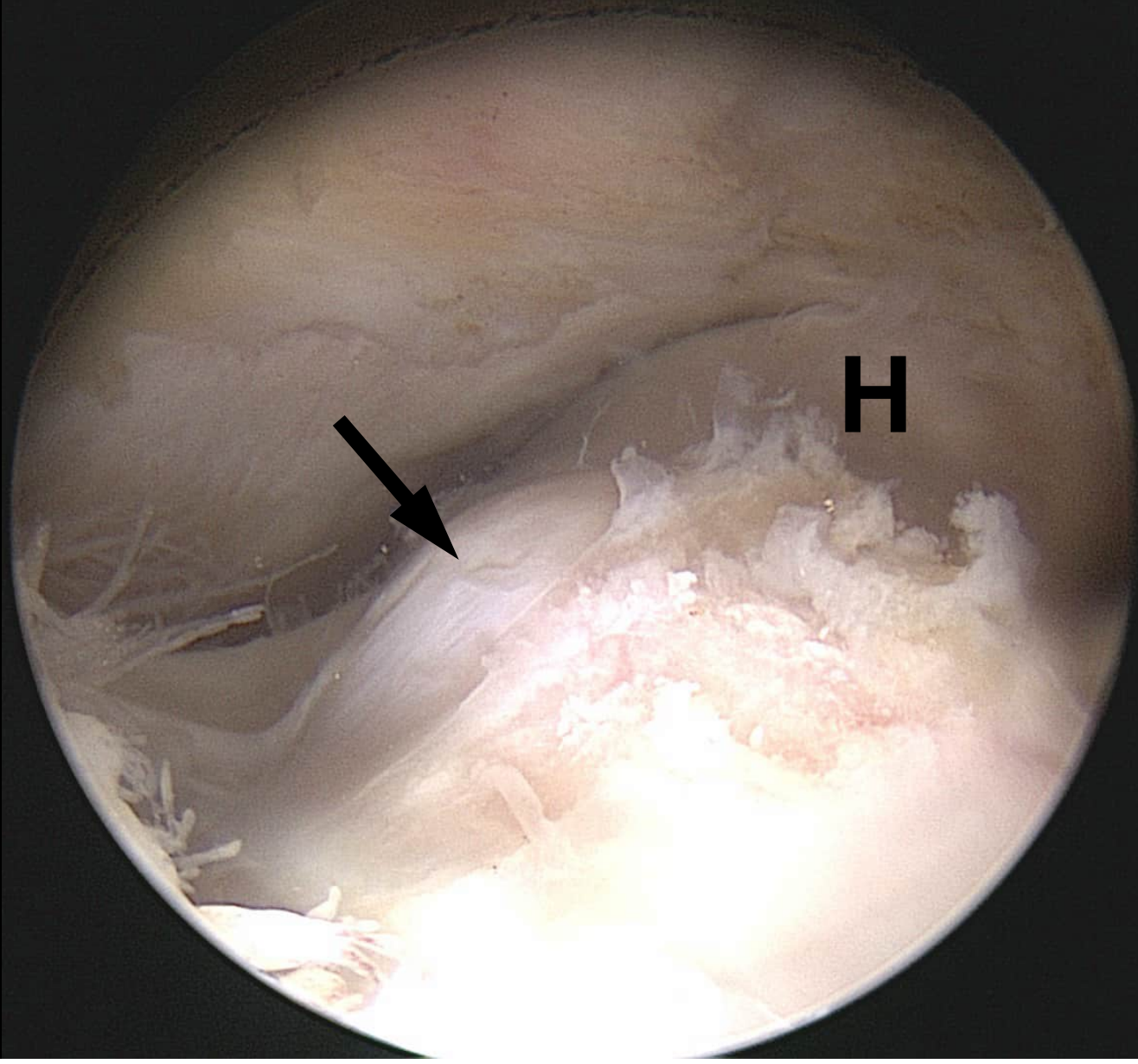


FP



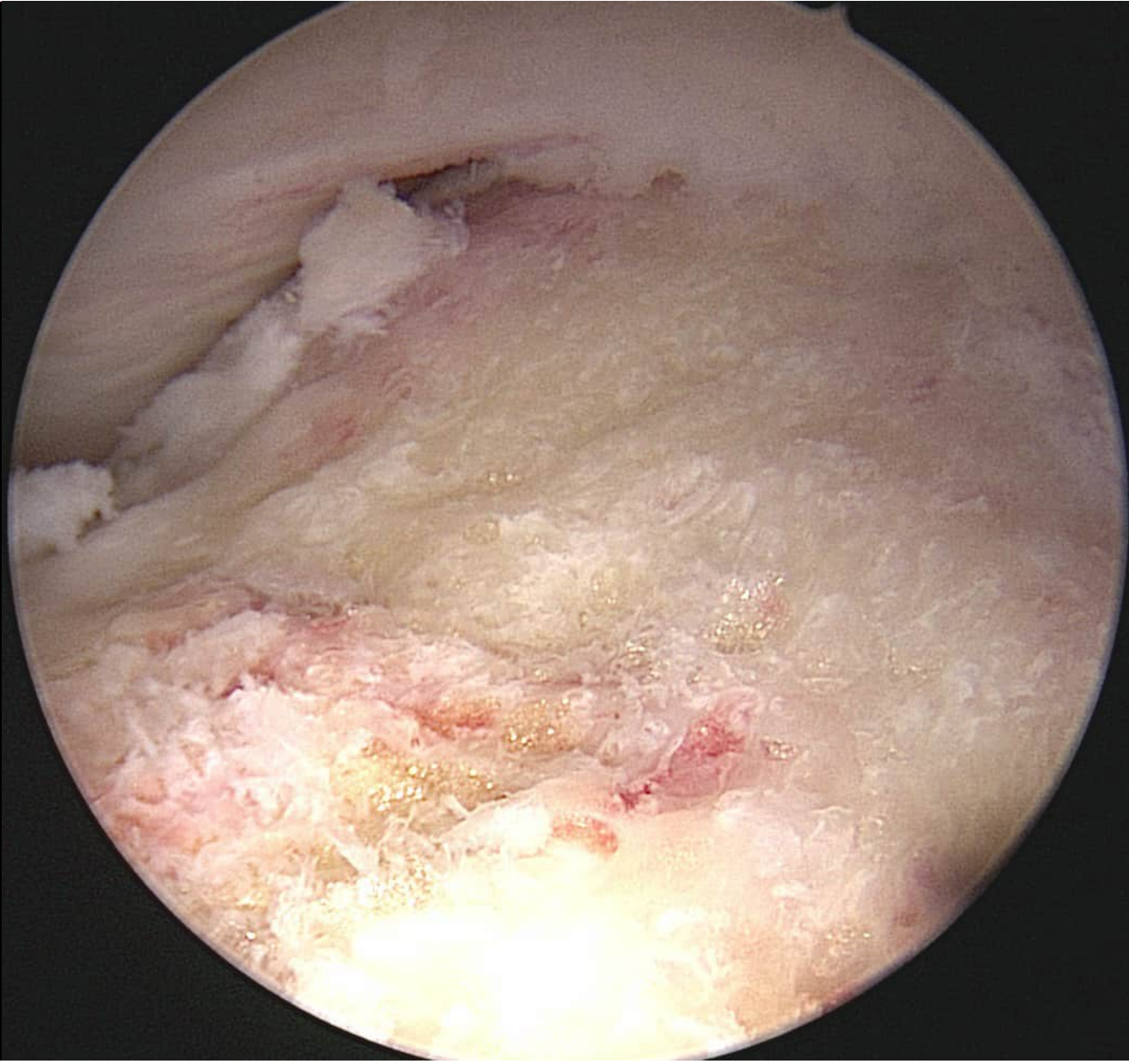


anterior



posterior

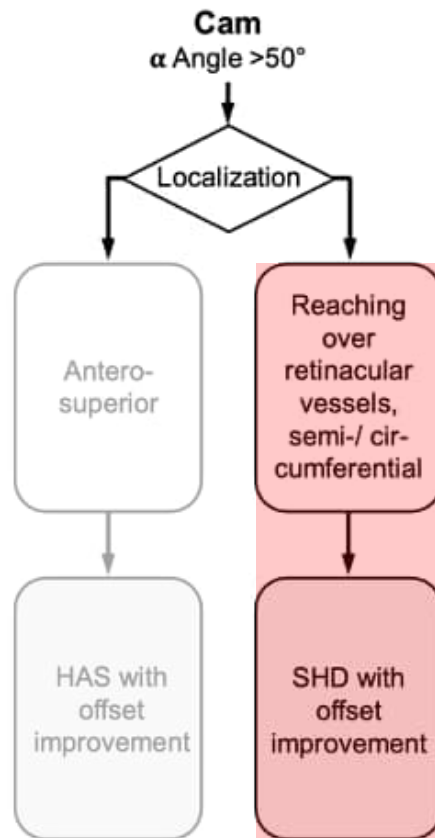
anterior



posterior

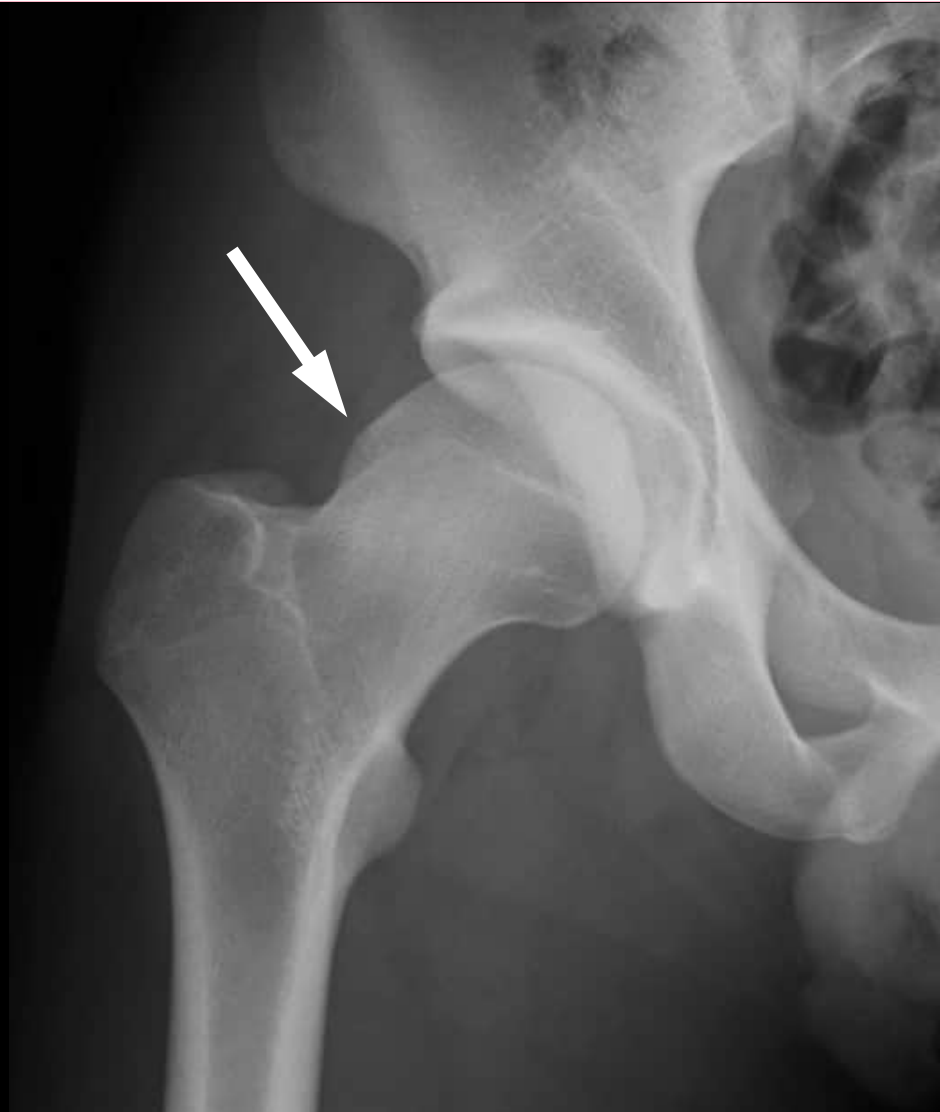u^b

Treatment Concept Cam Deformity

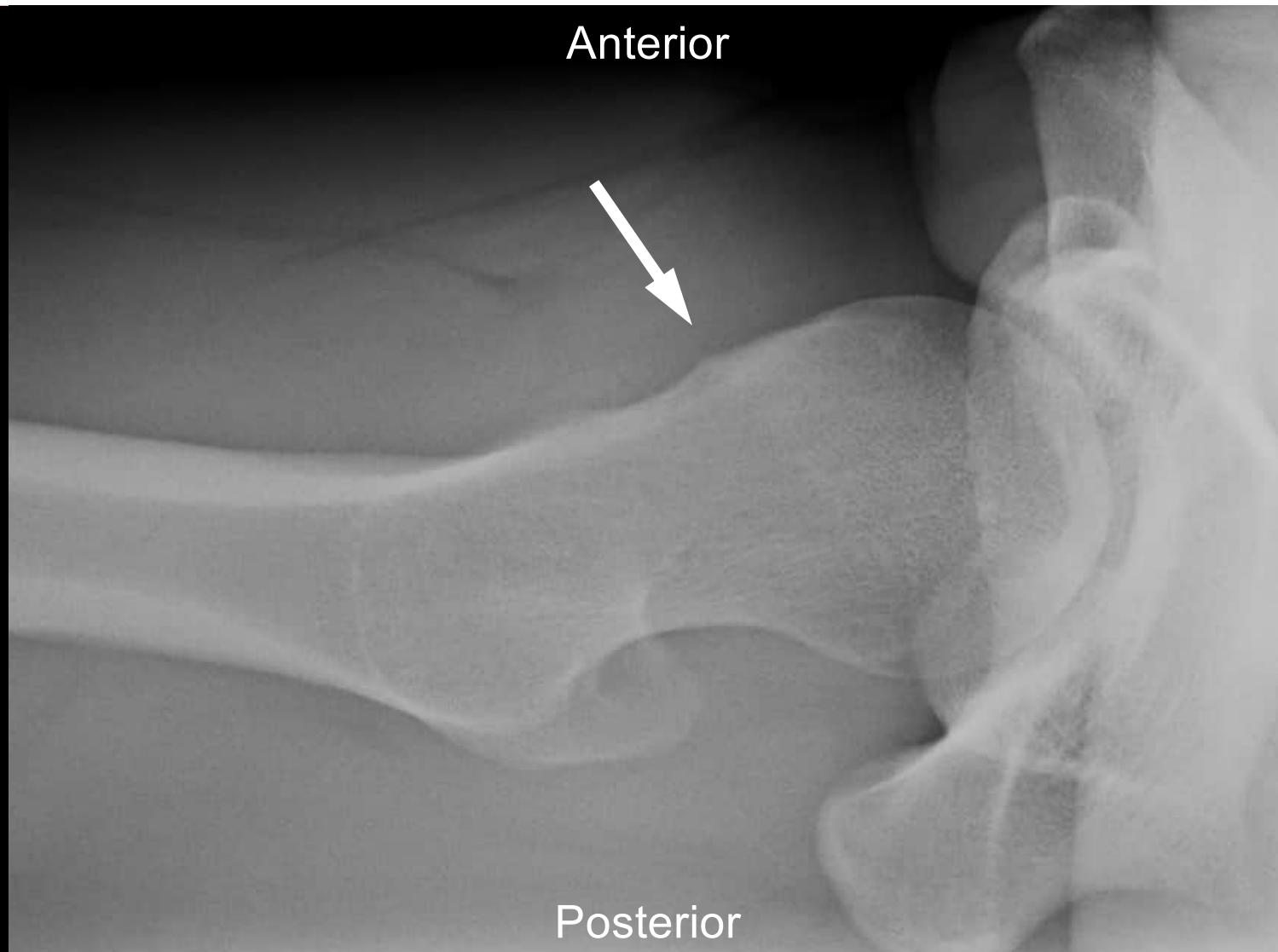

Surgical hip dislocation

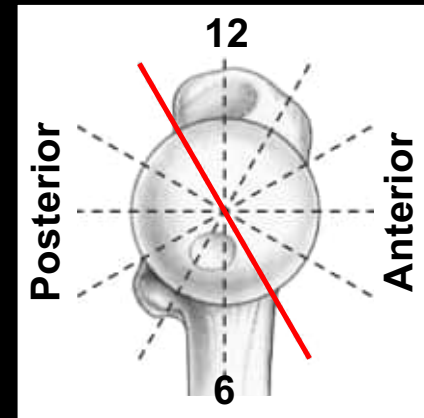
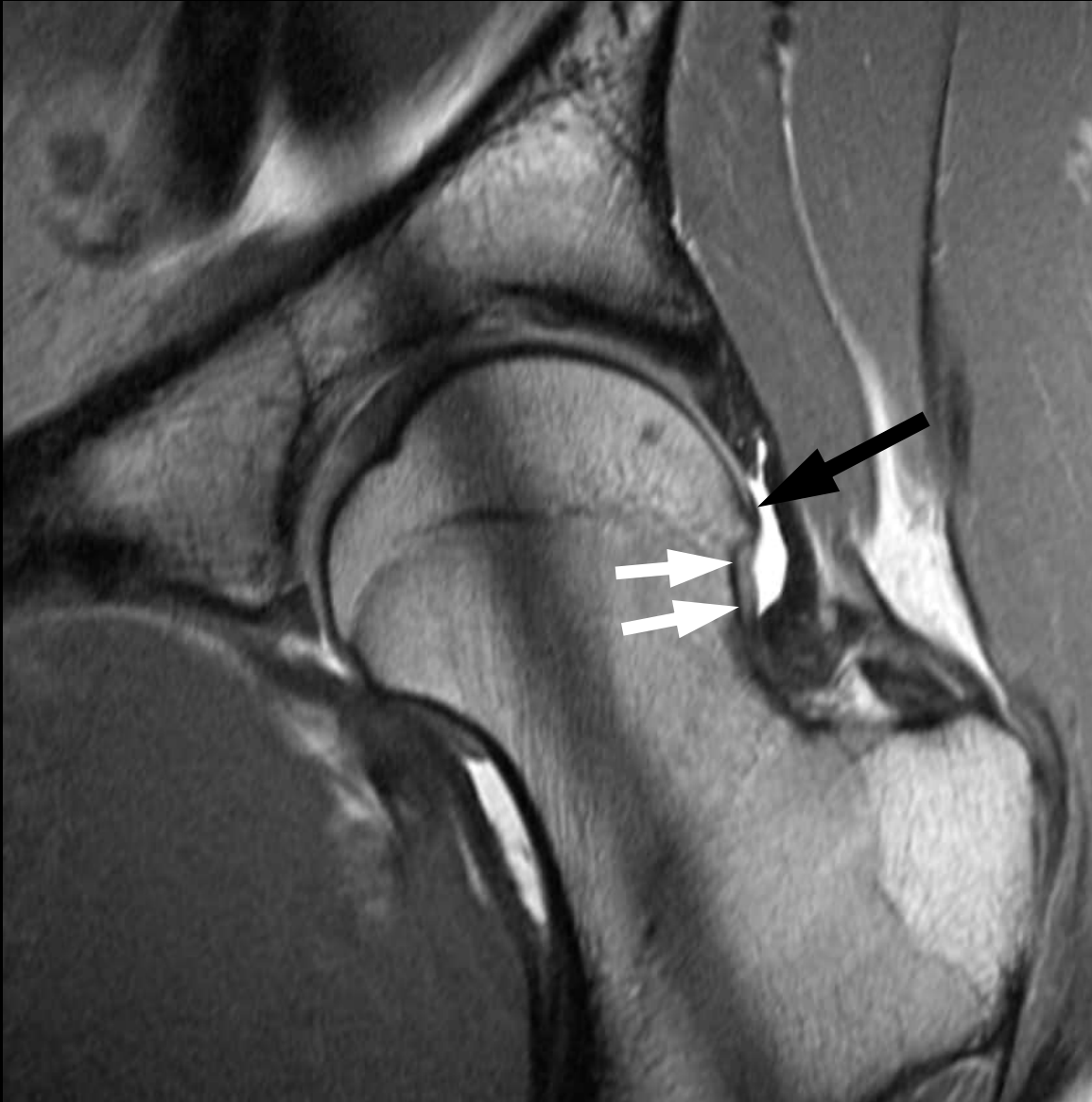- > Localisation:
 - Posterior
- > Extension:
 - Semi / circumferential
- > Relation to the retinacular vessels:
 - Close

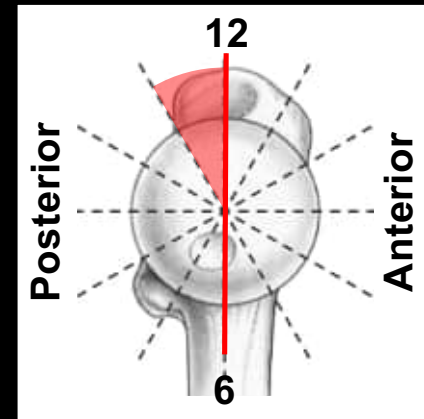
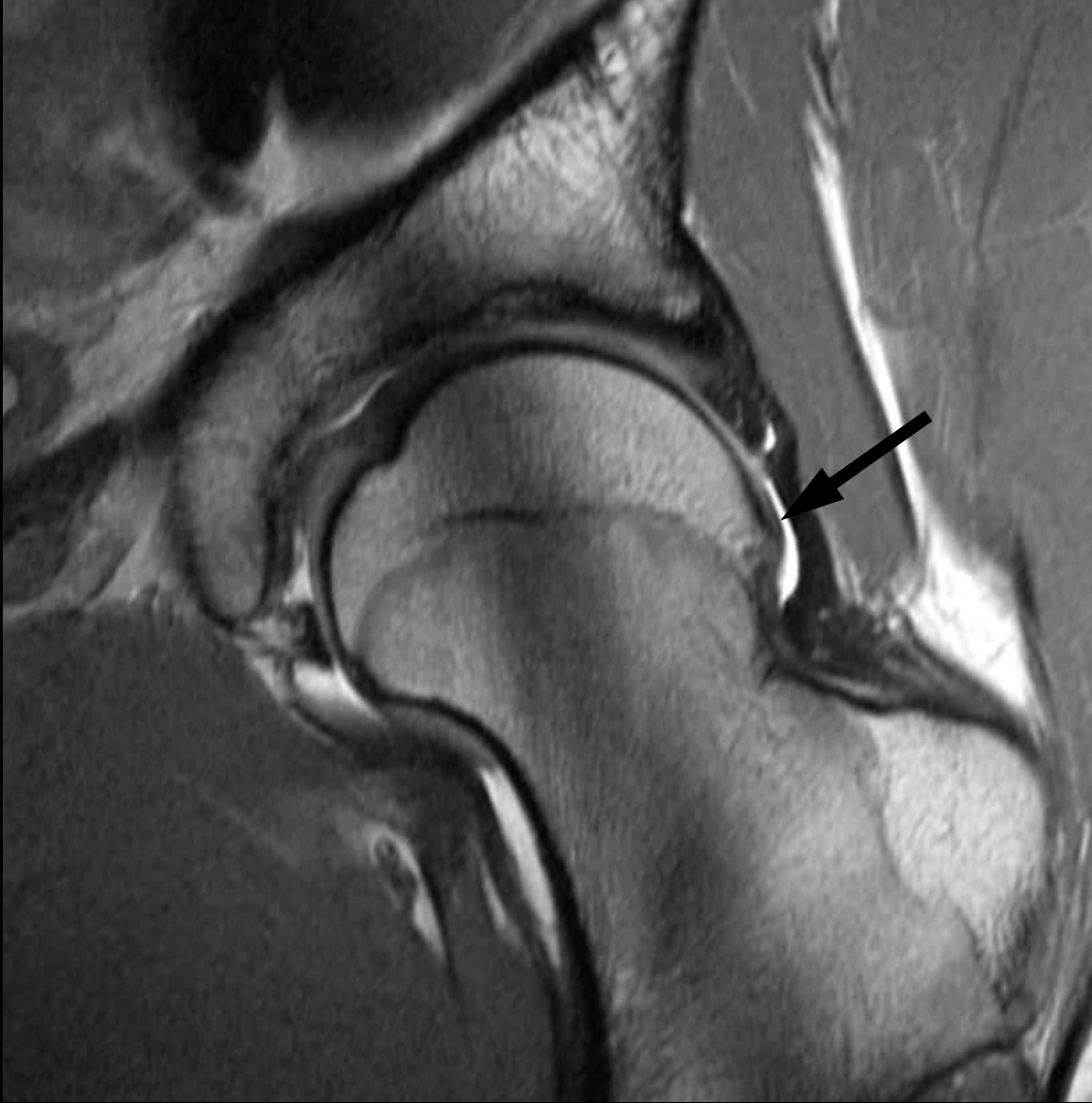

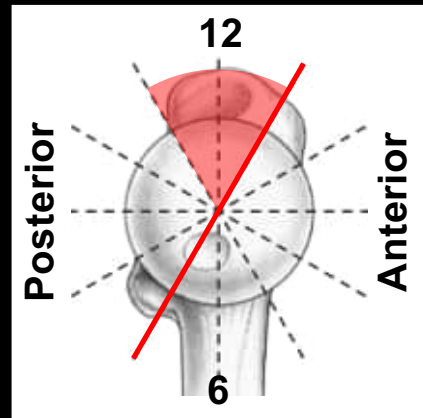
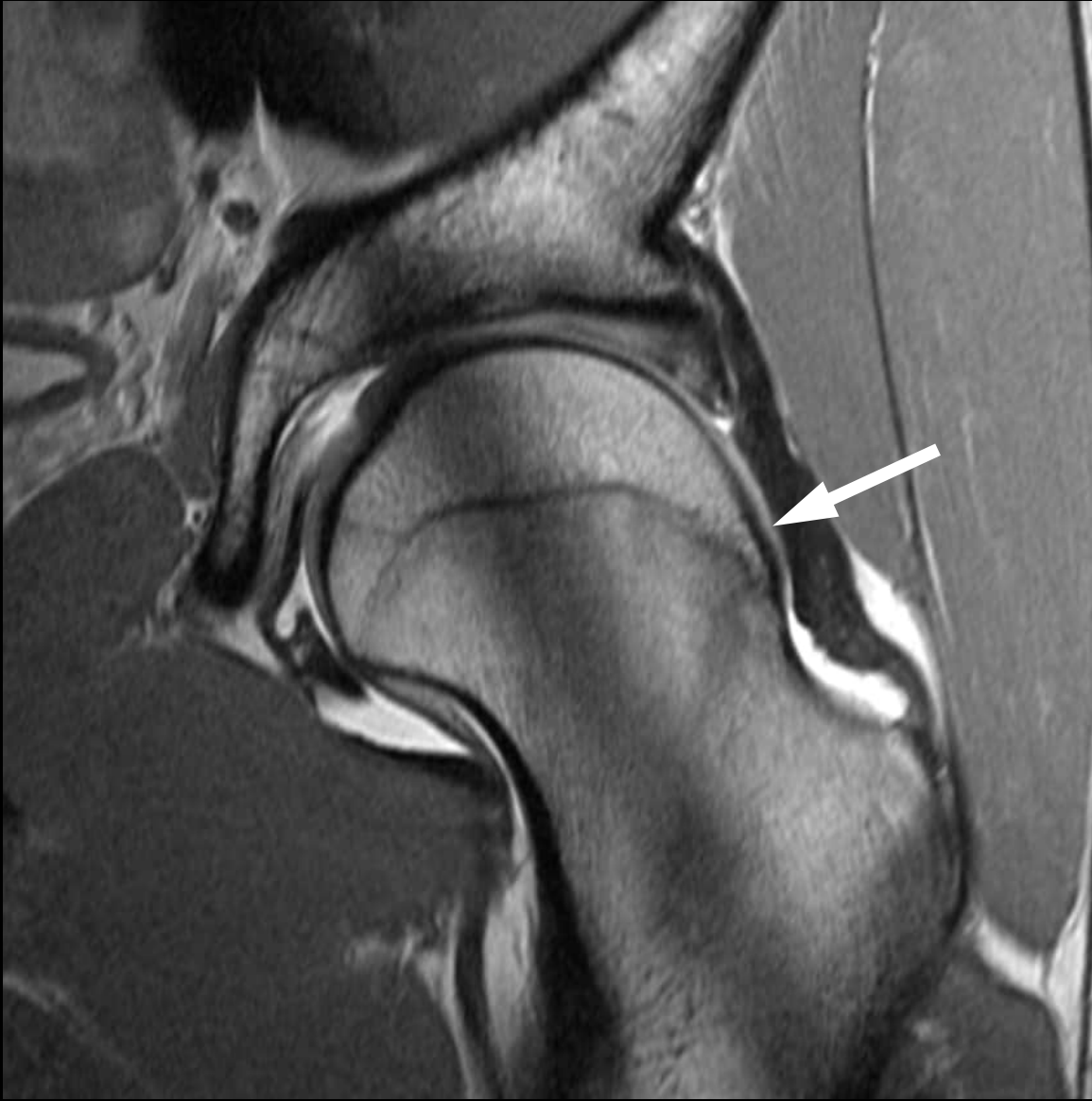26 year old patient with hip pain

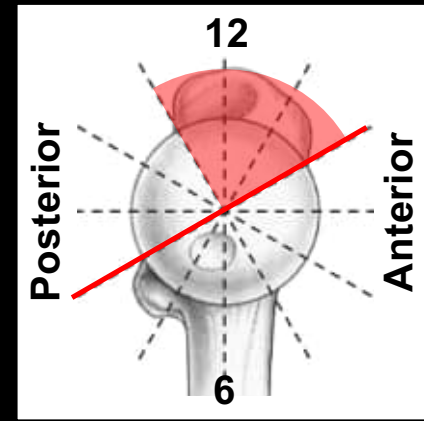
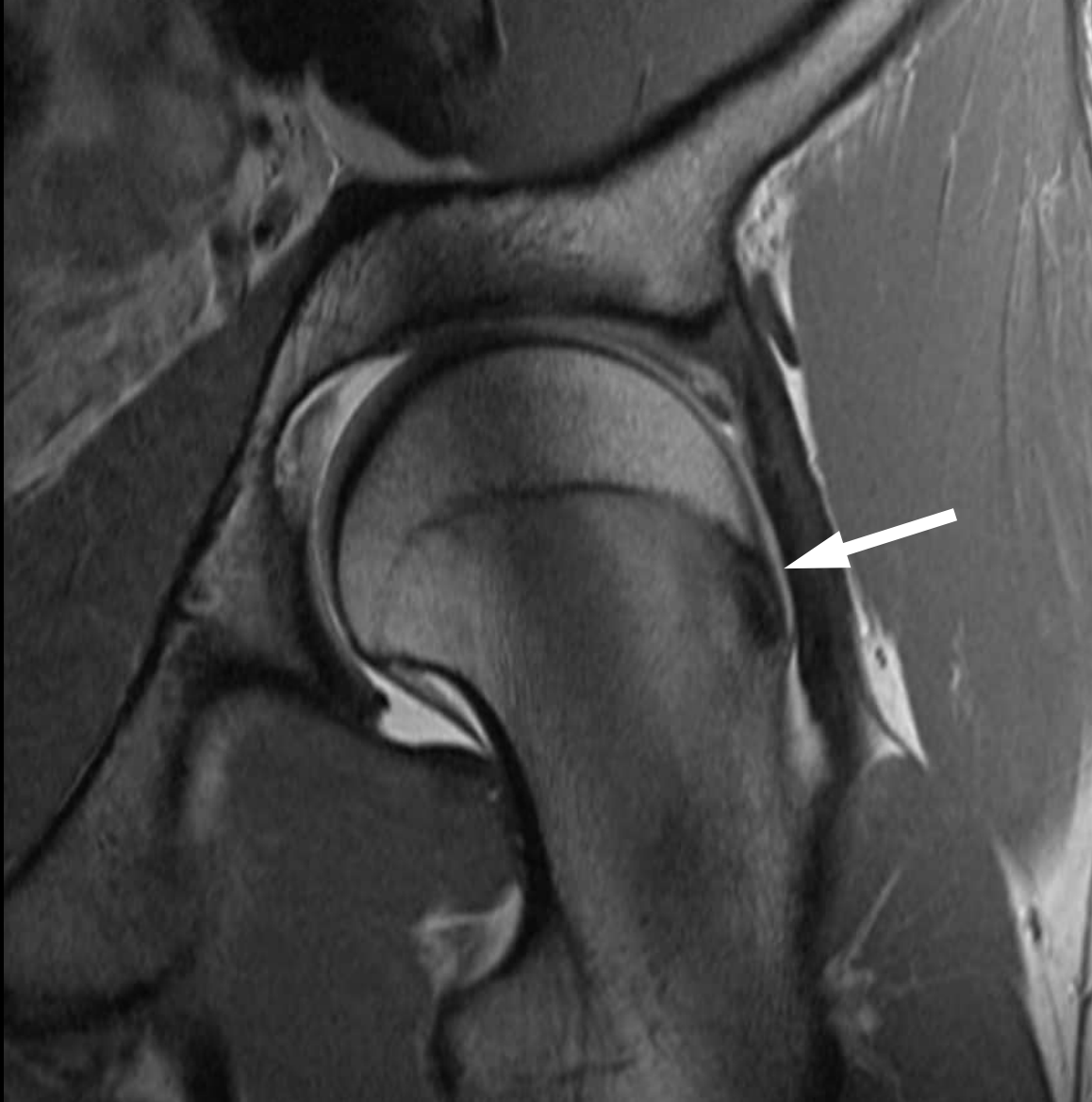

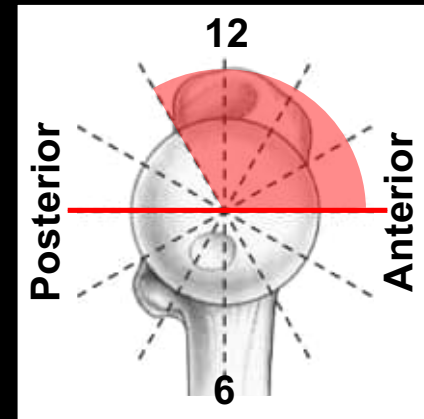
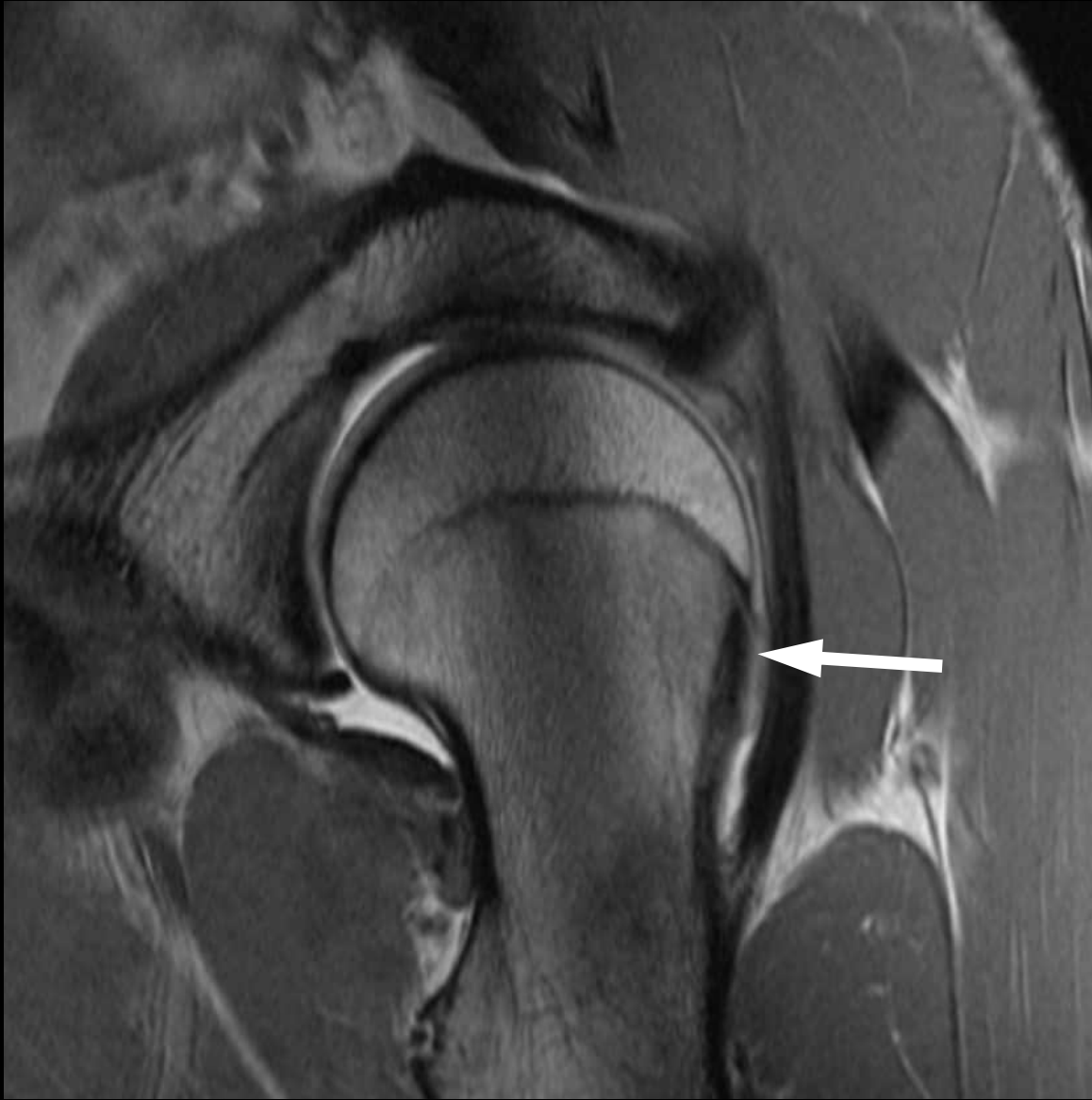26 year old patient with hip pain

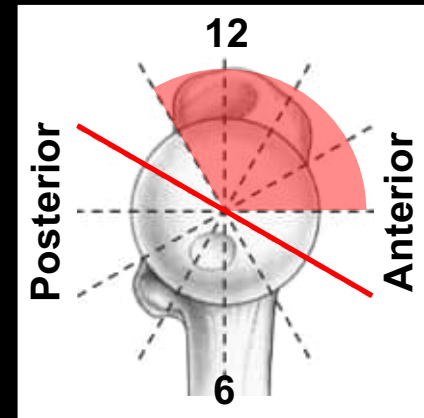
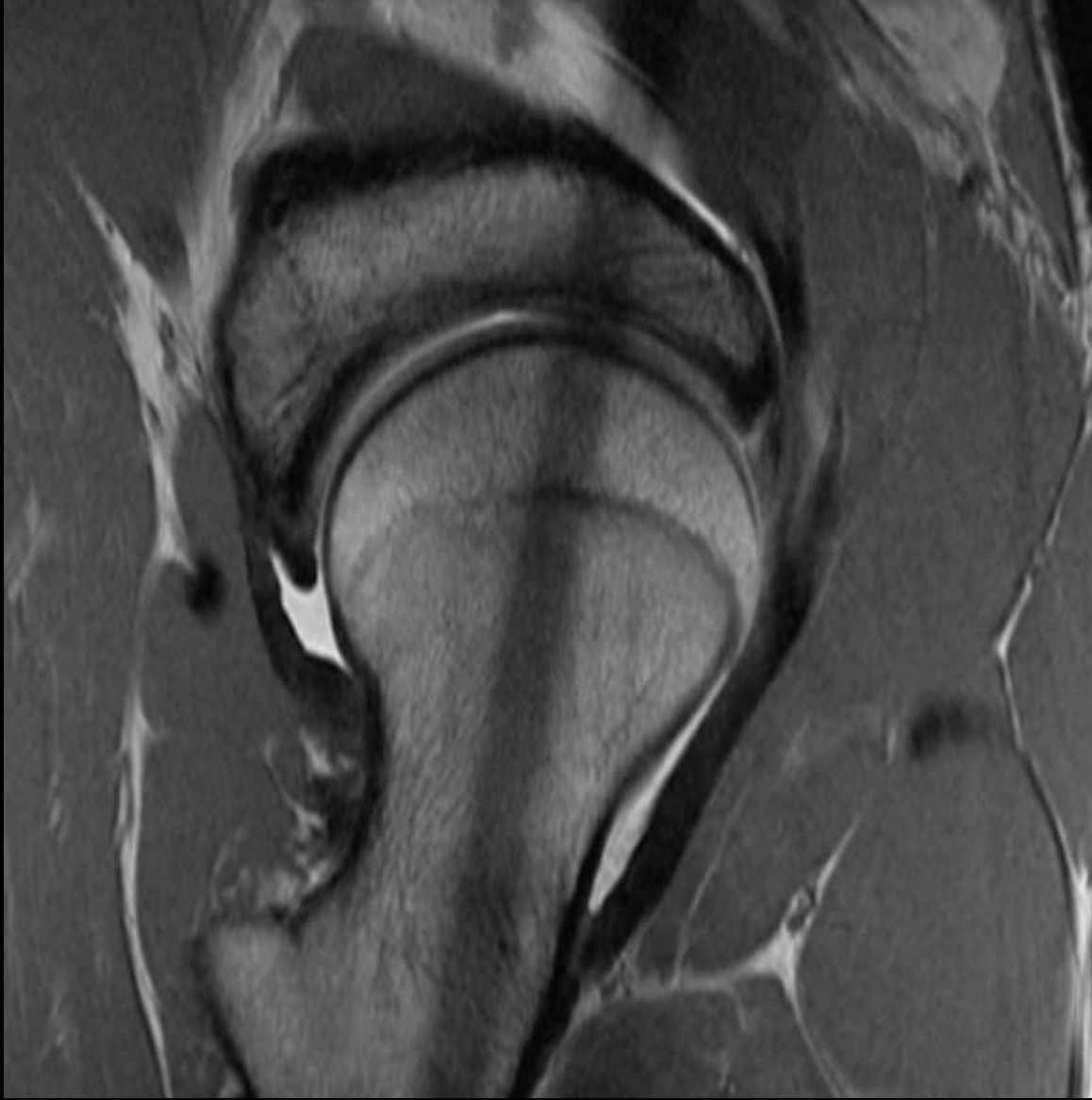

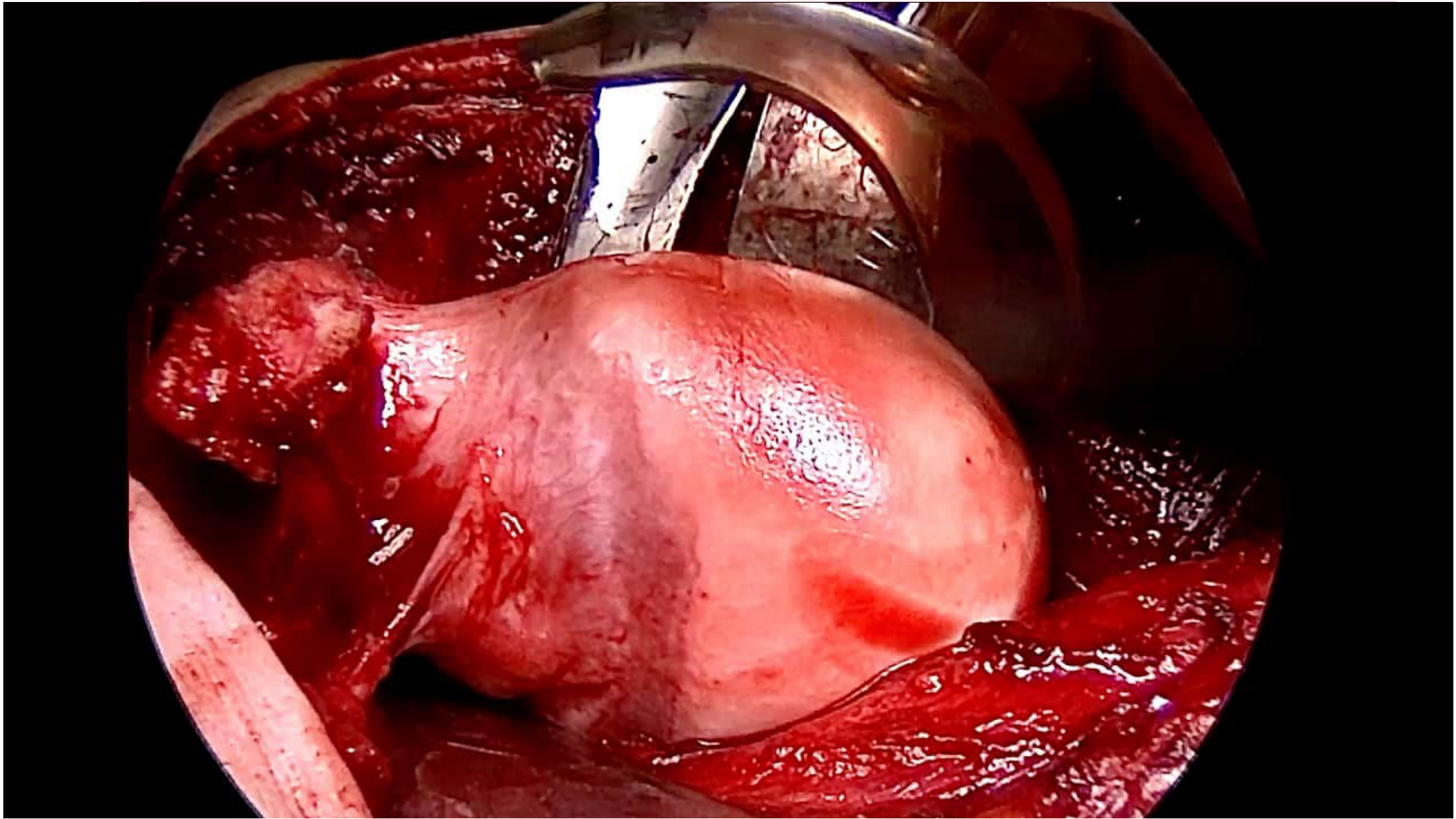


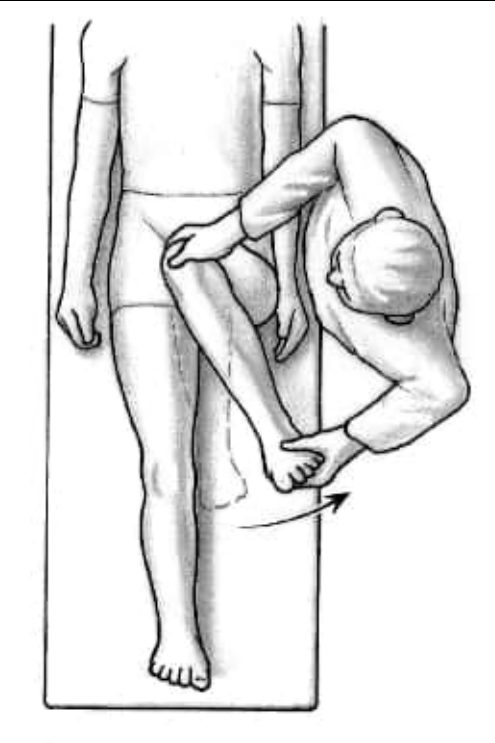




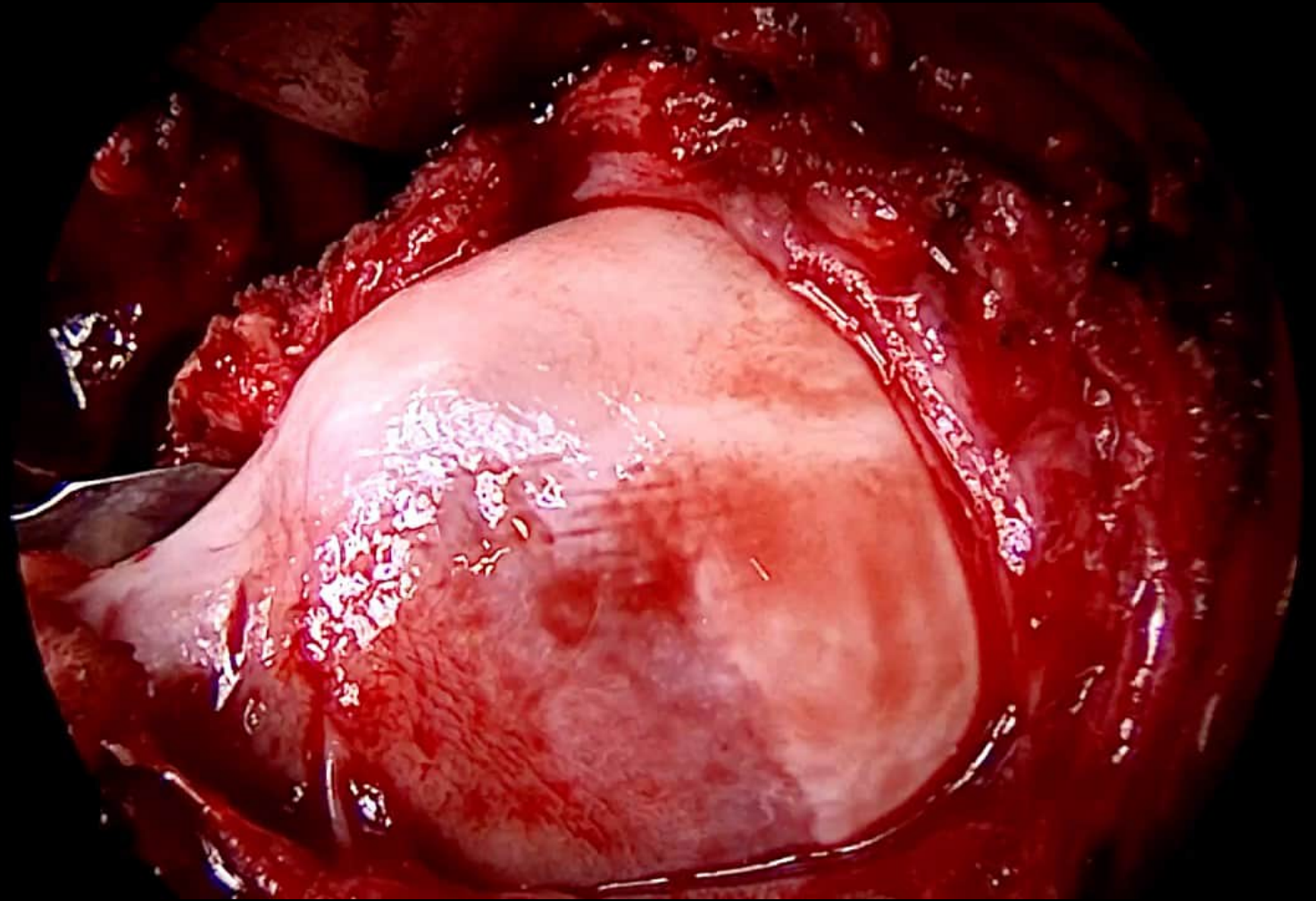


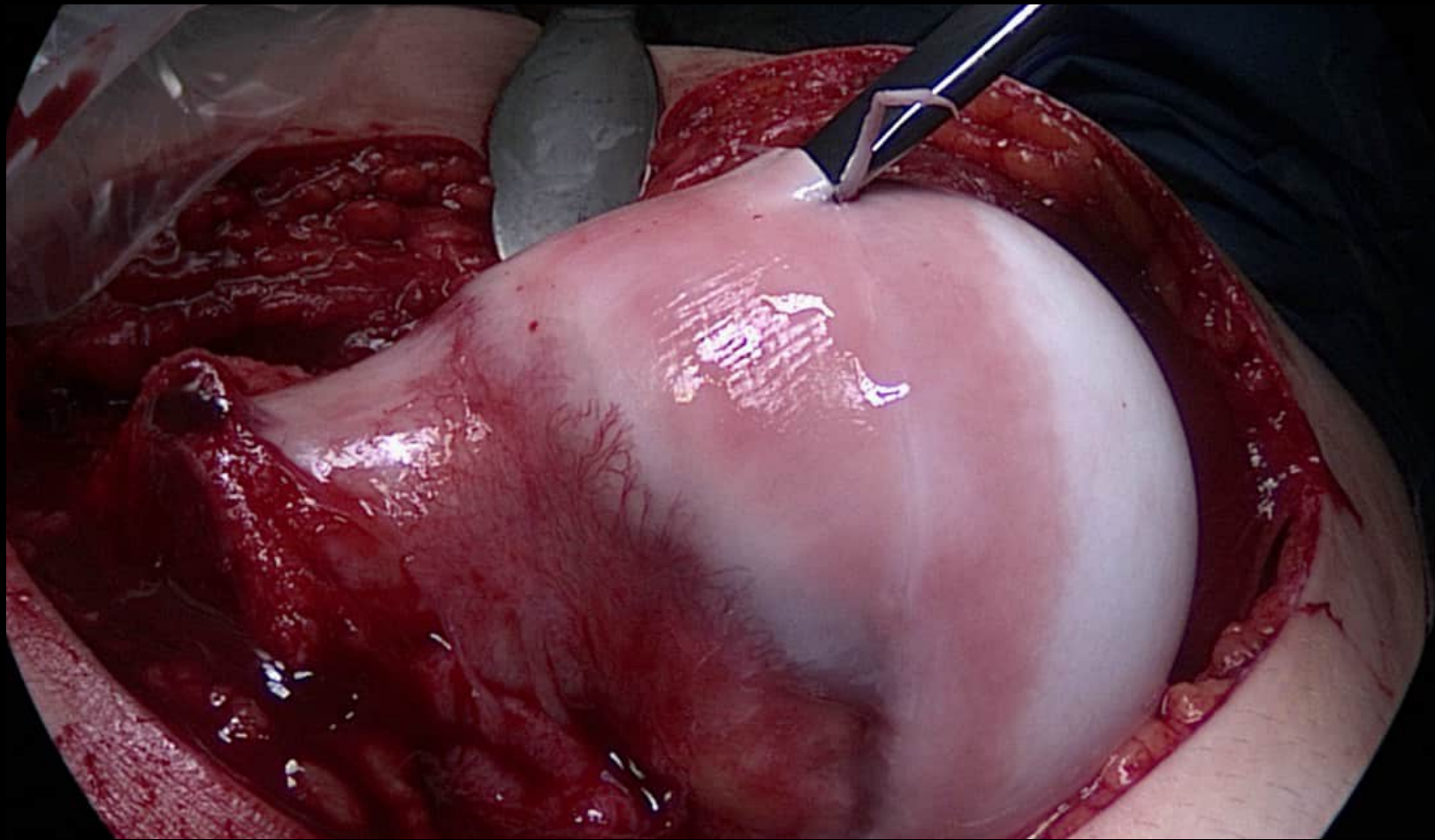


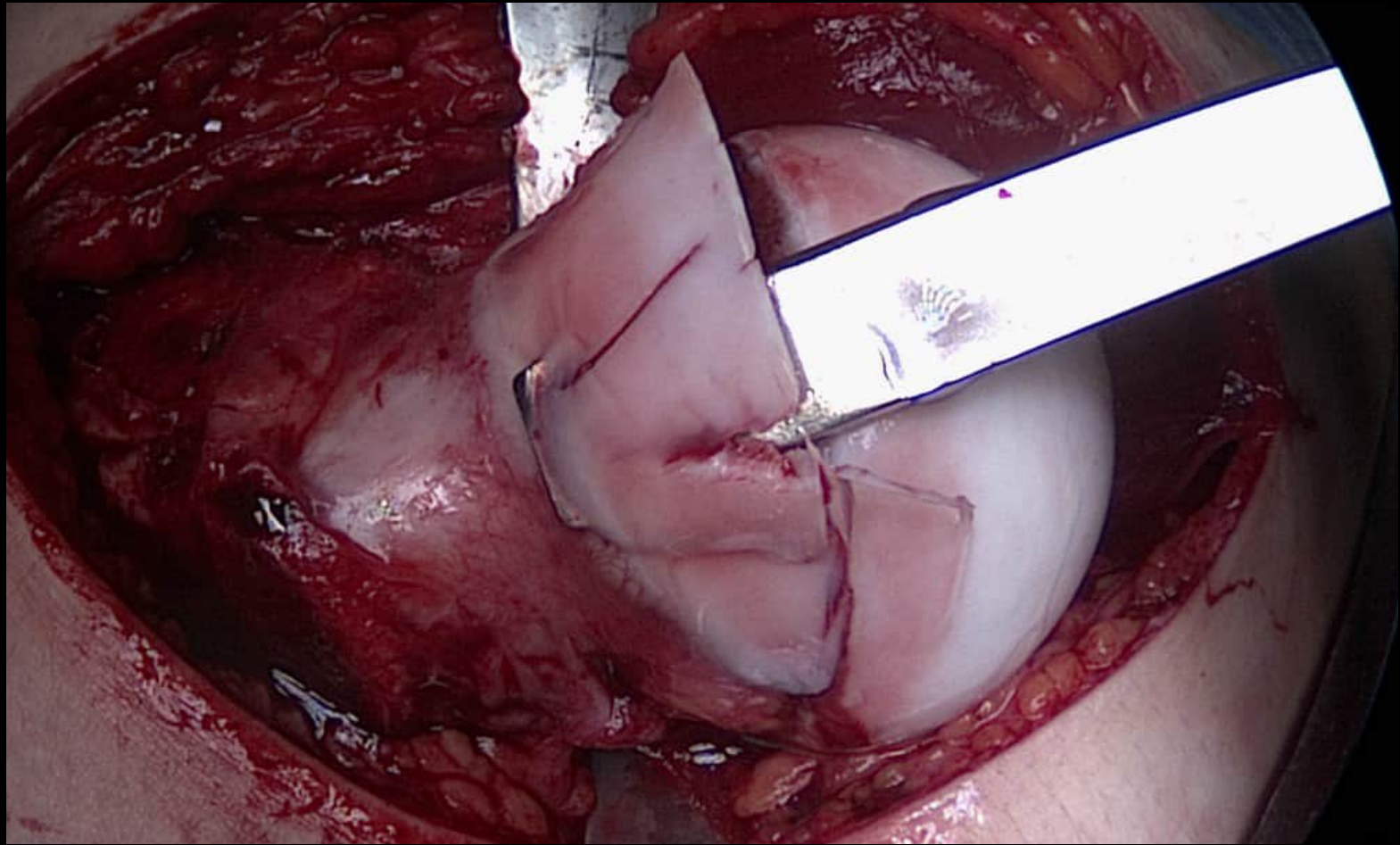


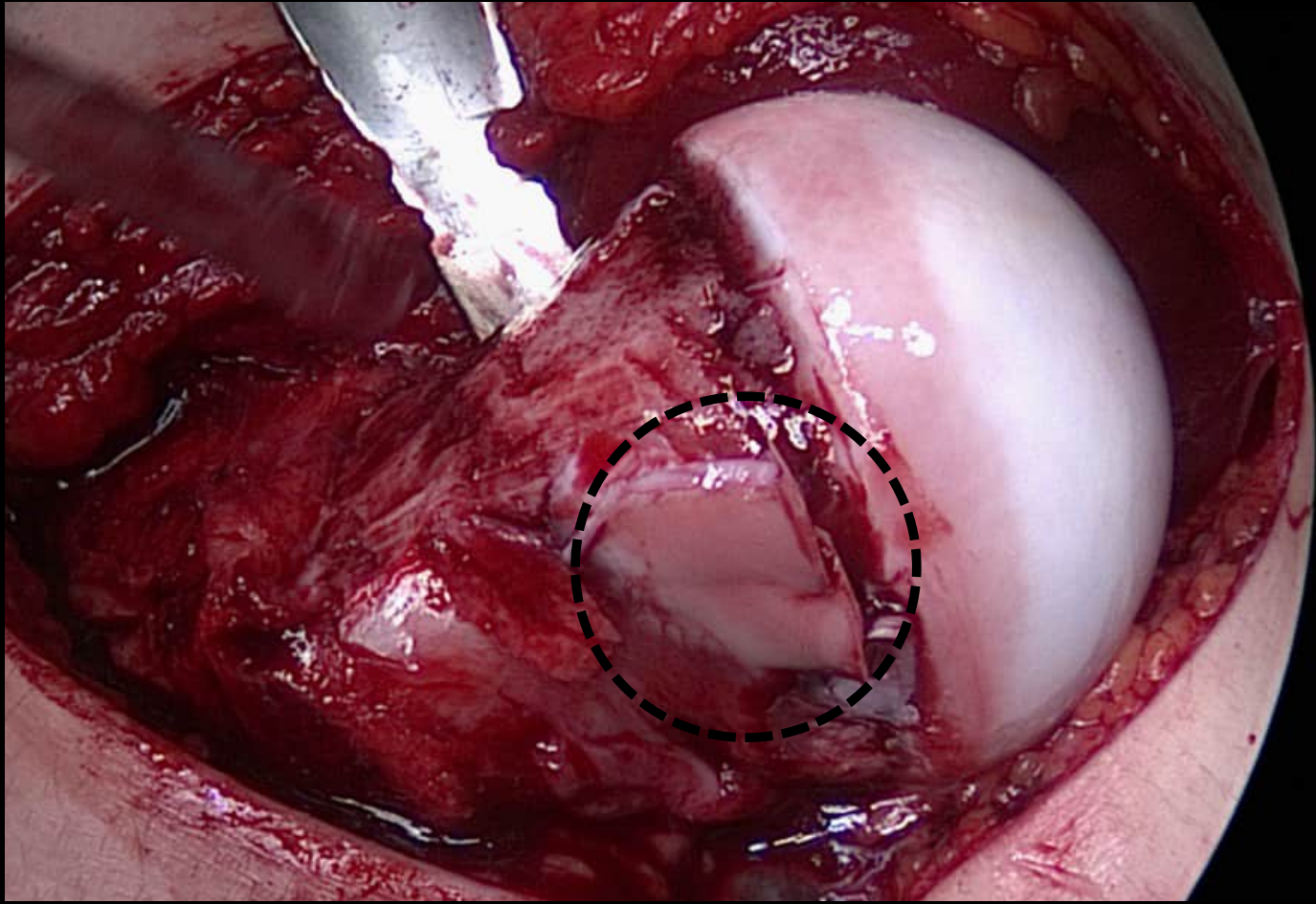


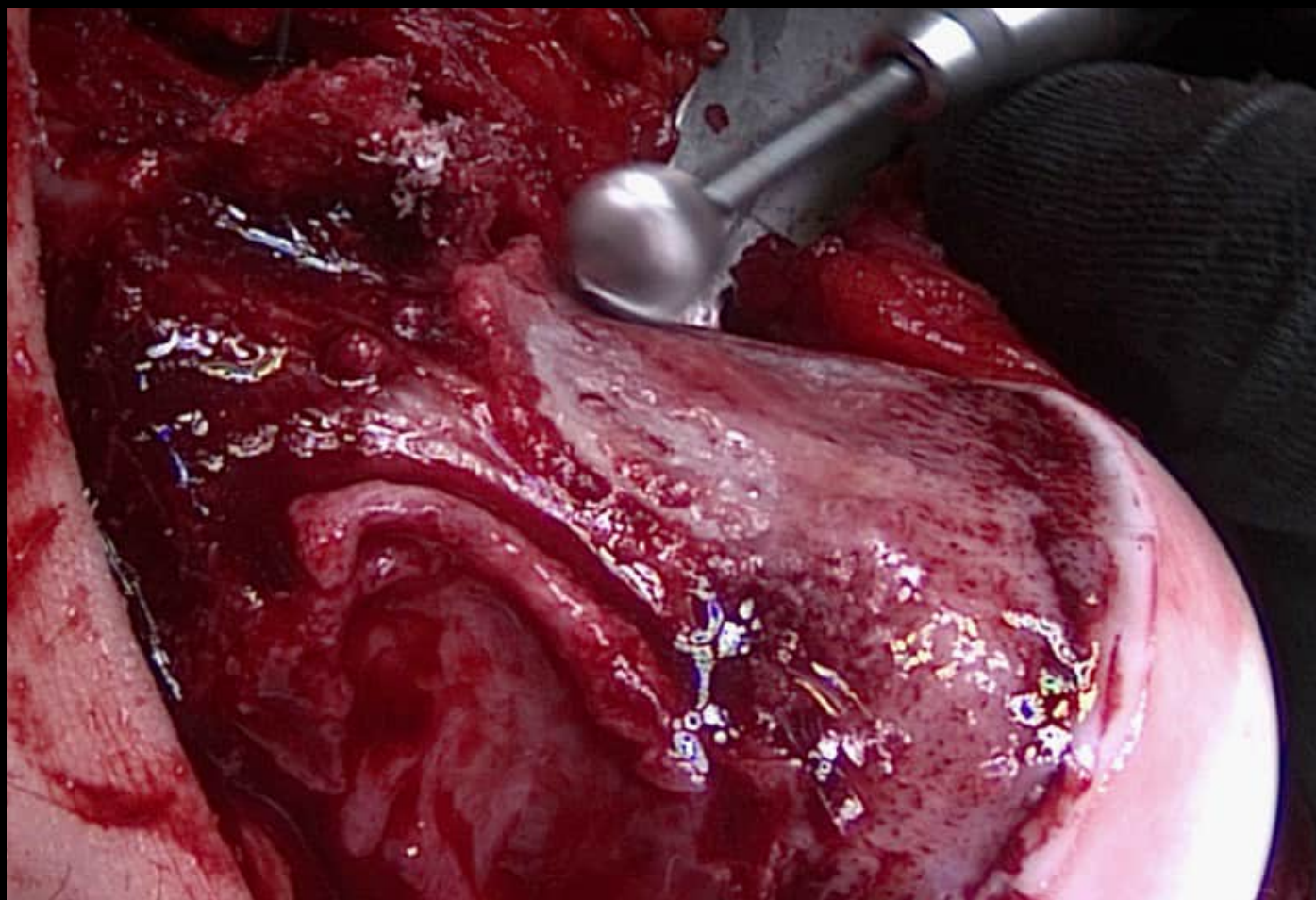
Flexion and
Internal rotation

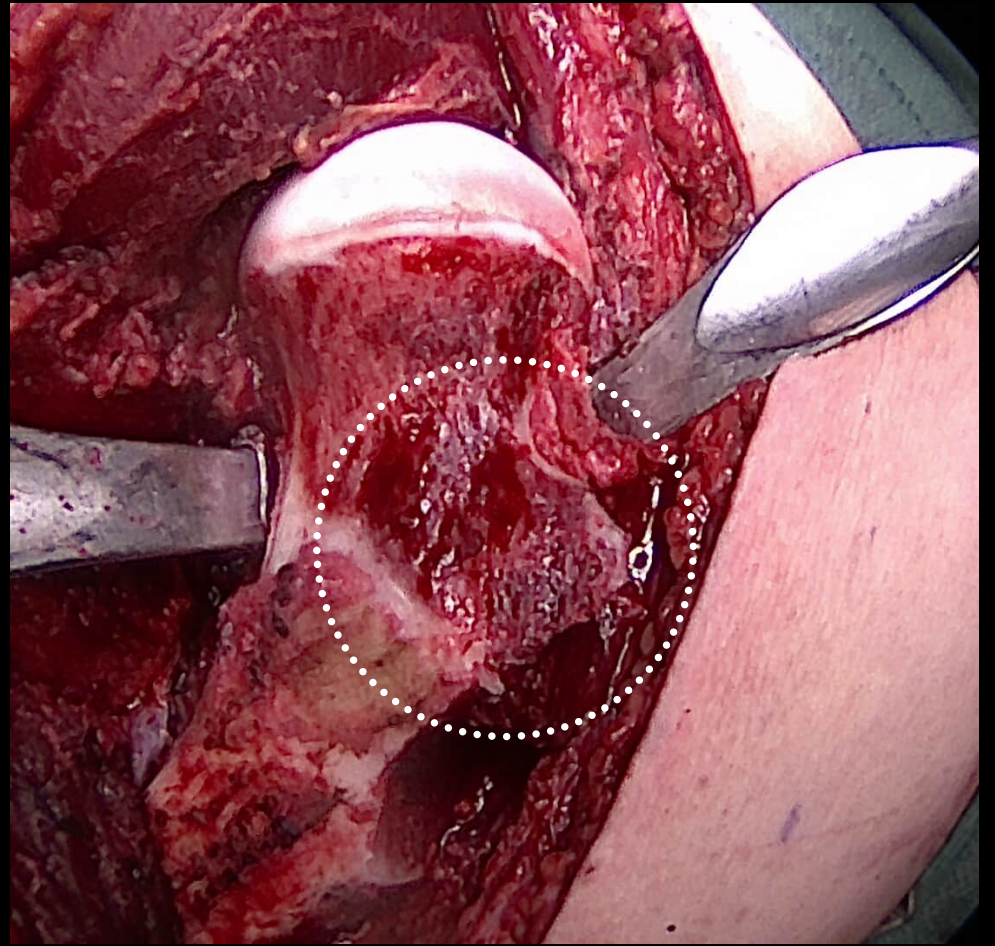
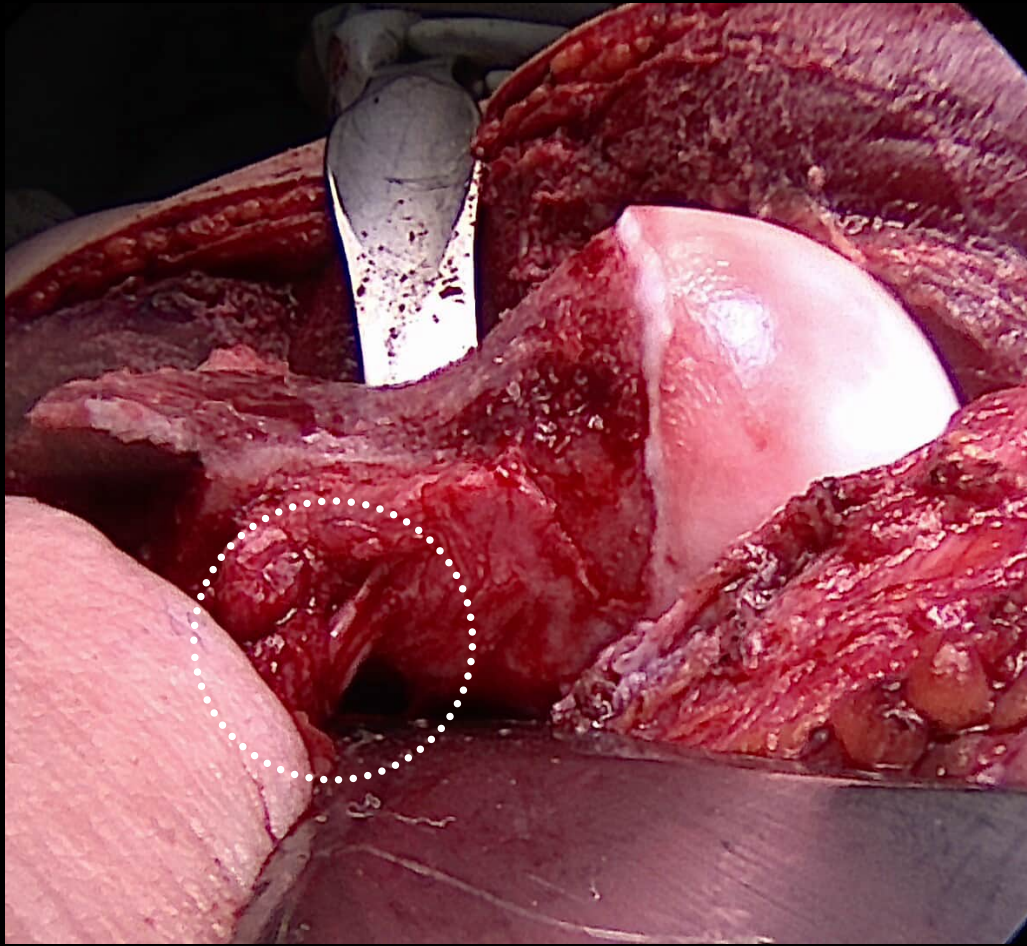


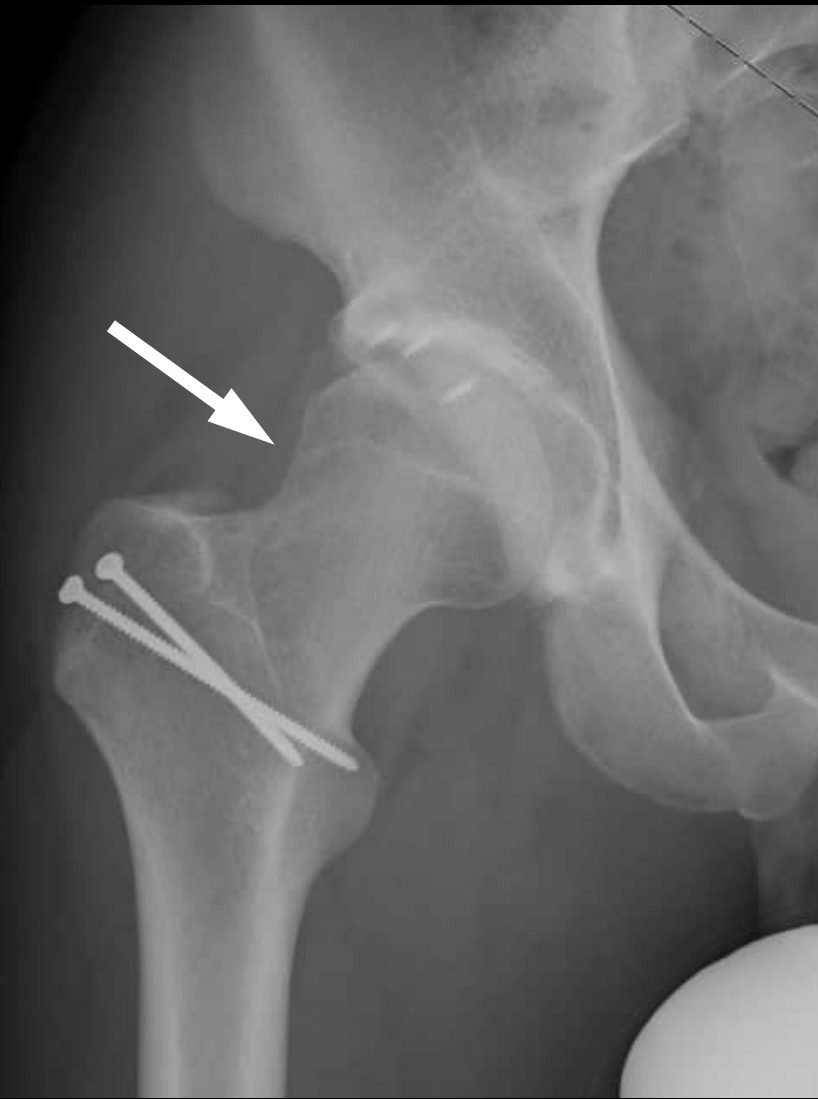
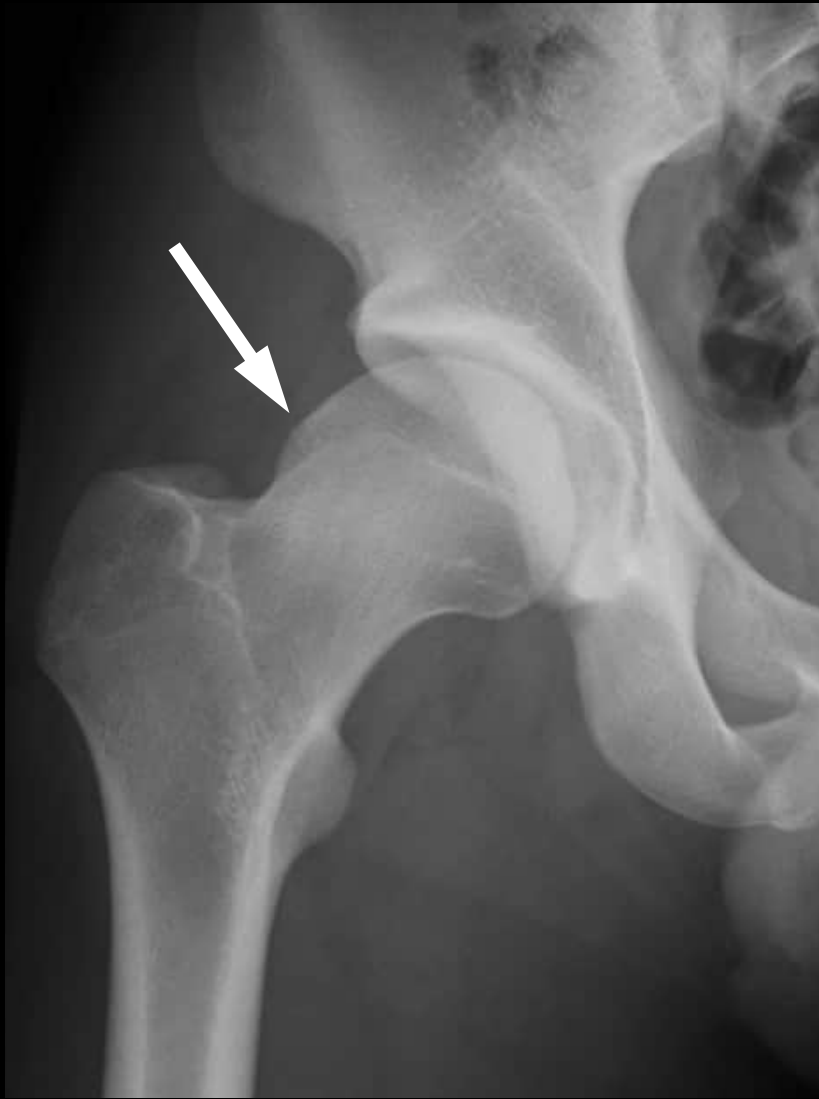


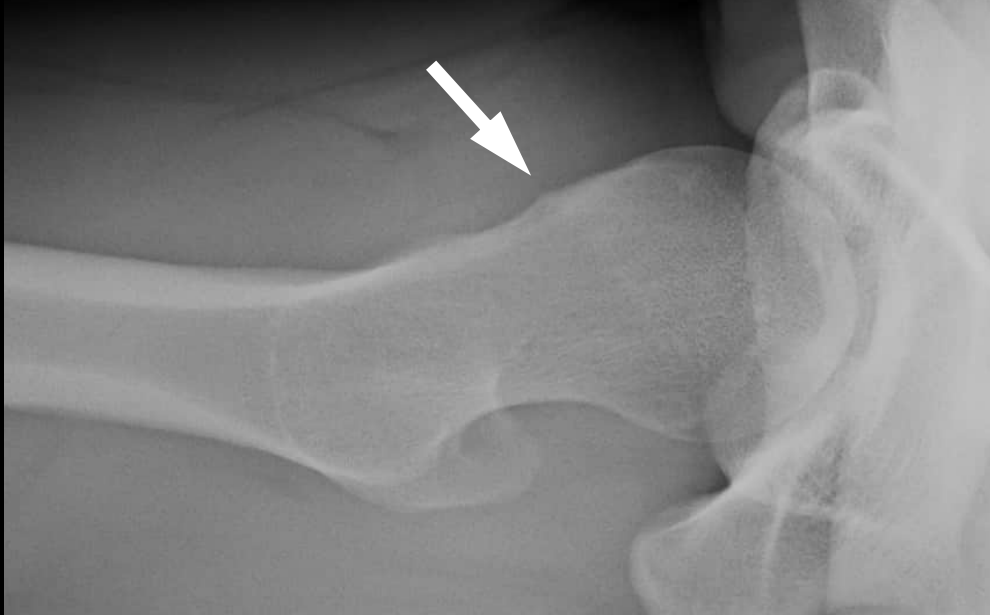
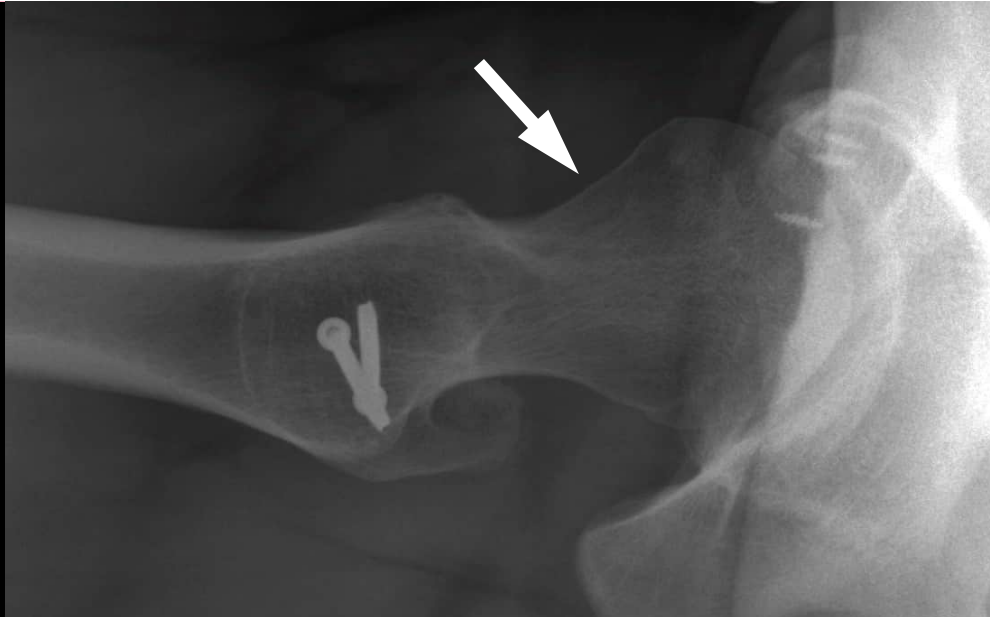


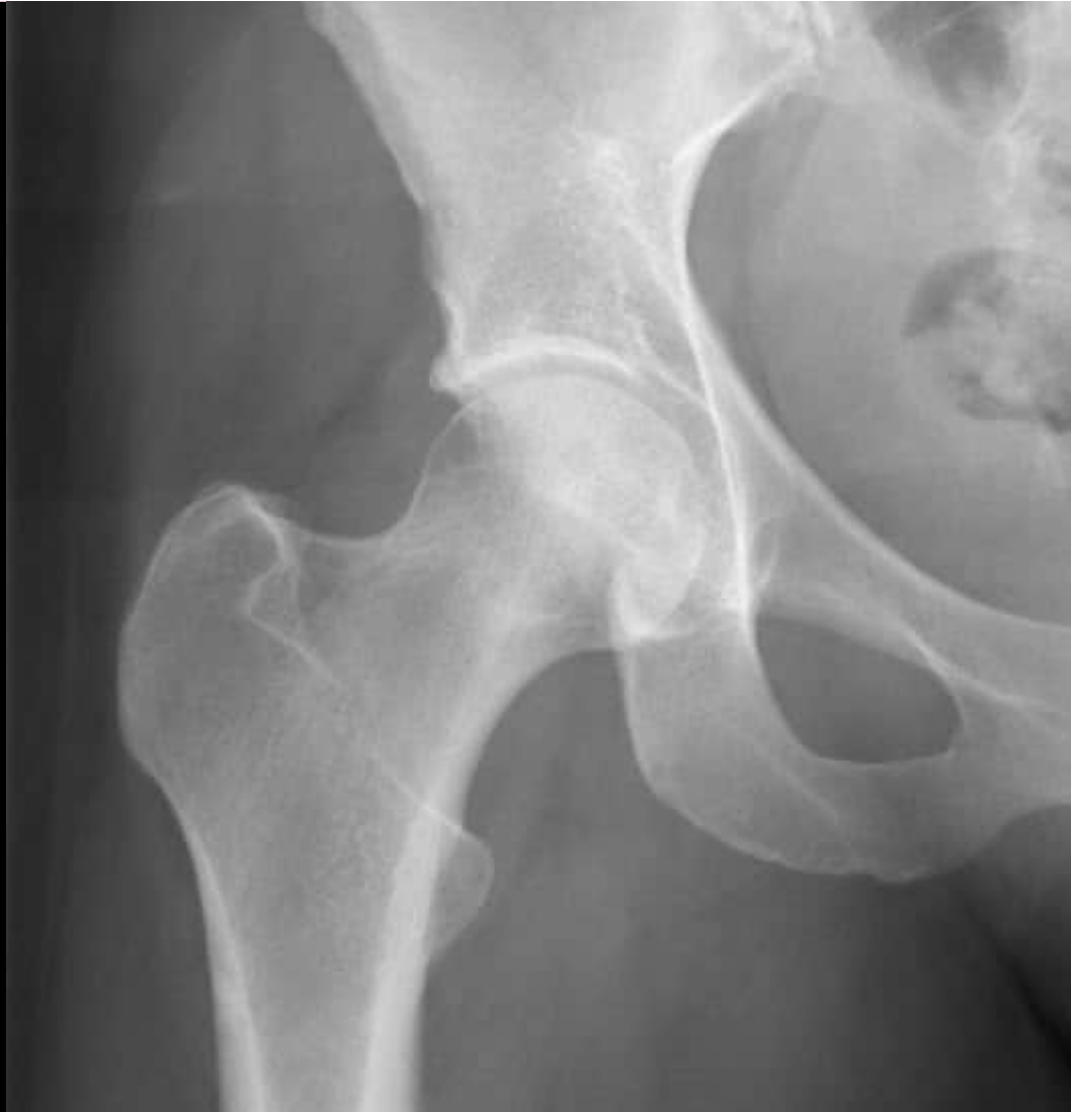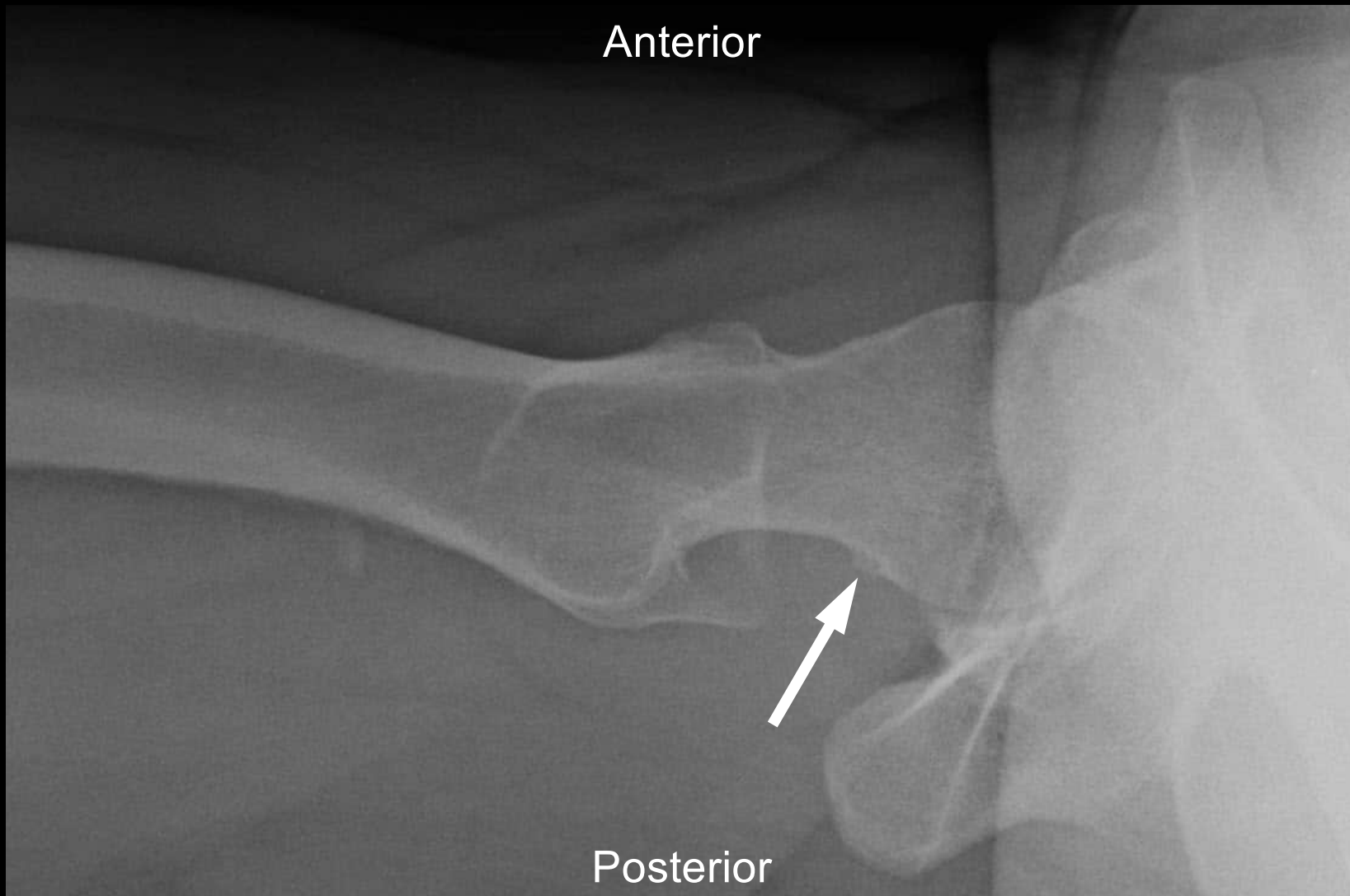




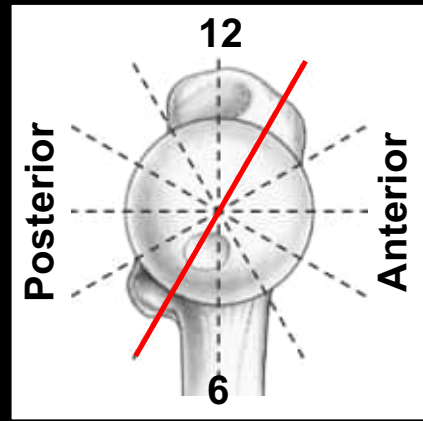


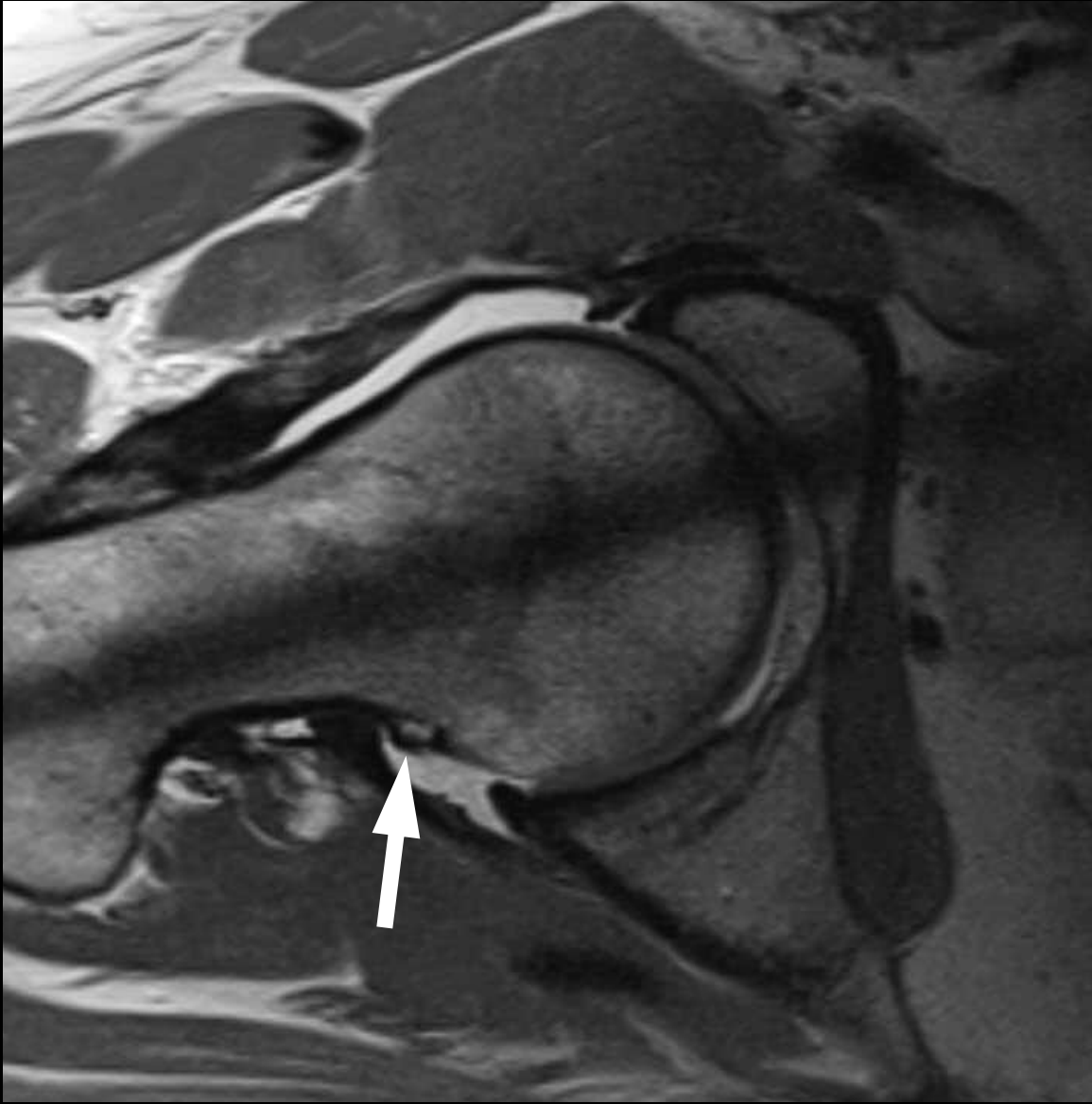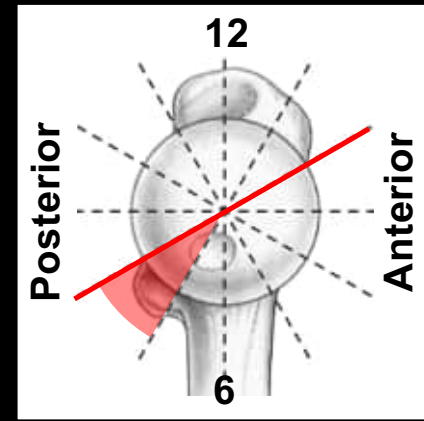


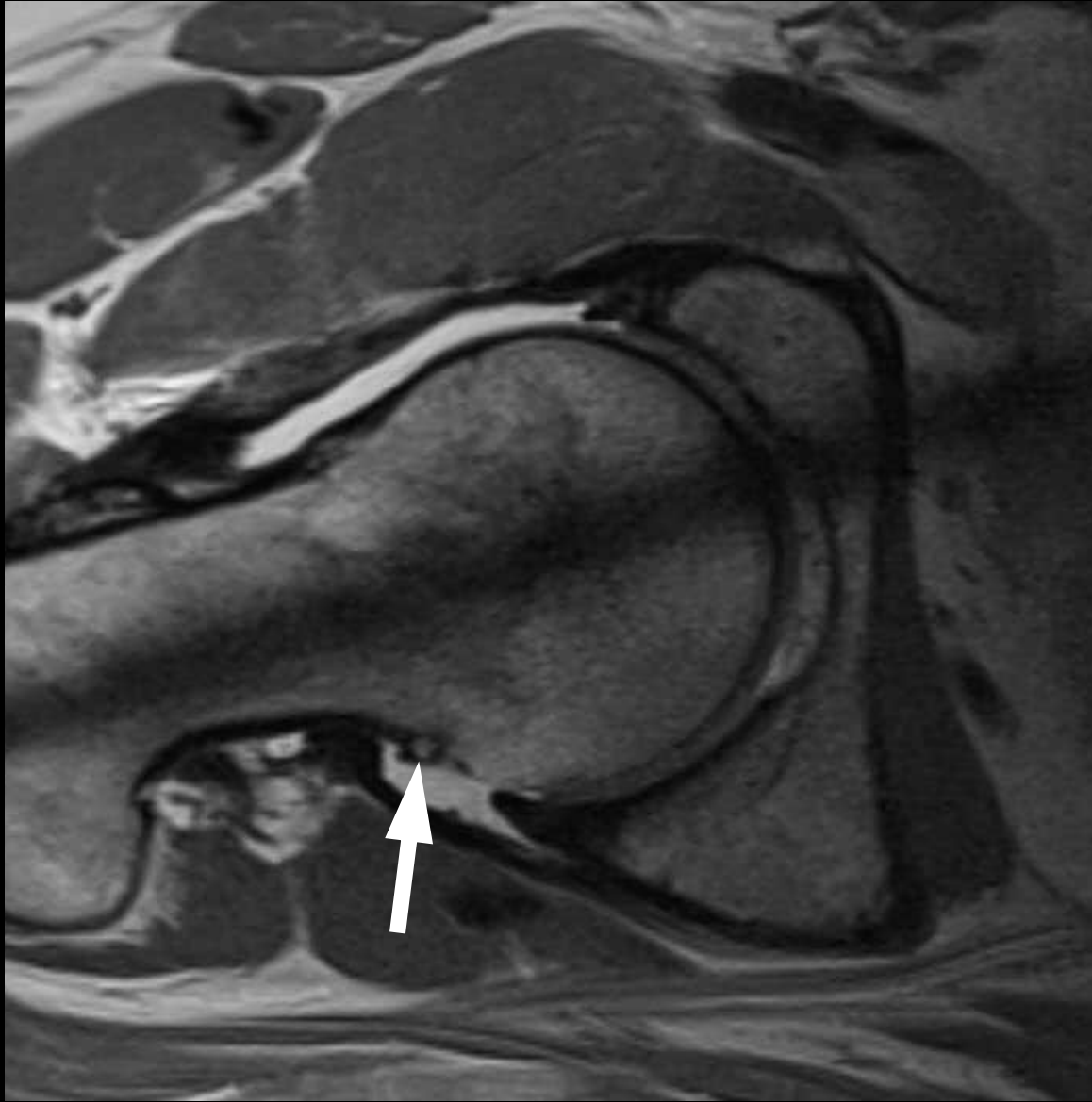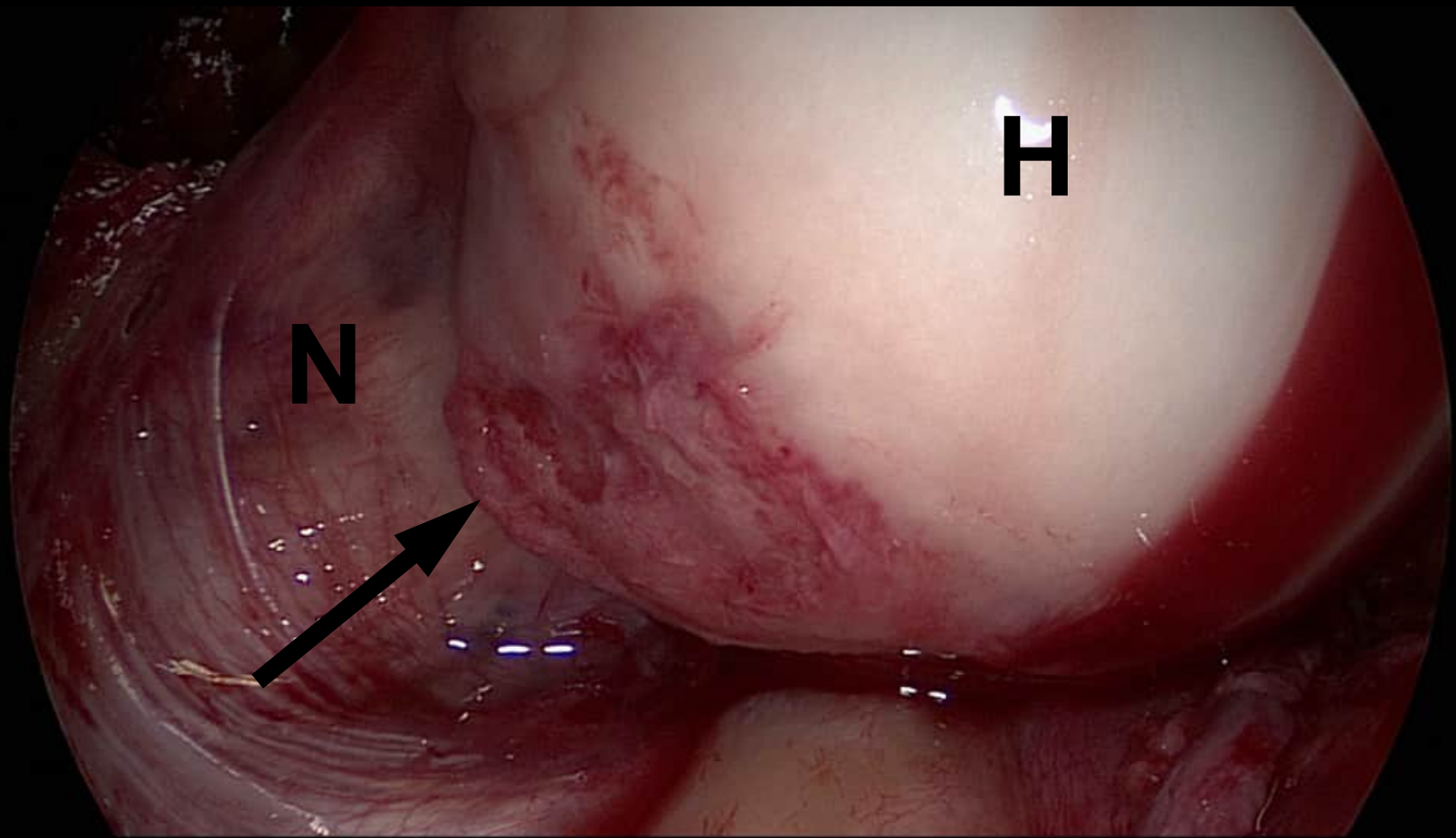
35 year old female patient with hip pain

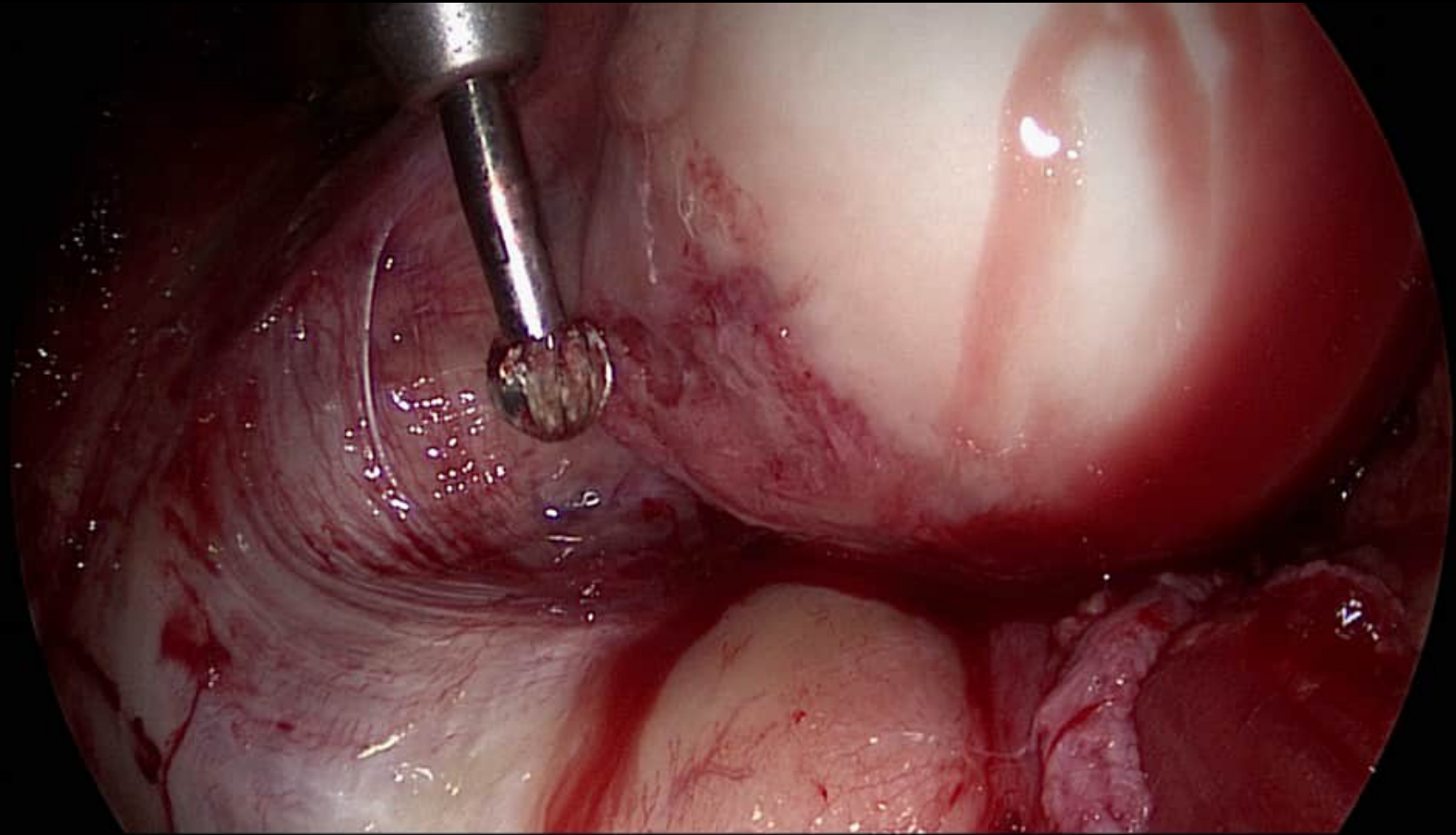


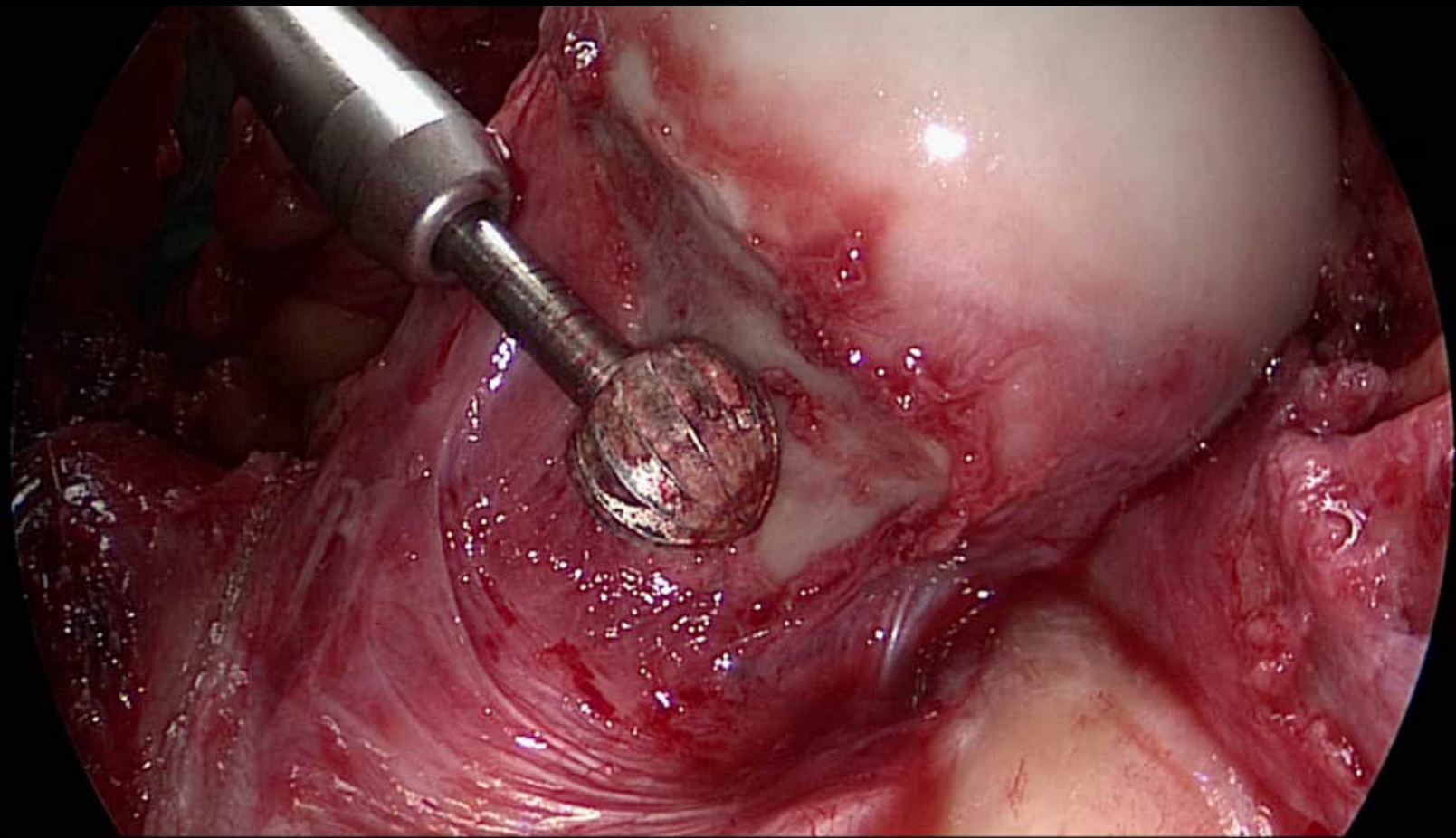
35 year old female patient with hip pain

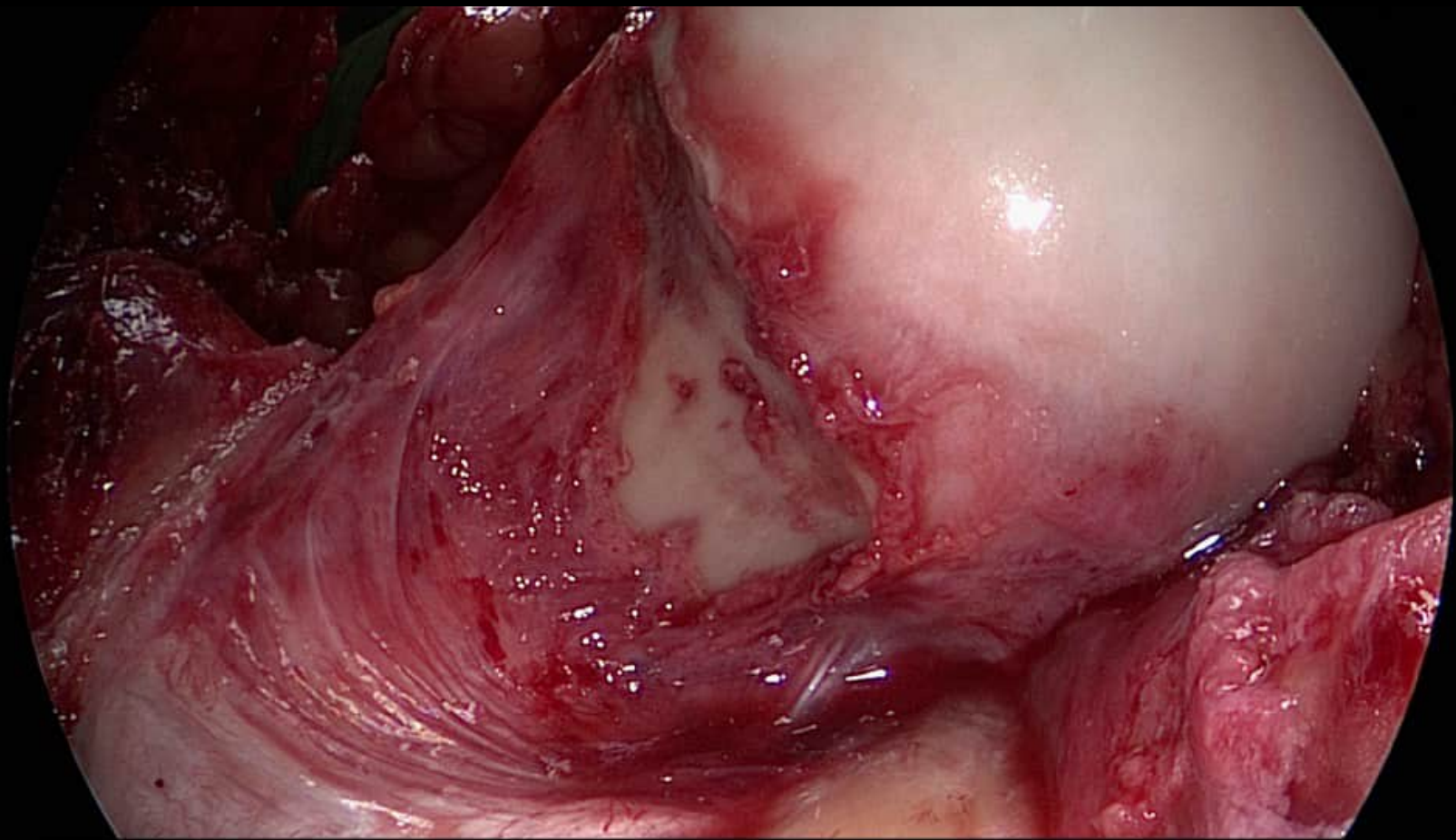




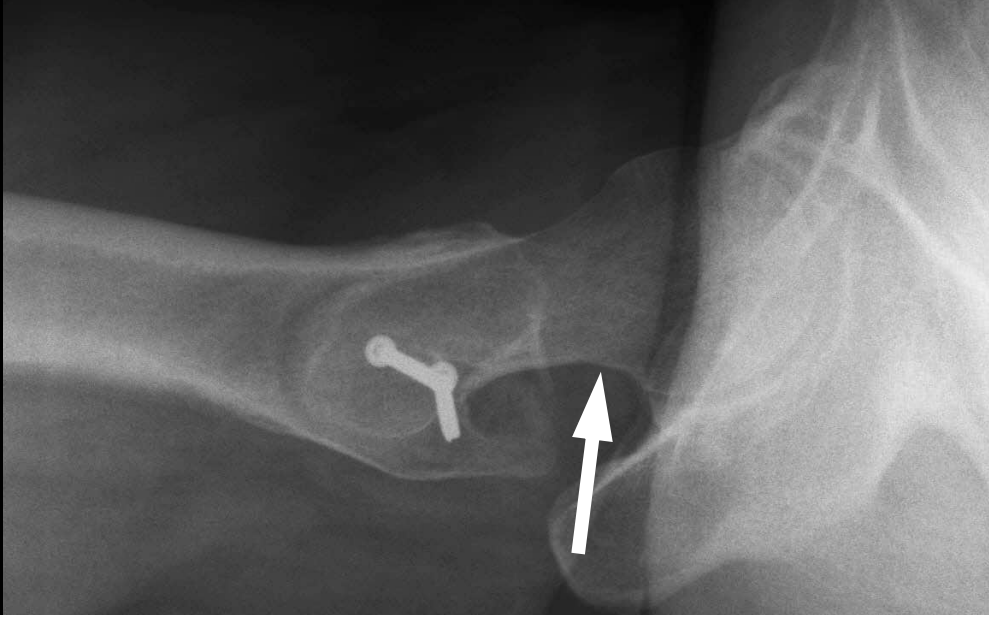



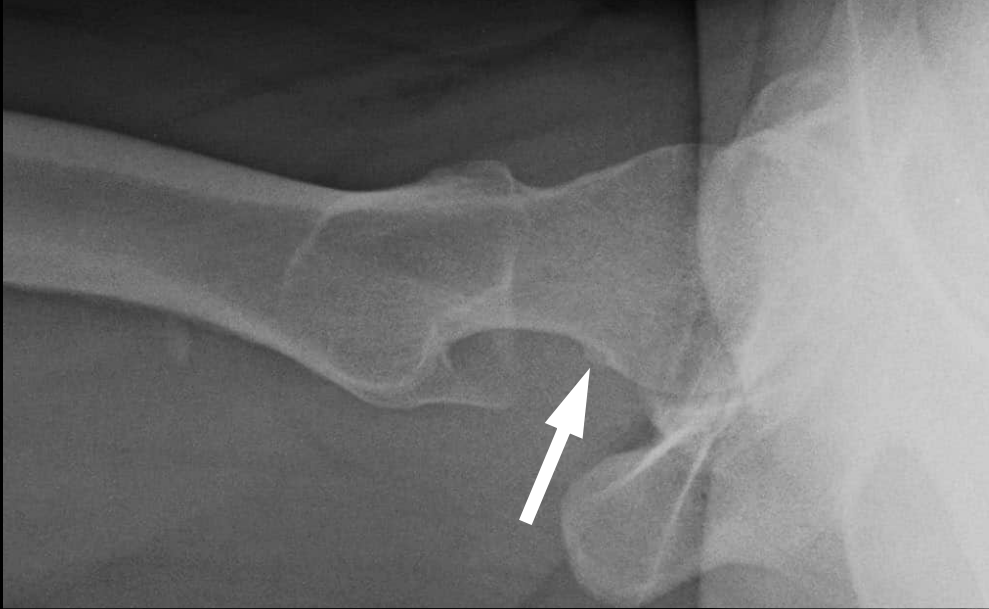



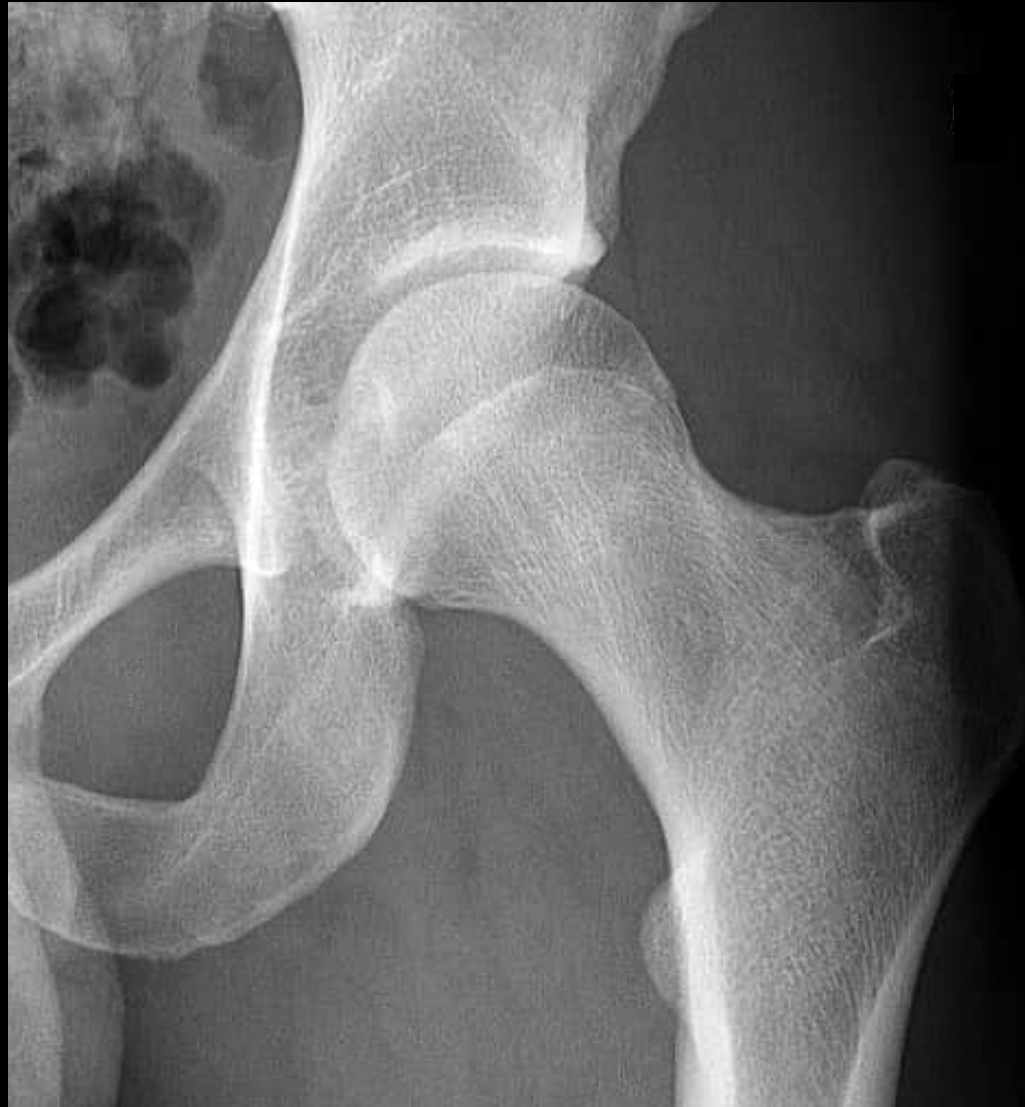
Postoperative



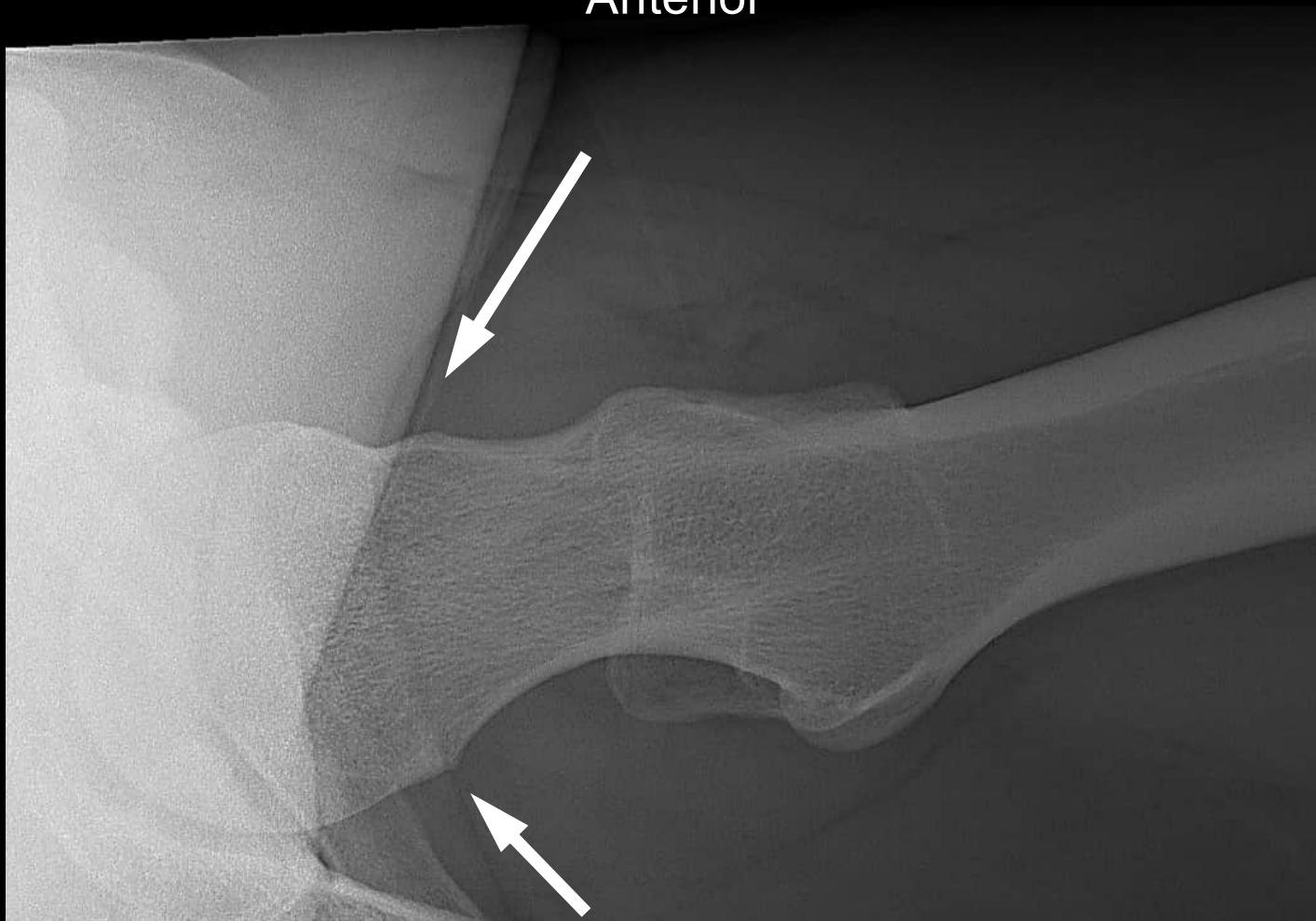Preoperative



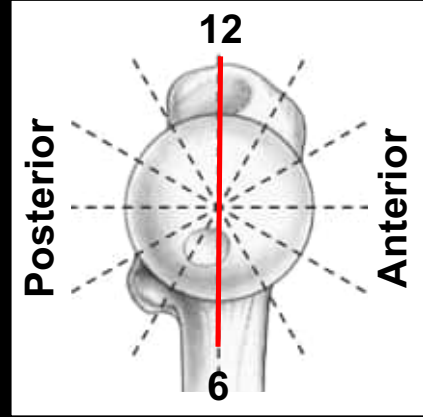
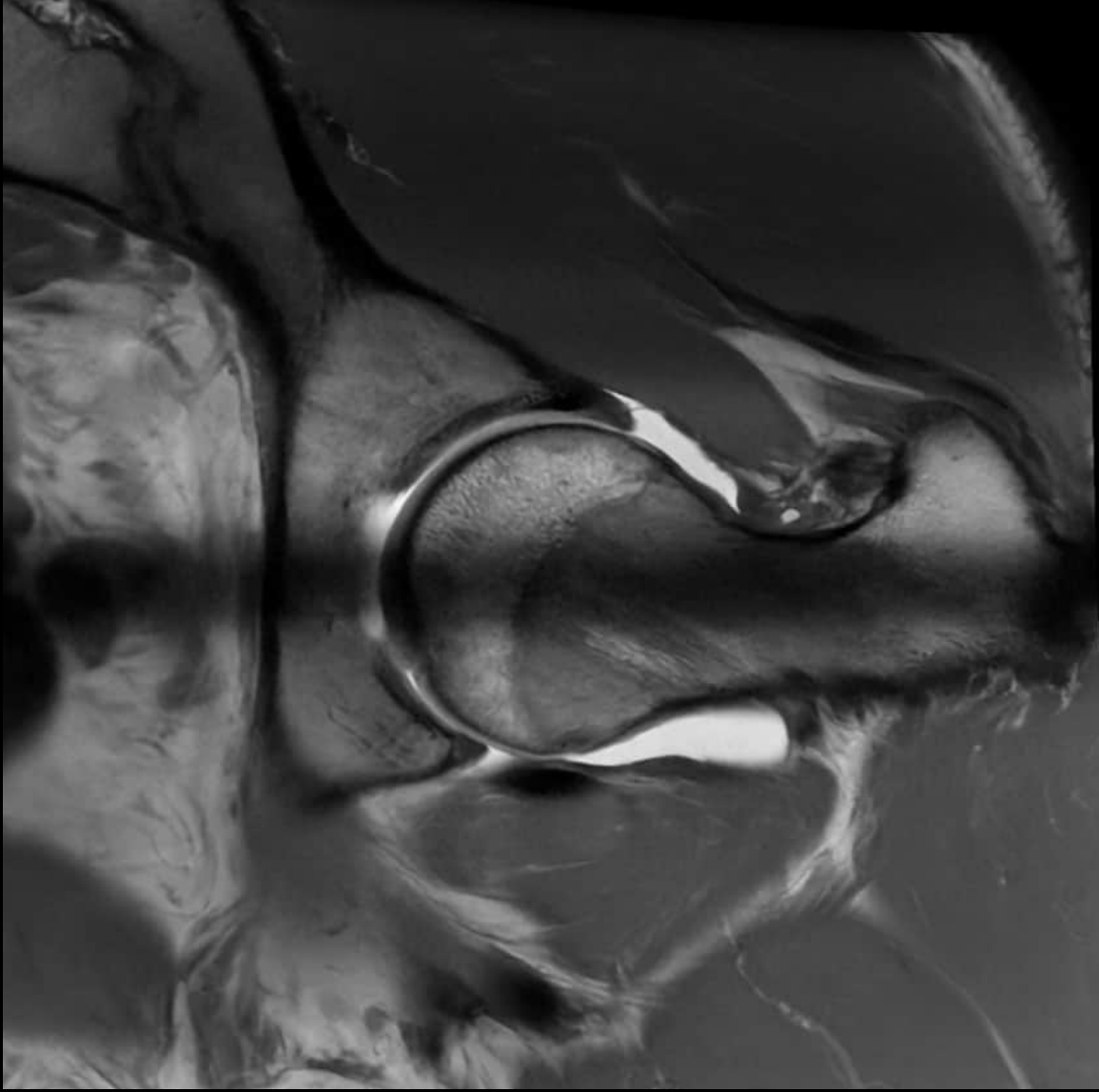


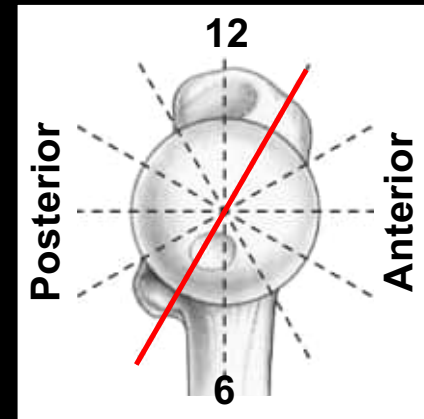
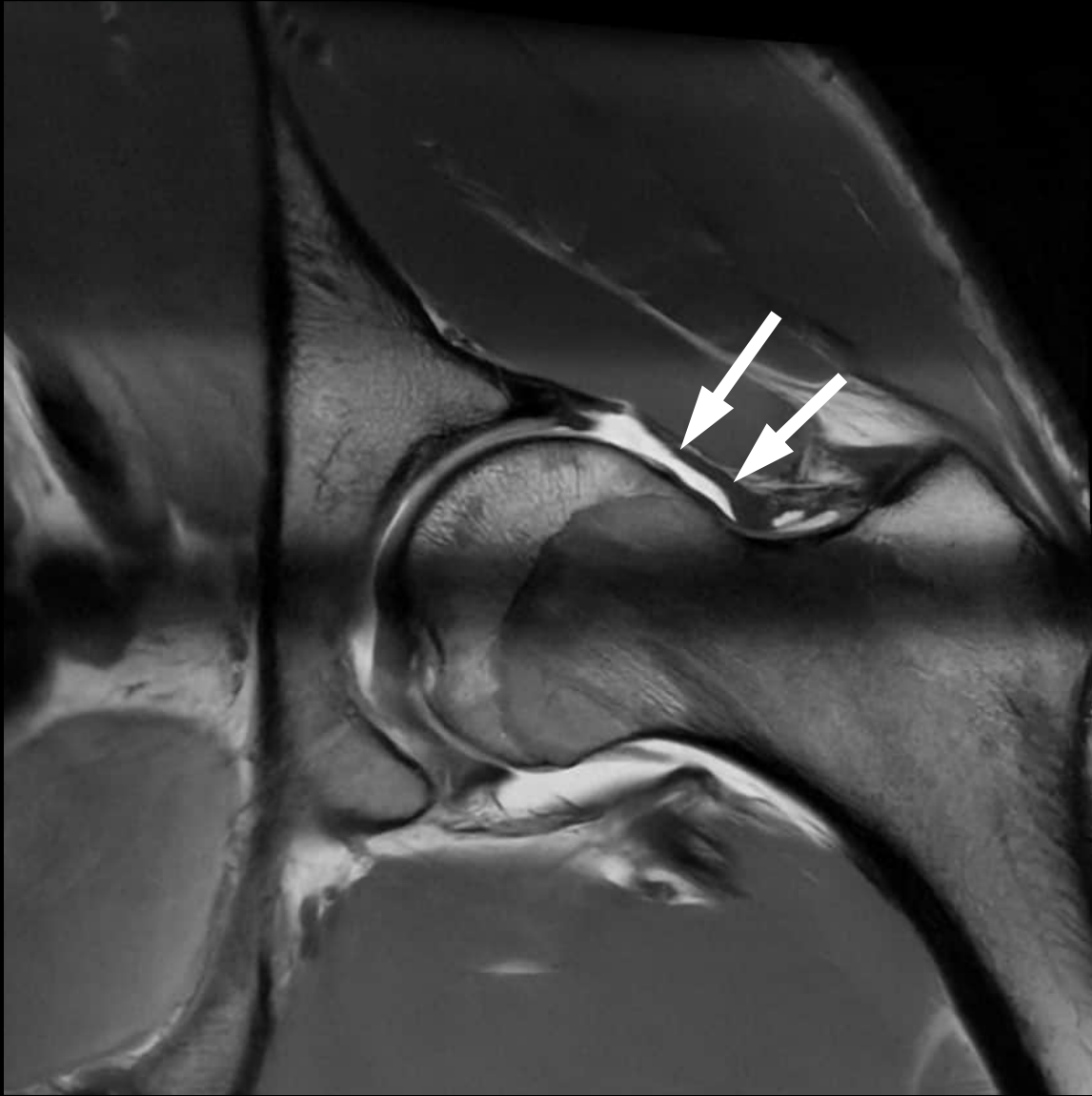
21 year old male patient with hip and buttock pain

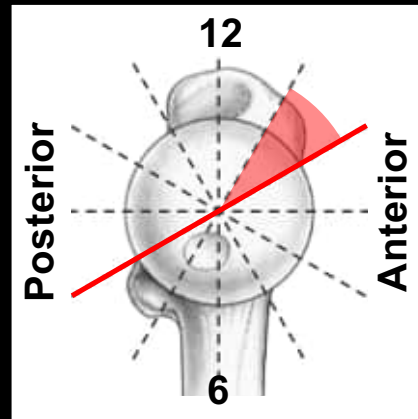
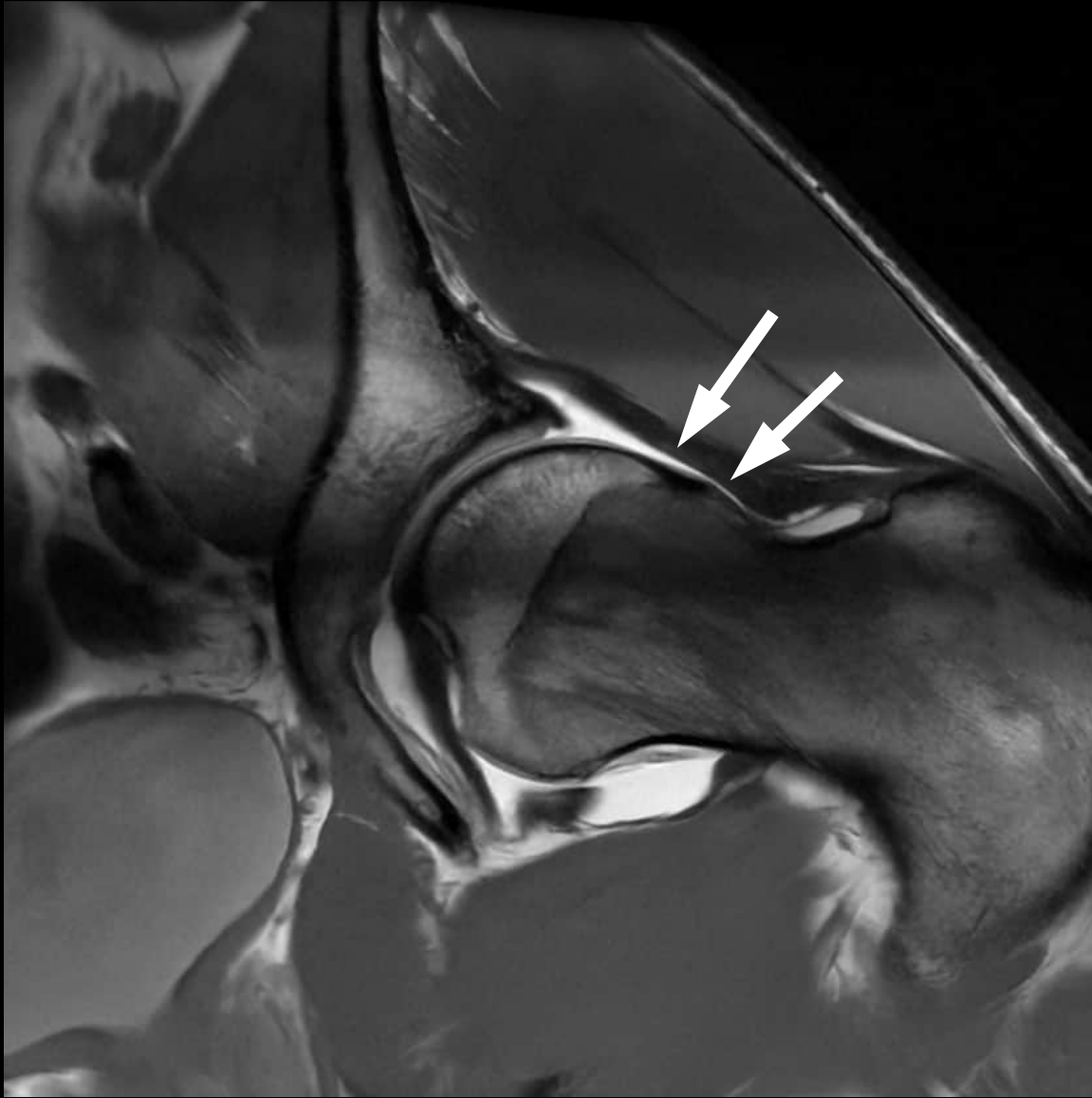
Anterior

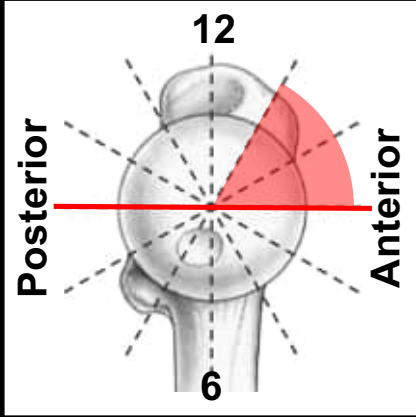
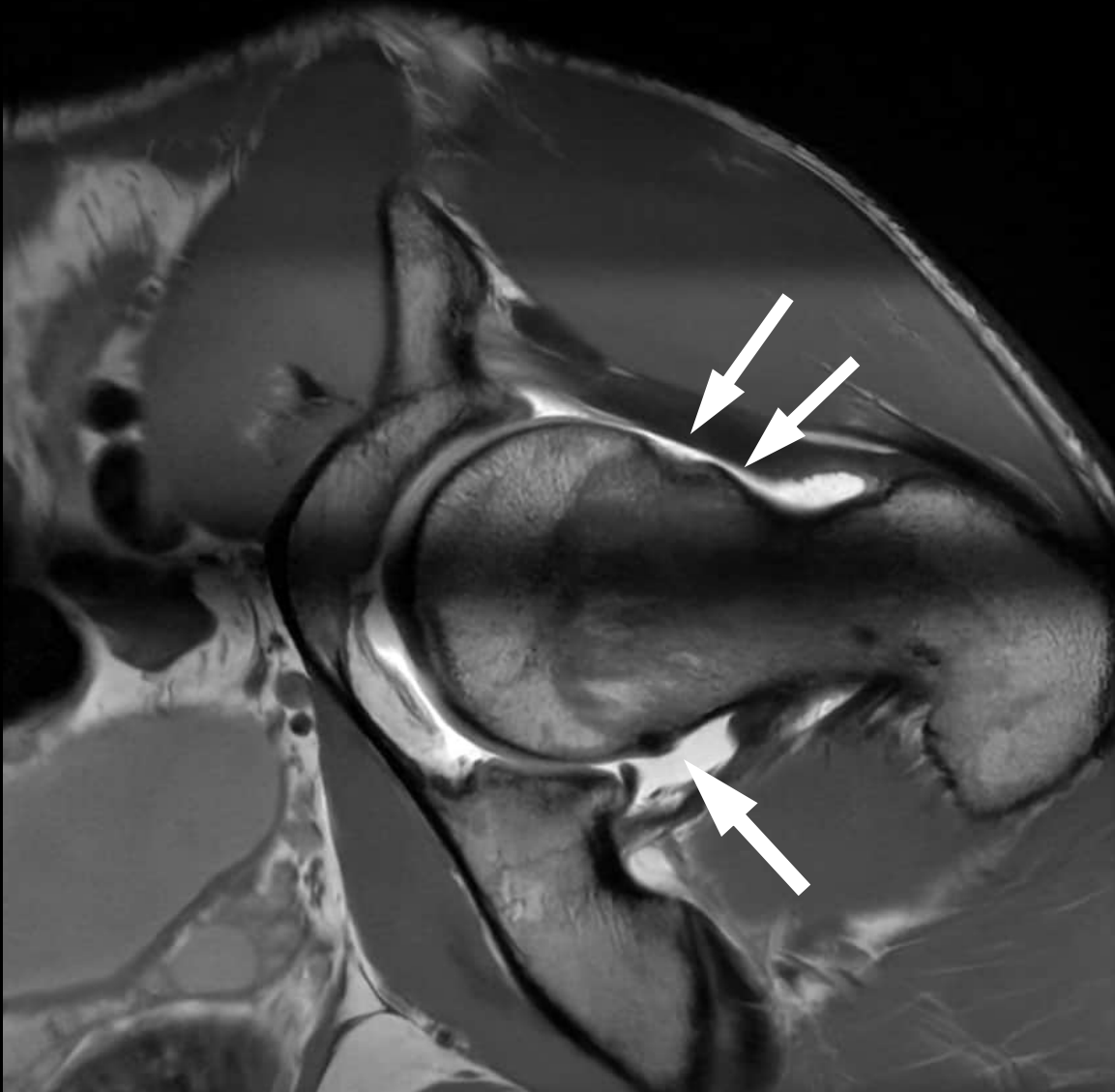

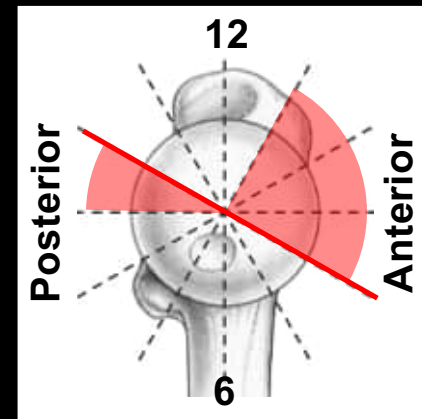
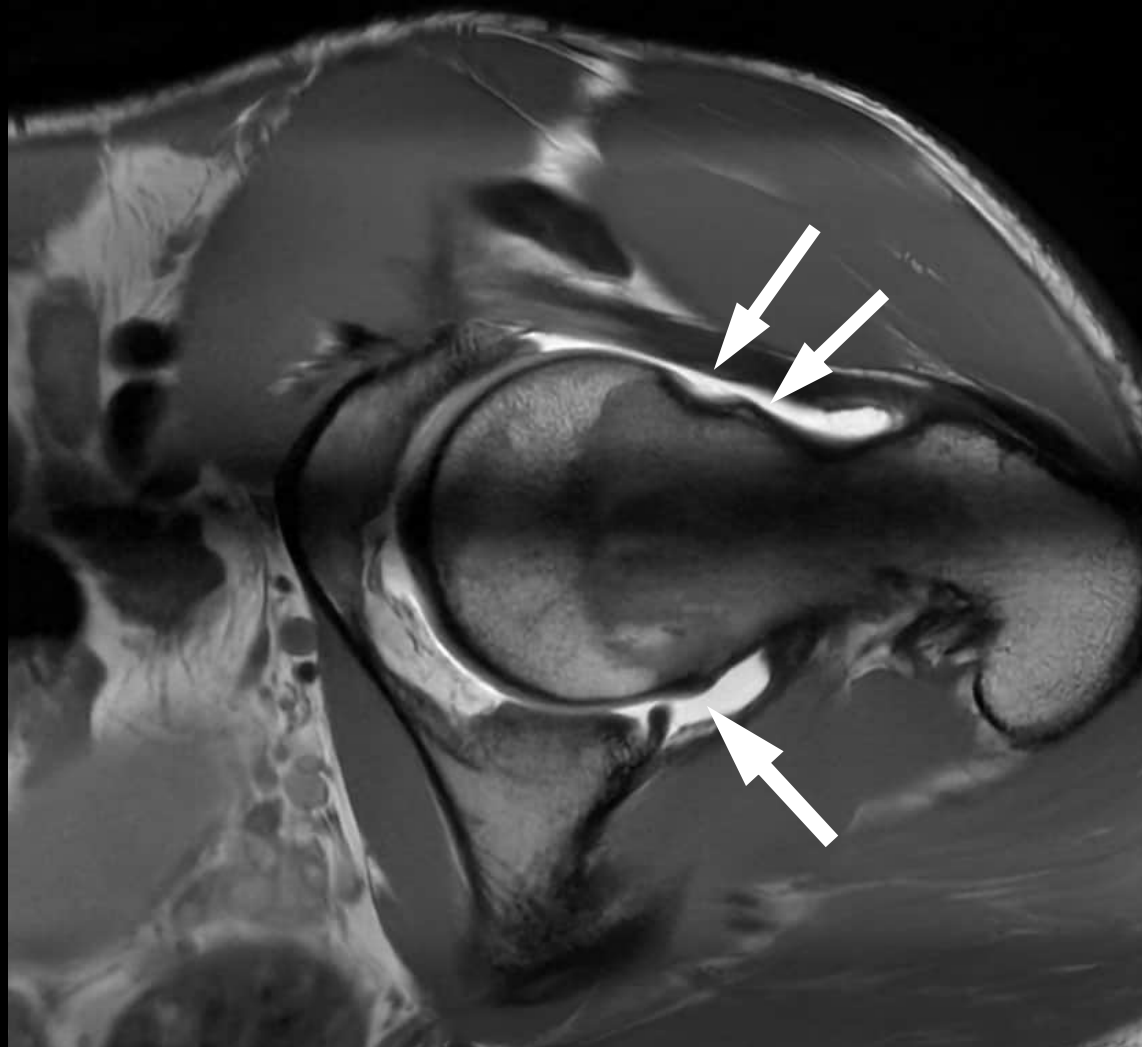
Posterior

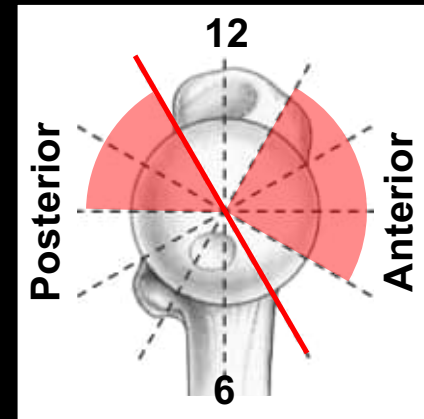
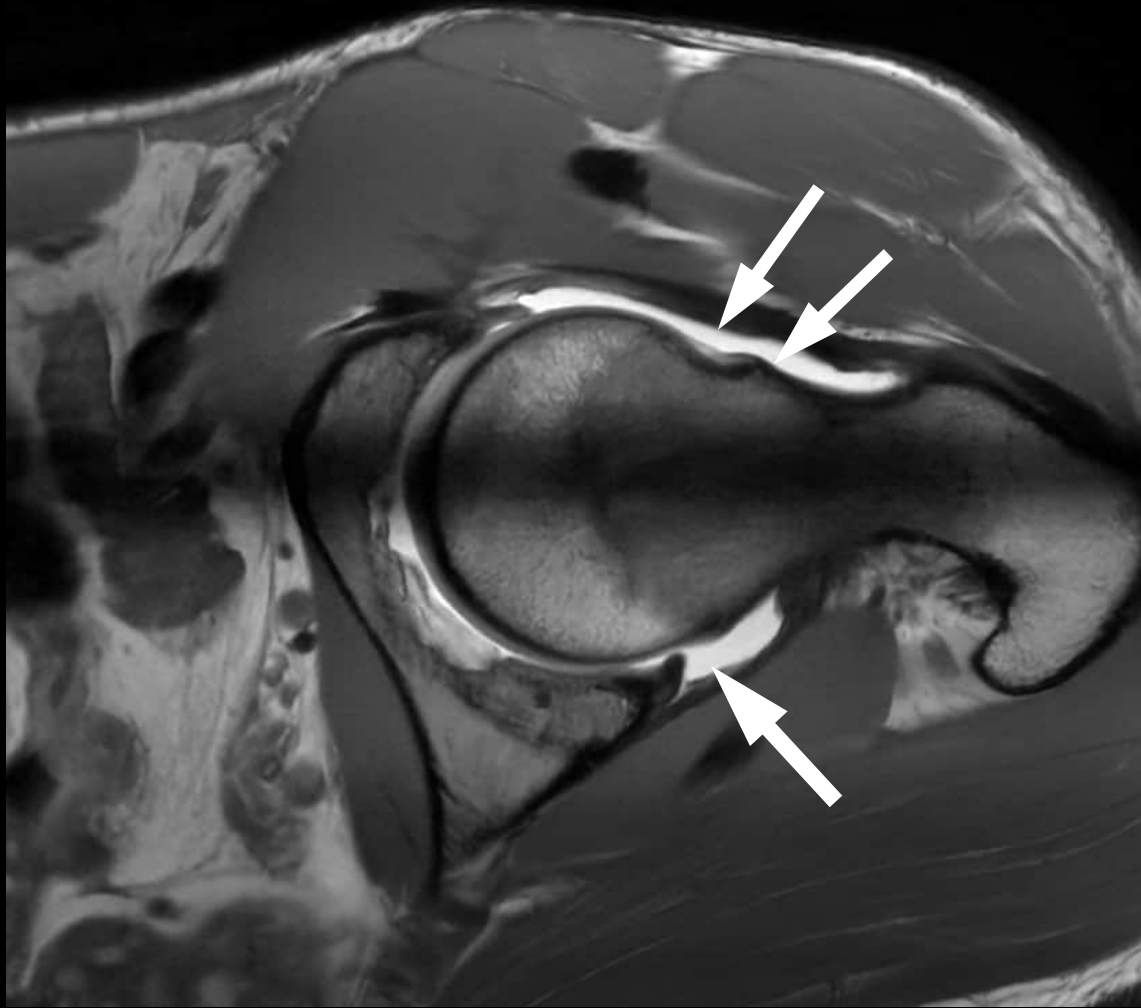


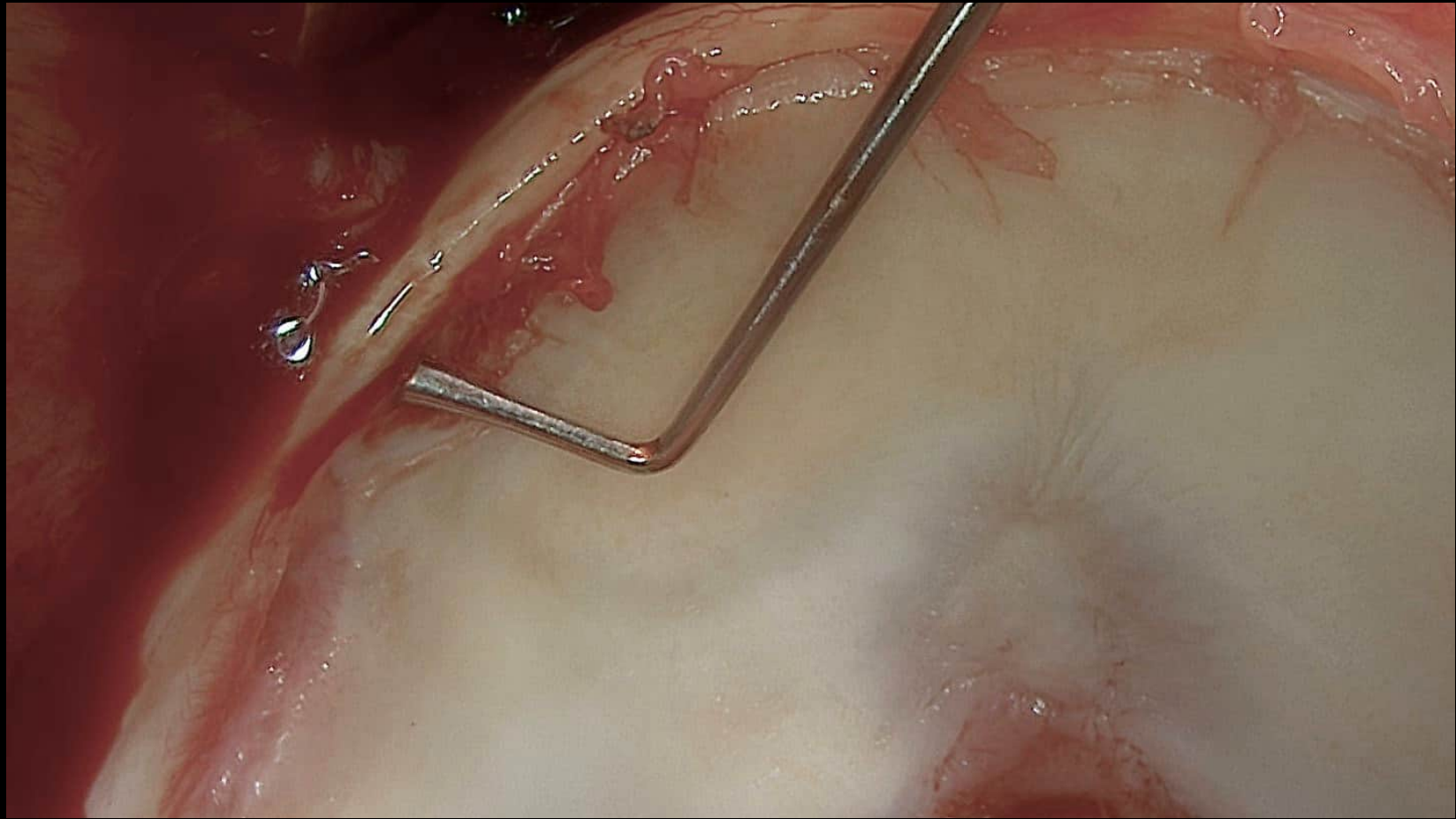


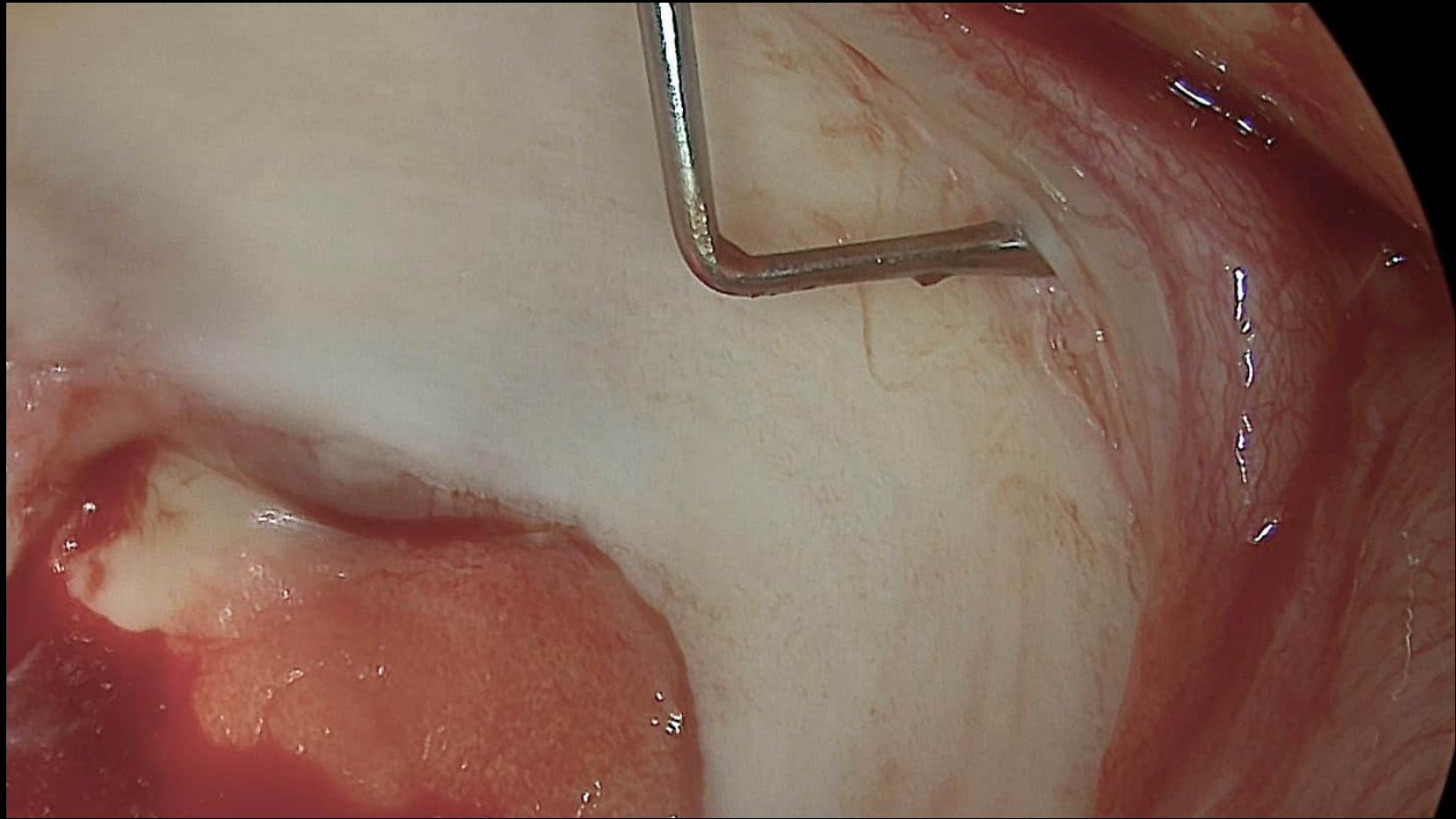


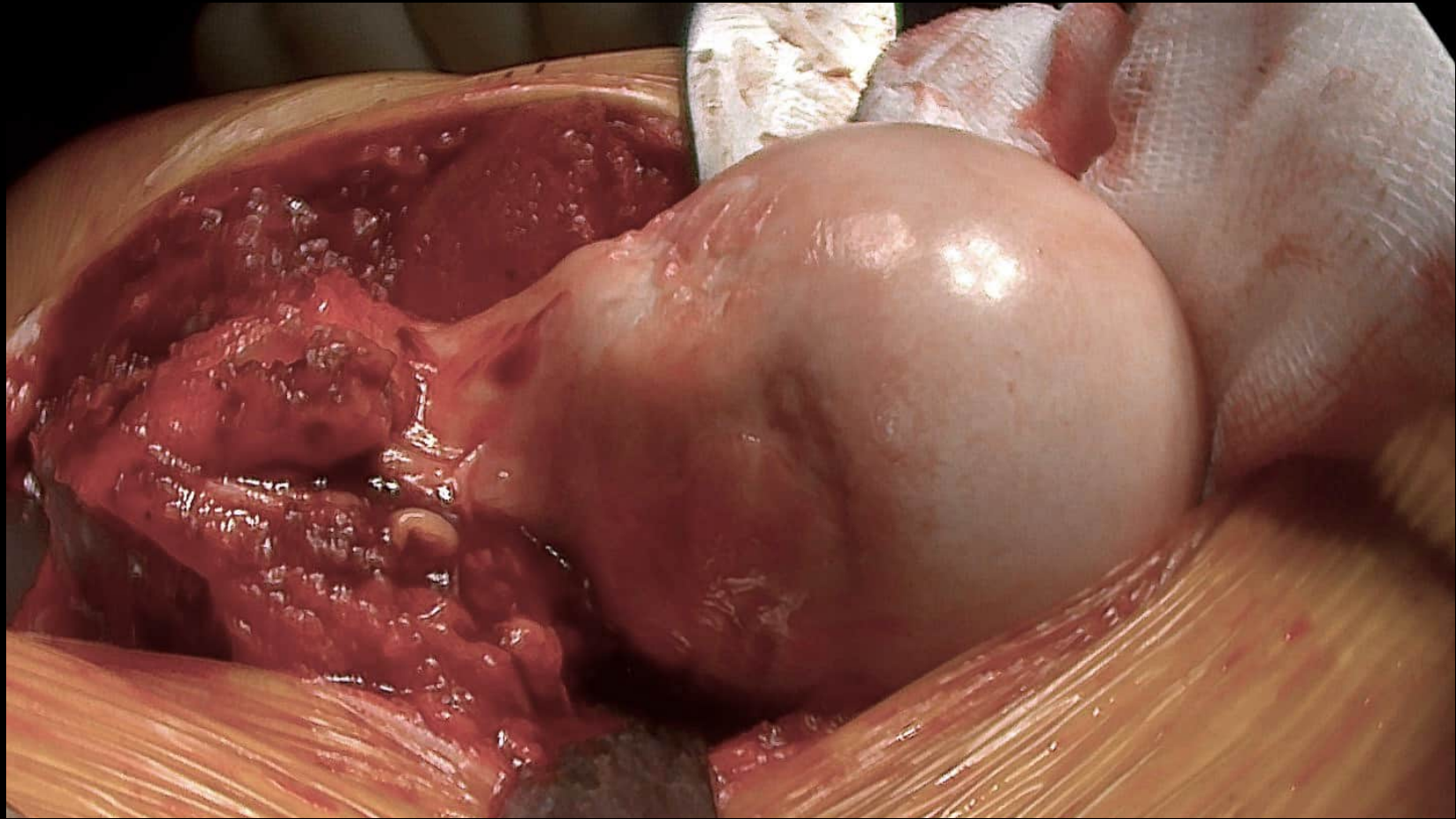


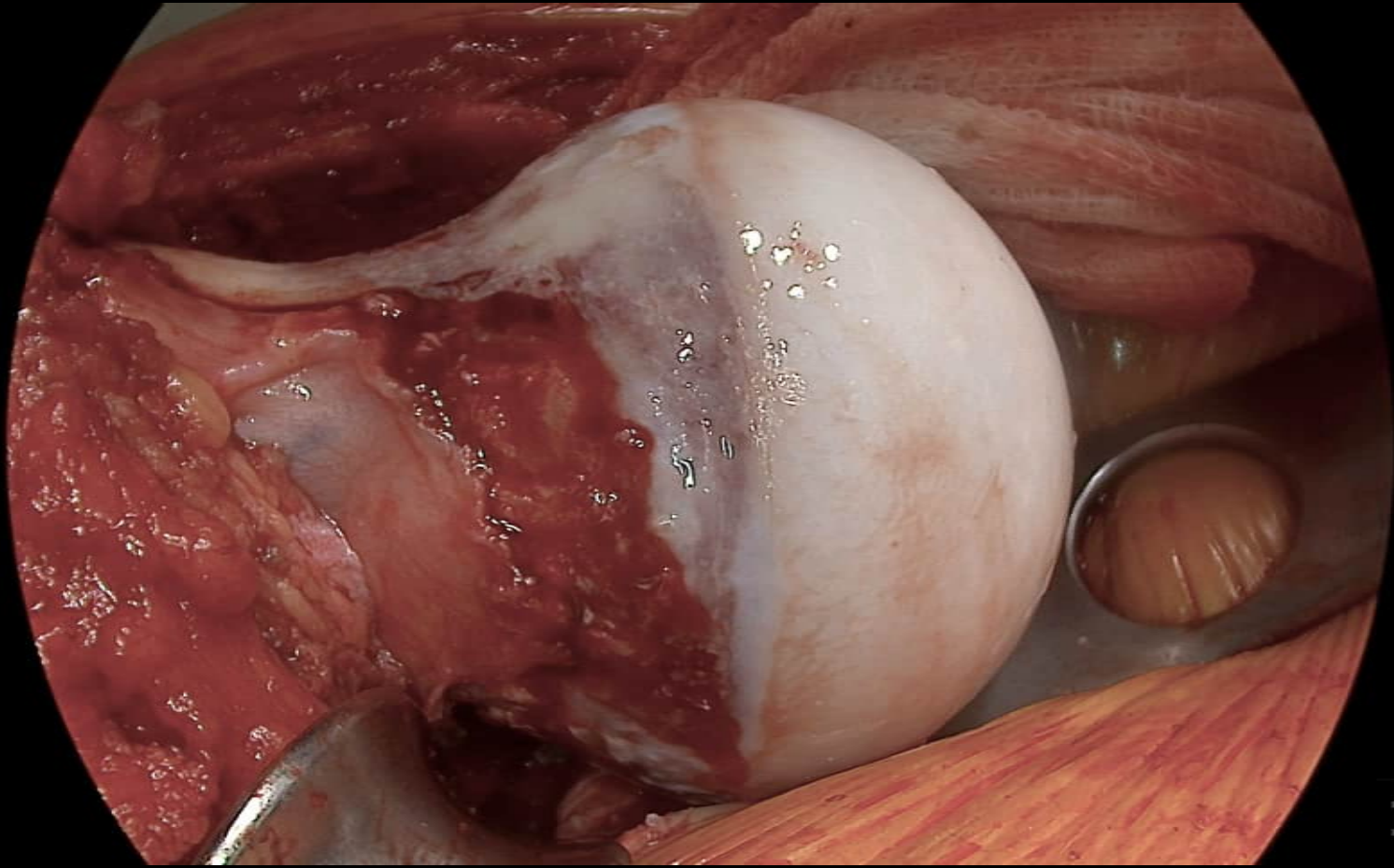


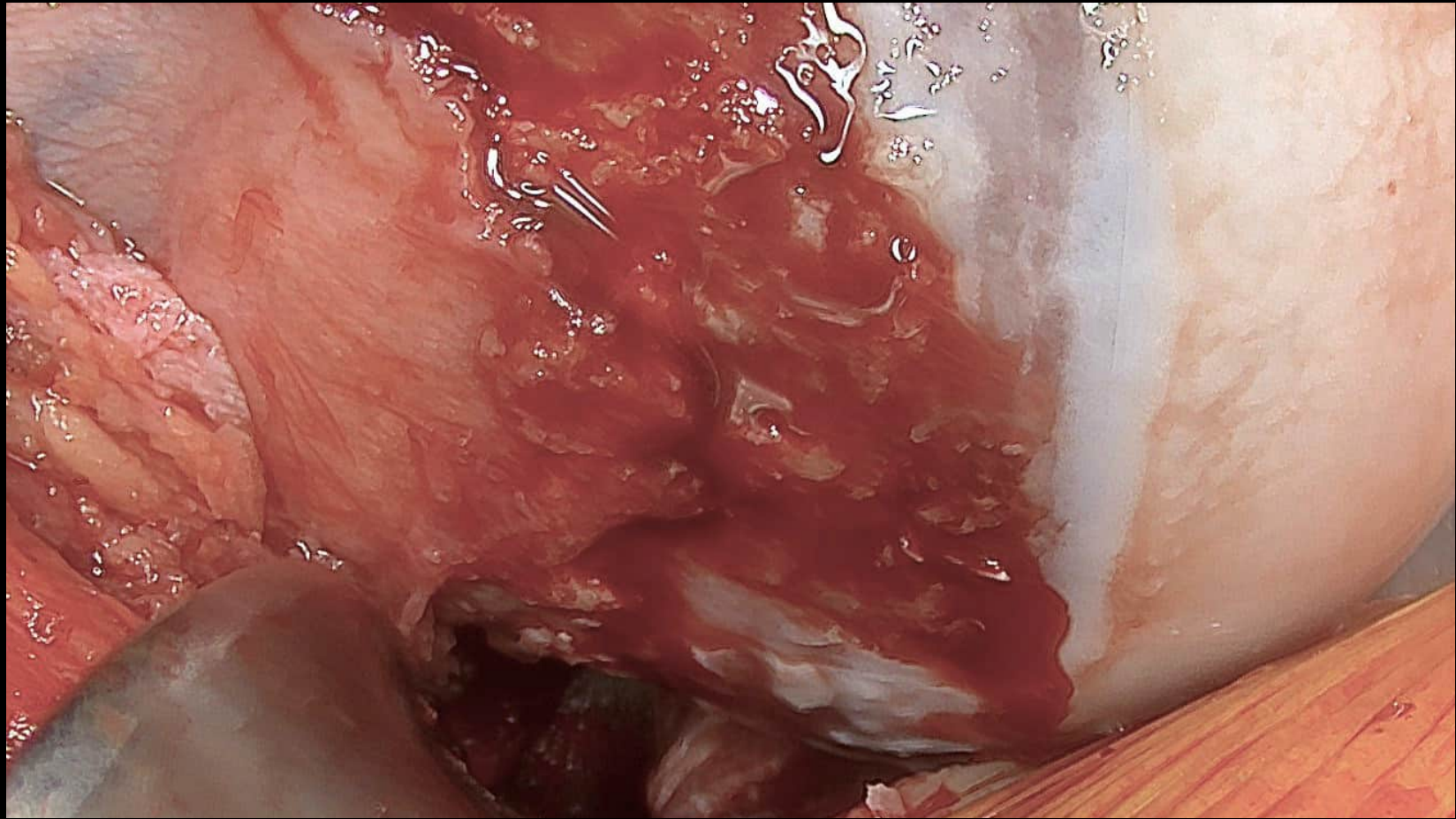


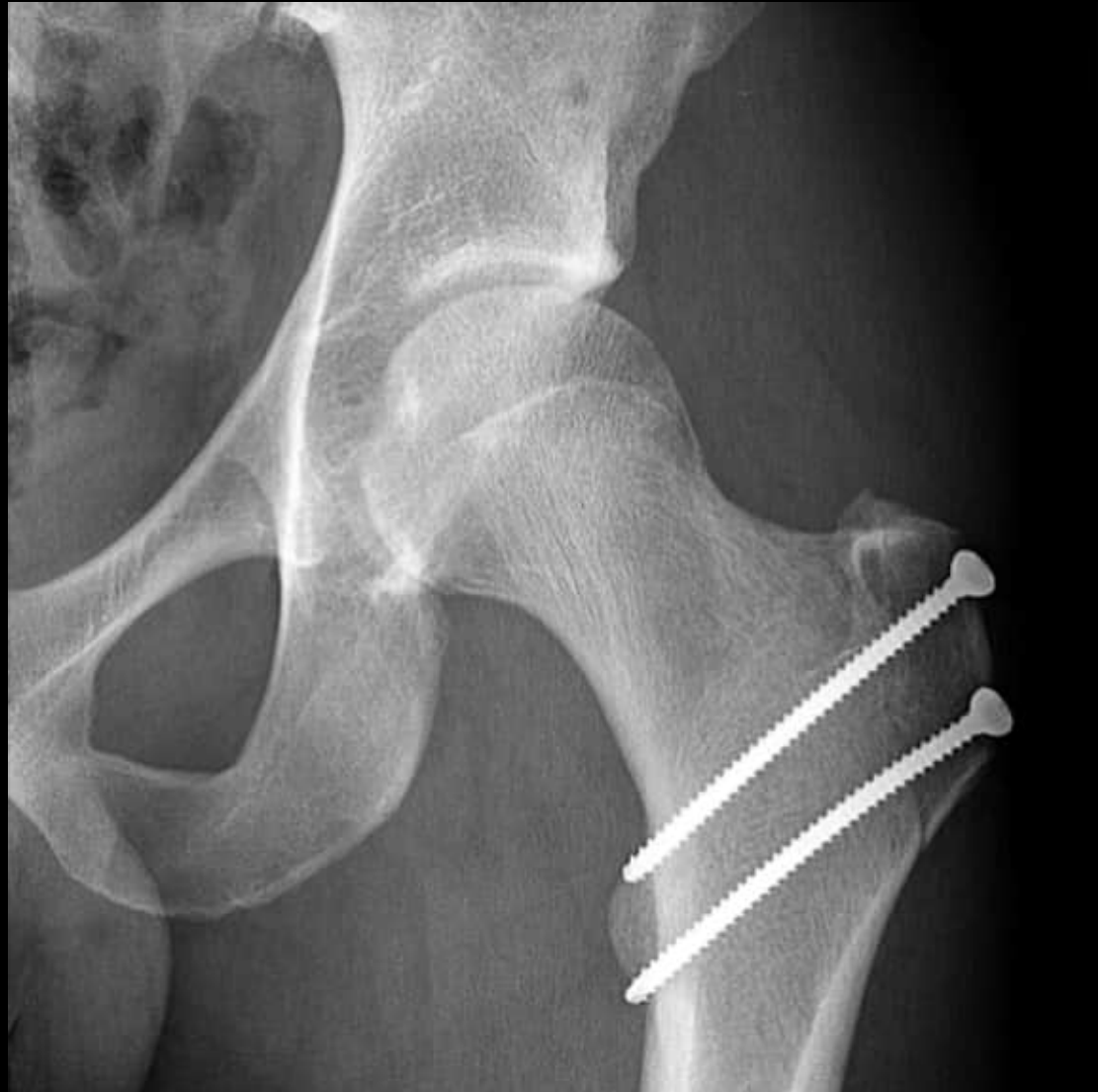





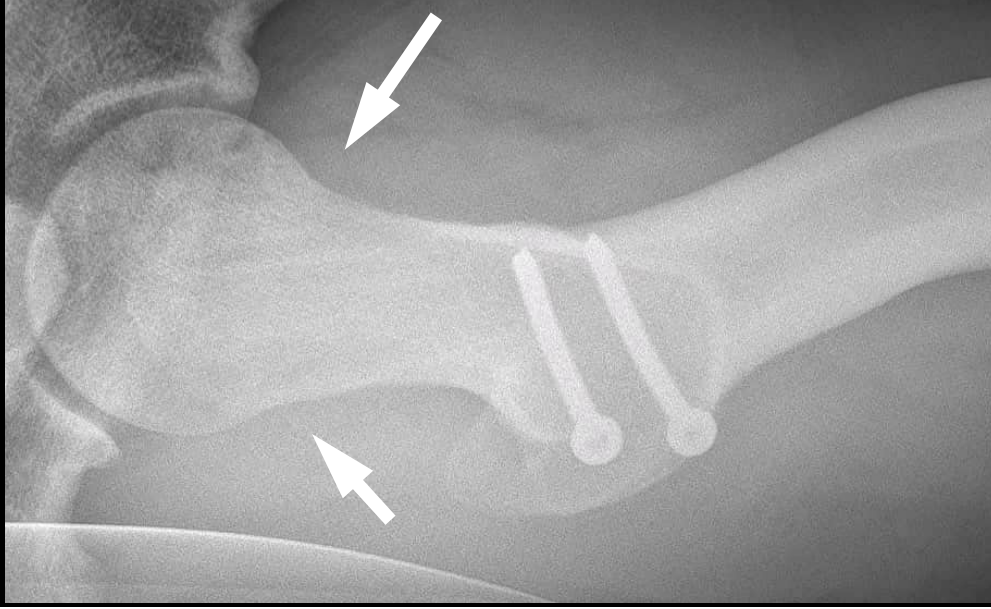





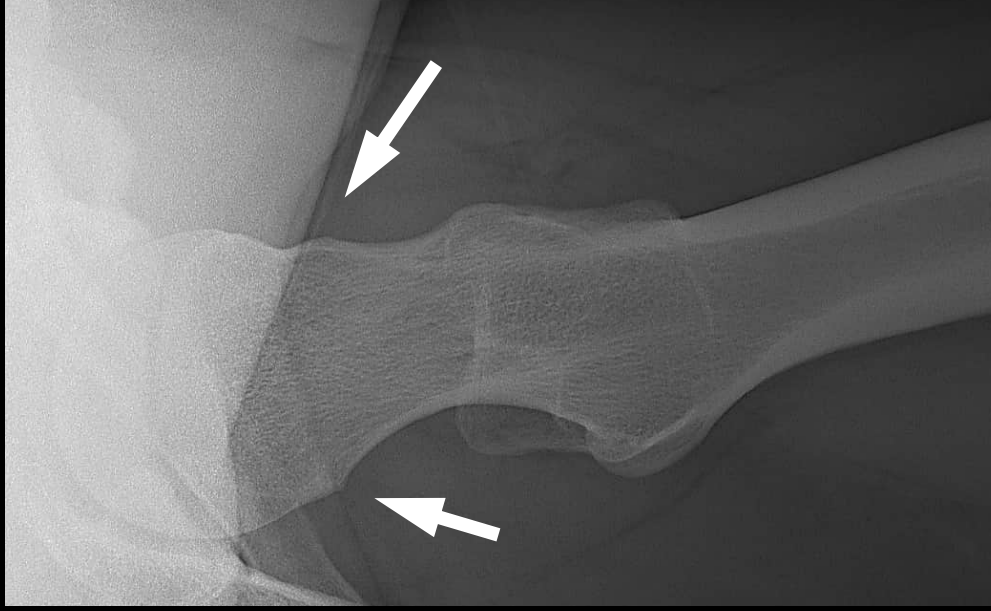
21 year old male patient with hip and buttock pain

Postoperative



Preoperative



u^b

Conclusion

Surgical therapy of cam deformity

- The course of the retinacular vessels must be taken into account.
- Correction of the entire deformity: if not possible arthroscopically, then with open surgery
- Indication depending on location and extension of cam deformity and relation to retinacular vessels