



Back to life:
Systematic overview on results of
joint-preserving hip surgery

K.P. Günther



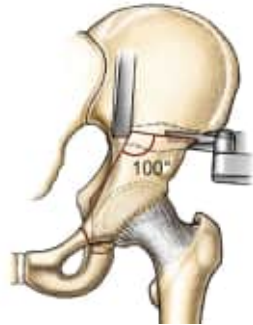LIBERTAS KARLS
UNIVERSITÄT
TÜBINGEN



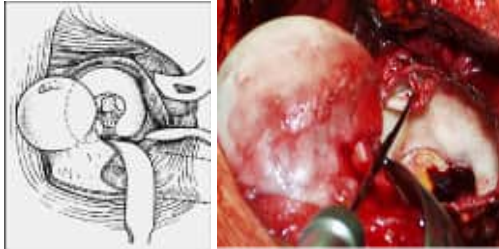
**Universitätsklinikum Tübingen
Orthopädische Klinik**

pelvic osteotomy

➔ **dysplasia**

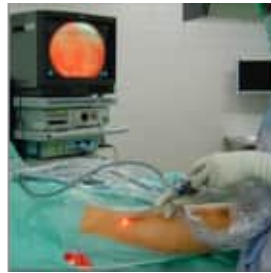

**surgical hip
dislocation**



➔ **FAI**

arthroscopy



**complication
rates**

**survival
rates**

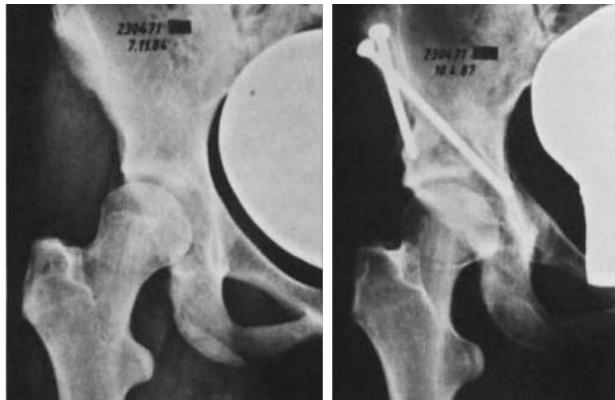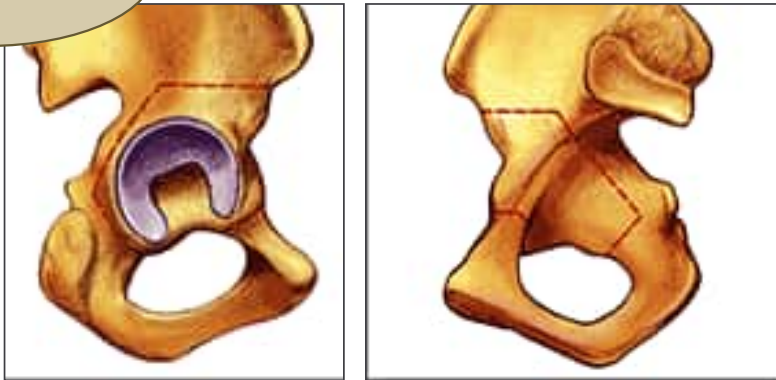↓
**conversion to
arthroplasty**

**function
& QoL
(PROMS)**

Pelvic Osteotomy (hip dysplasia)

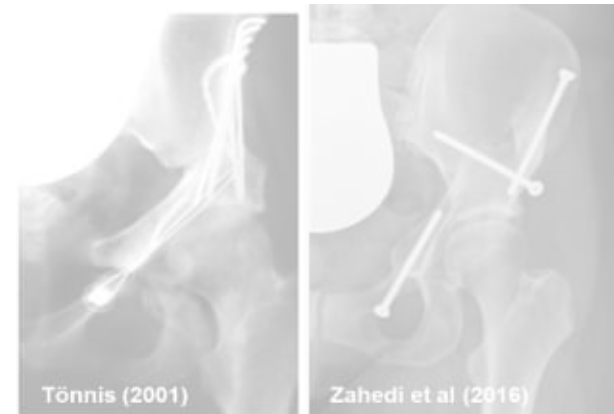
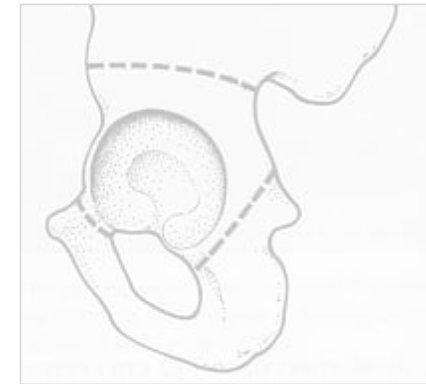
PAO

Clinical Orthopaedics and Related Research Number 232 July, 1988
A New Periacetabular Osteotomy for the Treatment of Hip Dysplasias
Technique and Preliminary Results
REINHOLD GANZ, M.D.,* KAJ KLAUE, M.D.,** THO SON VINH, M.D., Ph.D.,† AND JEFFREY W. MAST, M.D.‡



Triple

Journal of Pediatric Orthopedics
1:241-249 © 1981 Raven Press, New York
A Modified Technique of the Triple Pelvic Osteotomy:
Early Results
D. Tönnis, K. Behrens, and F. Tscharani



Complications of PAO (modified according to Hanke et al 2021 – Sink-Classification)

Complication grade	type	prevalence
1 Without clinical relevance	superficial wound infection heterotopic ossification 1°- 2°	5 % 2 - 15 %
2 Outpatient treatment or medication	paresthesia NCFL paresis N. femoralis paresis N. ischiadicus deep wound infection discontinuity post. column	30 % 2 – 6 % 2 – 7 % 3 – 15 % 2 – 9 %
3 Surgical therapy or hospitalization	DVT / PE heterotopic ossification 3° - 4° revision of non-union revision of hematoma intra-articular osteotomy	3 % 1 – 9 % 1 % 5 % 1 – 16 %
4 THA or life-threatening	necrosis acetabular fragment	4 %



Outcome of PAO - osteotomy survival

Orthopaedics & Traumatology: Surgery & Research 108 (2022) 103283
Hip survivorship following the Bernese periacetabular osteotomy for the treatment of acetabular dysplasia: A systematic review and meta-analysis

Joelle Hwee Inn Tan¹, Si Heng Sharon Tan^{1,2}, Meetrra Seyher Rajoo,
Andrew Kean Seng Lim, James Hoipo Hui

meta-analysis of 24 studies
(3471 patients, 3655 hips)

mean follow-up duration
54.2 mo (range: 1–336 mo)

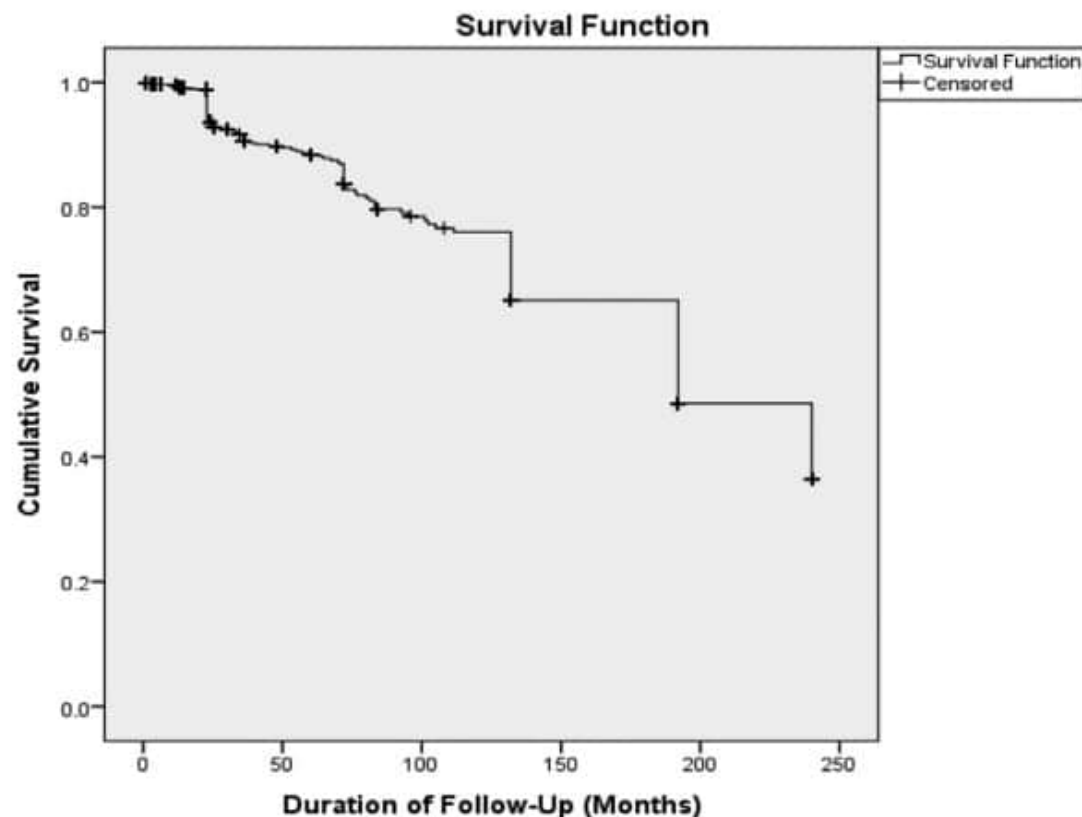


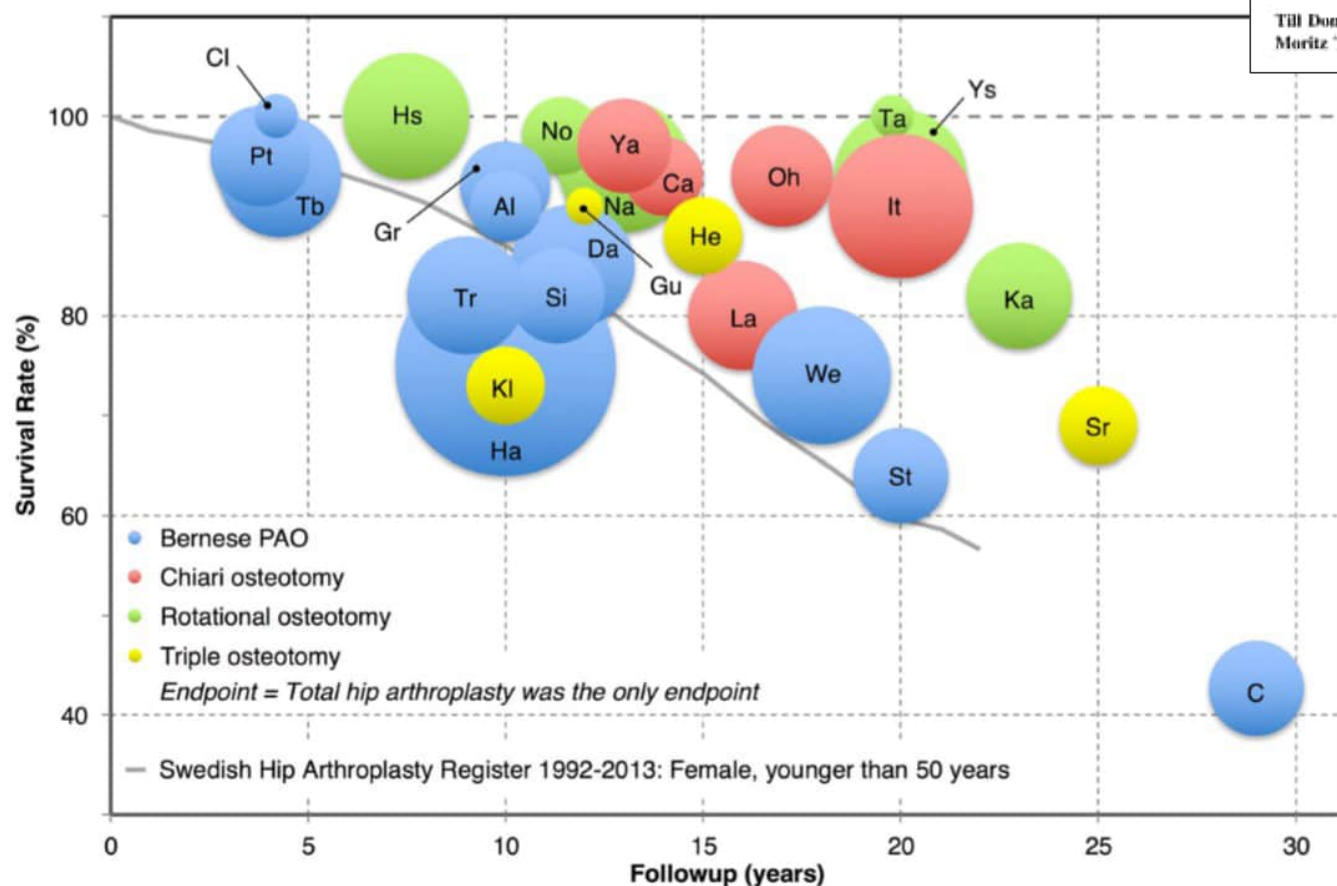
Fig. 2. Kaplan–Meier survivorship curve with conversion to total hip arthroplasty (THA) as an endpoint for 3655 hips following periacetabular osteotomy (PAO).

Outcome of all osteotomies

Clin Orthop Relat Res (2017) 475:1154–1168

One-third of Hips After Periacetabular Osteotomy Survive 30 Years With Good Clinical Results, No Progression of Arthritis, or Conversion to THA

Till Dominic Lerch MD, Simon Damian Steppacher MD, Emanuel Francis Liechti MD, Moritz Tannast MD, Klaus Arno Siebenrock MD




- Al Albers et al (2013)
- Ca Calvert et al (1987)
- Cl Clohisy et al (2005)
- Da Dahl et al (2014)
- Gr Grammatopoulos et al (2016)
- Gu Guille et al (1992)
- Ha Hartig-Andreasen et al (2012)
- He van Hellemond et al (2005)
- Hs Hasegawa et al (2002)
- Kl de Kleuver et al (1997)
- La Lack et al (1991)
- Na Nakamura et al (1998)
- No Nozawa et al (2002)
- Oh Ohashi et al (2000)
- Pd Pedersen et al (2014)
- Pt Peters et al (2006)
- Si Siebenrock et al (1999)
- St Steppacher et al (2008)
- Ta Takatori et al (2001)
- Tb Trumble et al (1999)
- Tr Troelsen et al (2009)
- Ya Yanagimoto et al (2005)
- Ys Yasunaga et al (2004)



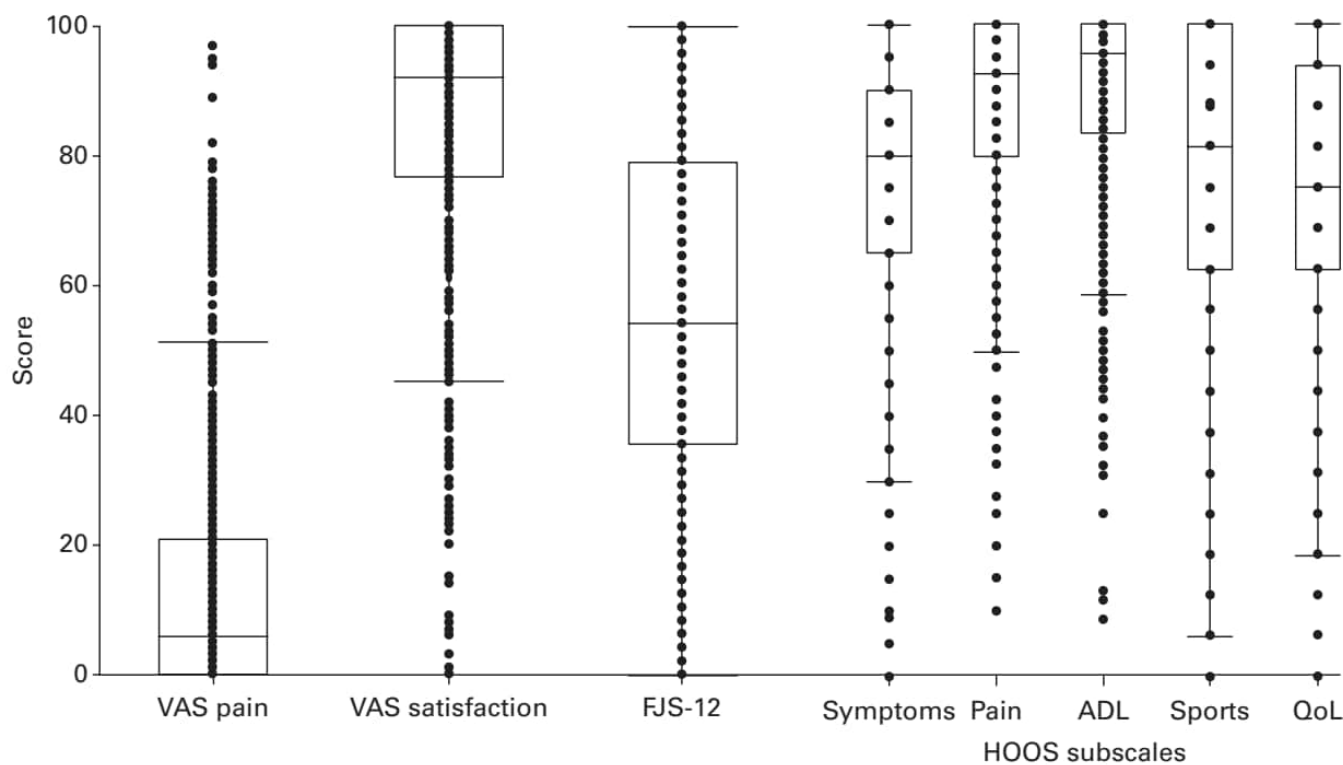
Outcome of PAO - function & PROMS

**transposition
osteotomy
(type of PAO)
686 patients (882 hips)
median f/u 12 y
(IQ range 7 – 16 y)**

 *Bone Joint J*
2023;105-B(7):760–767.

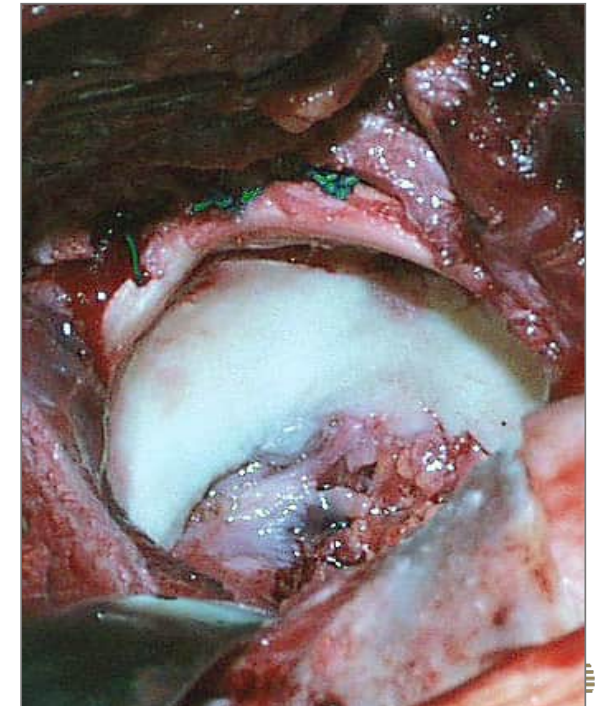
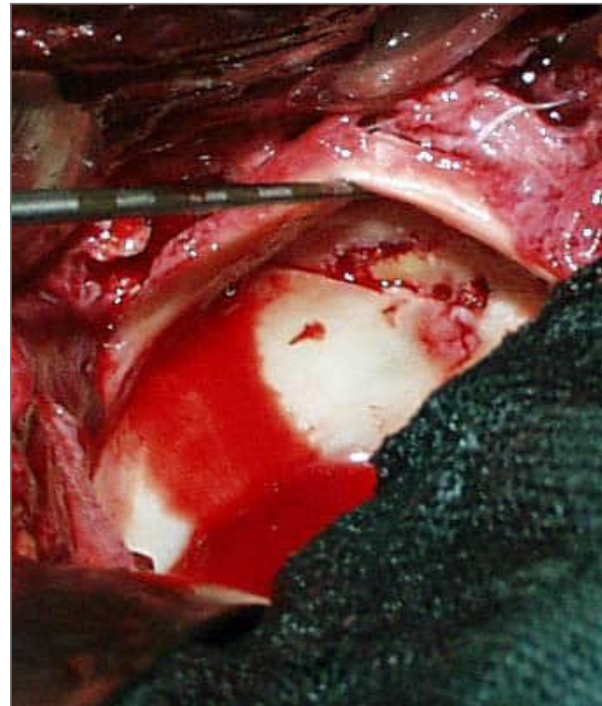
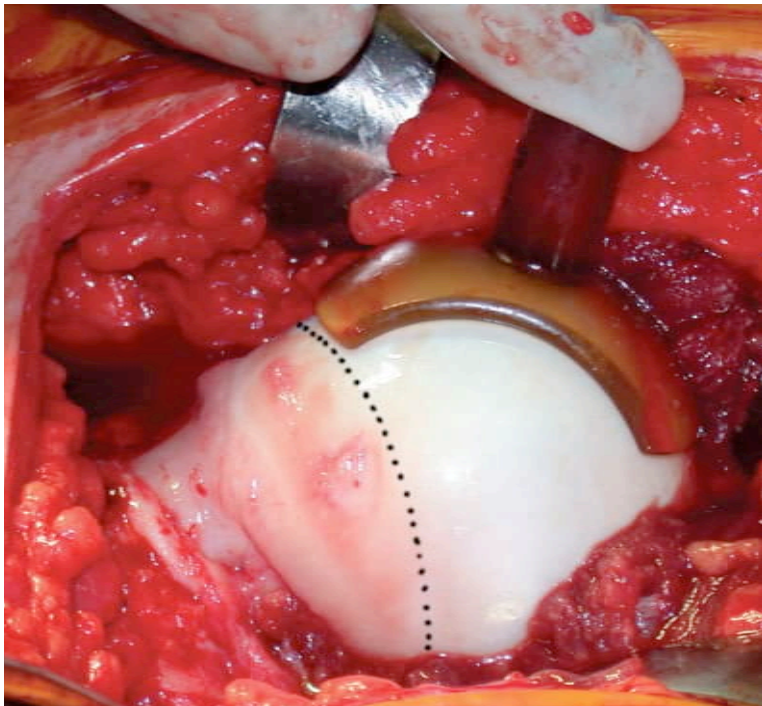
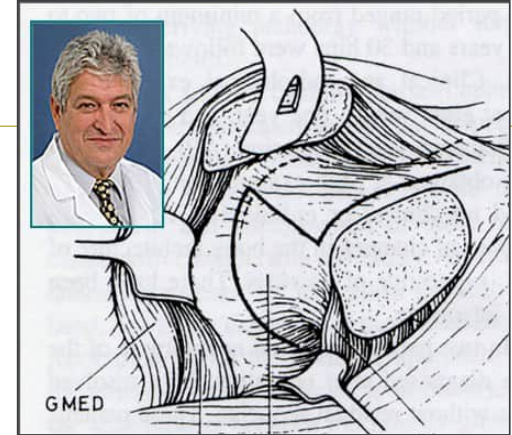
Joint awareness following periacetabular osteotomy in patients with hip dysplasia

S. Tanaka,
M. Fujii,
S. Kawano,
M. Ueno,
M. Sonohata,
M. Kitajima,
D. Mawatari,
M. Mawatari



Surgical hip dislocation (SHD) ➡ mainly in FAI

Ganz et al 2001



Complications of SHD (modified according to Hanke et al 2021 – Sink-Classification)

Complication grade	type	prevalence
1 Without clinical relevance	superficial wound infection bursitis trochanterica heterotopic ossification 1° - 2°	1 % 13 % 5 %
2 Outpatient treatment or medication	partial neurapraxia	0 - 2 %
3 Surgical therapy or hospitalization	heterotopic ossification 3° - 4° trochanteric fixation failure revision of hematoma removal of trochanteric screws arthroscopic adhesiolysis revision of IT band dehiscence	1 % 1 – 2 % 2 % 25 – 65 % 6 %

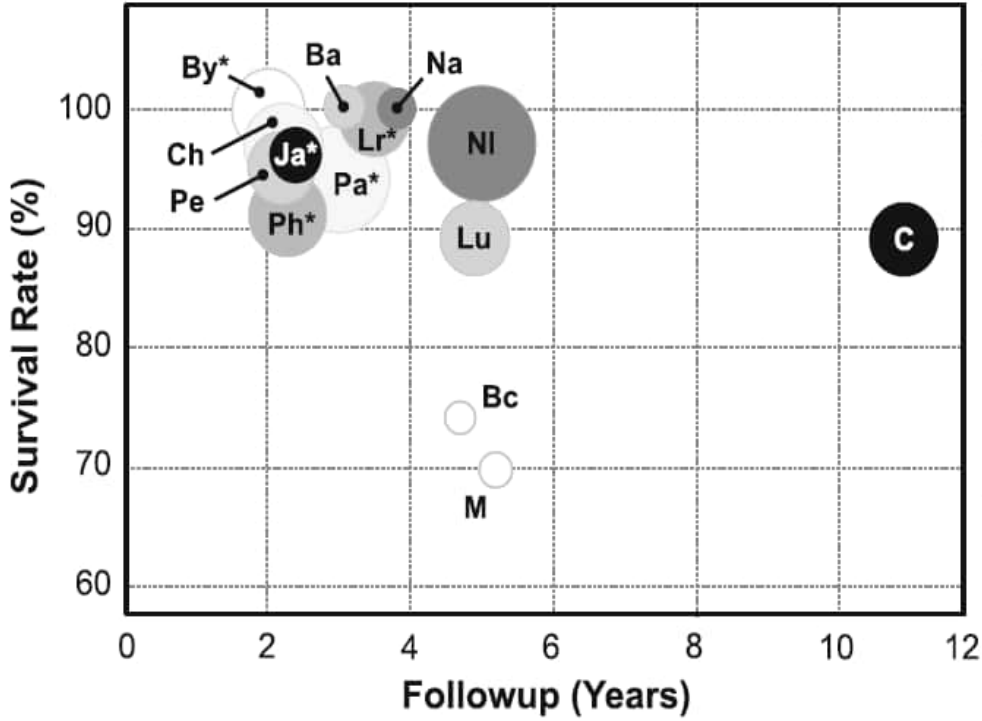
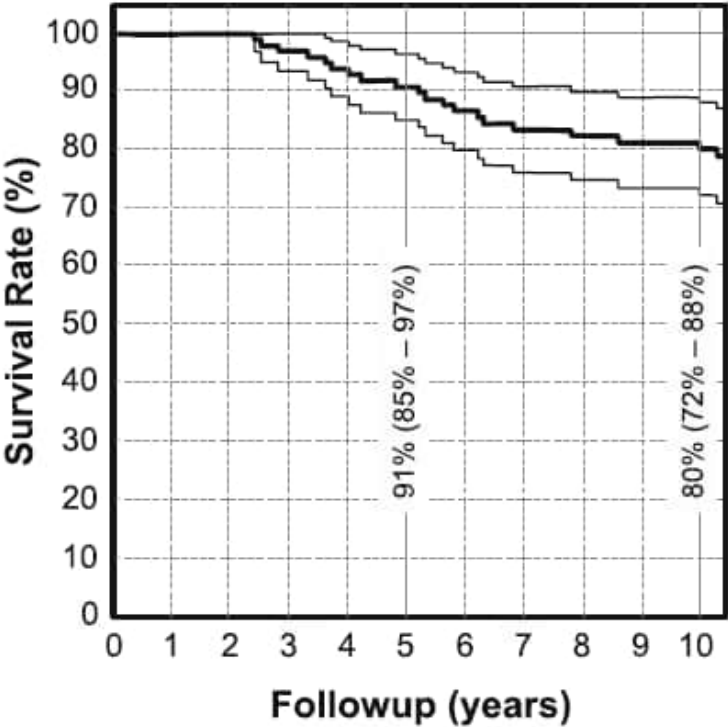


Outcome of SHD - survival

Eighty Percent of Patients With Surgical Hip Dislocation for Femoroacetabular Impingement Have a Good Clinical Result Without Osteoarthritis Progression at 10 Years

Simon D. Steppacher MD, Helen Anwander MD,
 Corinne A. Zurmühle MD, Moritz Tannast MD,
 Klaus A. Siebenrock MD

Clin Orthop Relat Res (2015) 473:



- Bc** Beck et al, 2004 [3]
 - M** Murphy et al, 2004 [26]
 - Ba** Beaulé et al, 2007 [2]
 - Lu** Laude et al, 2009 [20]
 - Ph*** Philippon et al, 2009 [31]
 - Pe** Peters et al, 2010 [30]
 - By*** Byrd and Jones, 2011 [6]
 - Na** Naal et al, 2011 [28]
 - Ch** Chiron et al, 2012 [7]
 - Lr*** Larson et al, 2012 [19]
 - NI** Naal et al, 2012 [27]
 - Pa*** Palmer et al, 2012 [29]
 - Ja*** Jackson et al, 2014 [15]
 - C** Current Study
- * Arthroscopic Surgery

Outcome of SHD - function & PROMS

Eighty Percent of Patients With Surgical Hip Dislocation for Femoroacetabular Impingement Have a Good Clinical Result Without Osteoarthritis Progression at 10 Years

Simon D. Steppacher MD, Helen Anwander MD,
Corinne A. Zurmühle MD, Moritz Tannast MD,
Klaus A. Siebenrock MD

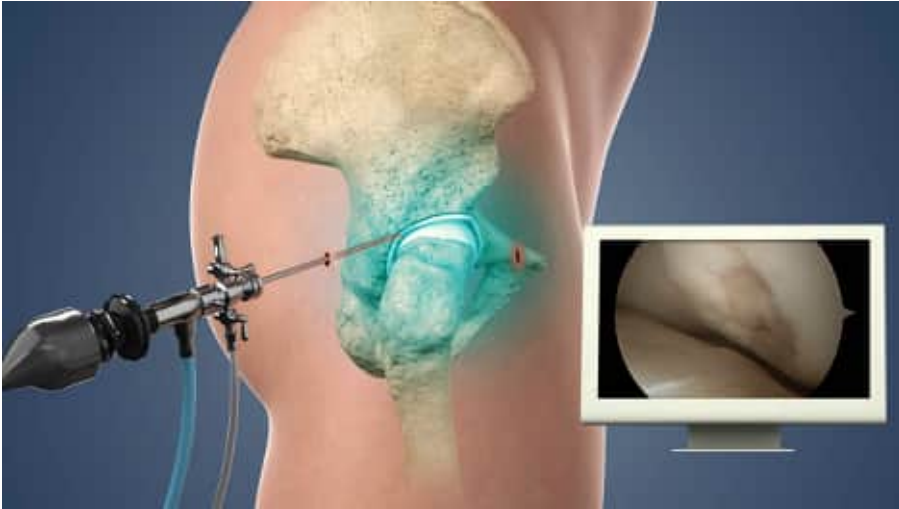Clin Orthop Relat Res (2015) 473:

**75 patients (97 hips)
SHD 2001 - 2003
Mean f/u 11 y (10–13)**

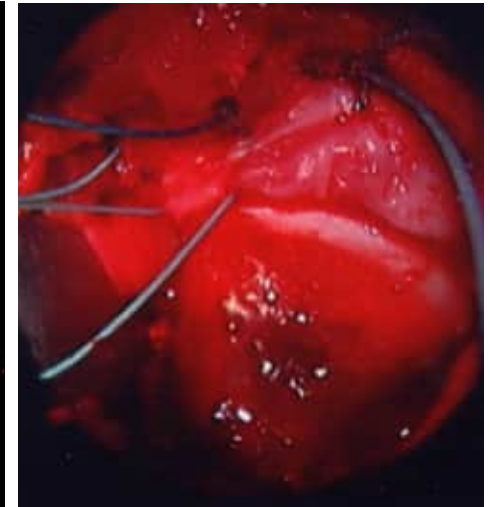
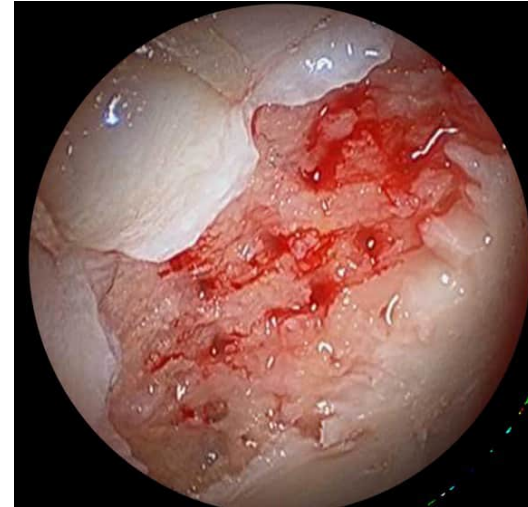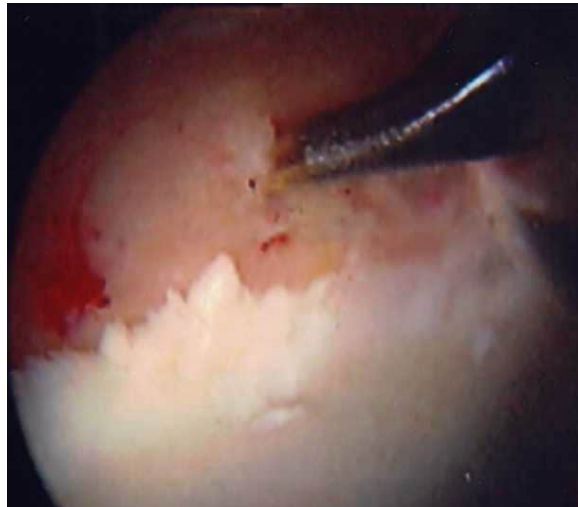
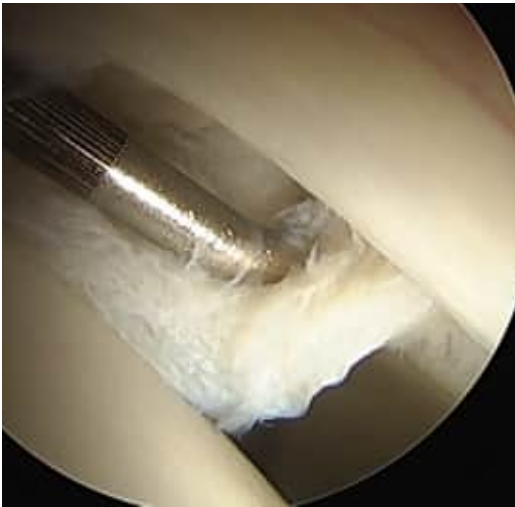Parameter (best-worst score possible)	Preoperative (n = 97)	5-year followup (n = 90)	10-year followup (n = 86)
WOMAC [4] (0–100)	–	8 ± 12 (0–52)	6 ± 11 (0–59)
Harris hip score [11] (100–0)	–	92 ± 12 (48–100)	92 ± 10 (44–100)
SF-12 [9, 33]			
Physical component Scale (100–0)	–	50 ± 8 (20–65)	52 ± 7 (24–61)
Mental component Scale (100–0)	–	54 ± 8 (21–67)	52 ± 10 (20–63)
UCLA score [34] (10–0)	–	7 ± 2 (2–10)	8 ± 2 (2–10)



Arthroscopy ➡ mainly in FAI



<https://www.hss.edu/health-library/conditions-and-treatments/list/hip-arthroscopy>



Complications of ASC (modified according to Hanke et al 2021 – Sink-Classification)

Complication grade	type	prevalence
1 Without clinical relevance	superficial wound infection heterotopic ossification 1° - 2° instrument breakage iatrogenic chondral / labral injury hypothermia	< 1 % 1 - 6 % < 1% 3 % / 1-20 % 3 %
2 Outpatient treatment or medication	temporary / permanent nerve injury perineal skin damage deep wound infection DVT	2-7 % / < 1 % < 1 % < 1 % 1 – 4 %
3 Surgical therapy or hospitalization	heterotopic ossification 3° - 4° femoral neck fracture scrotal skin necrosis AVN extraarticular fluid extravasion	< 1 % < 1 % < 1 % < 1 % 1 %



Outcome of ASC - survival

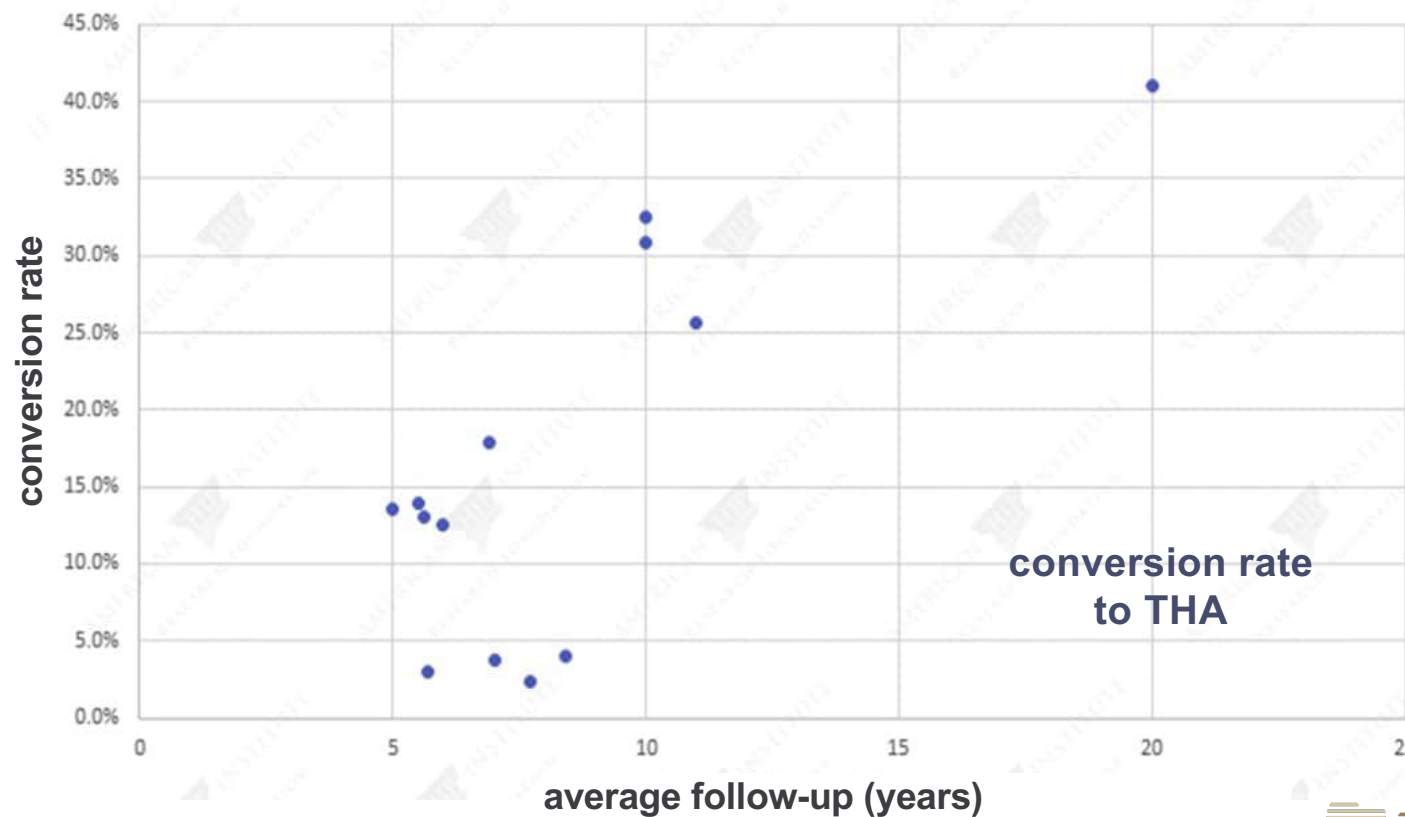
Arthroscopy. 2021 Mar;37(3):1011-1025

**Mid- to Long-Term Outcomes of Hip Arthroscopy:
A Systematic Review**

Cynthia Kyin, B.A., David R. Maldonado, M.D., Camille C. Go, B.S., Jacob Shapira, M.D.,
Ajay C. Lall, M.D., M.S., and Benjamin G. Domb, M.D.



systematic review
13 studies (1571 hips)
f/u 5 – 20y



Outcome of ASC - function & PROMS

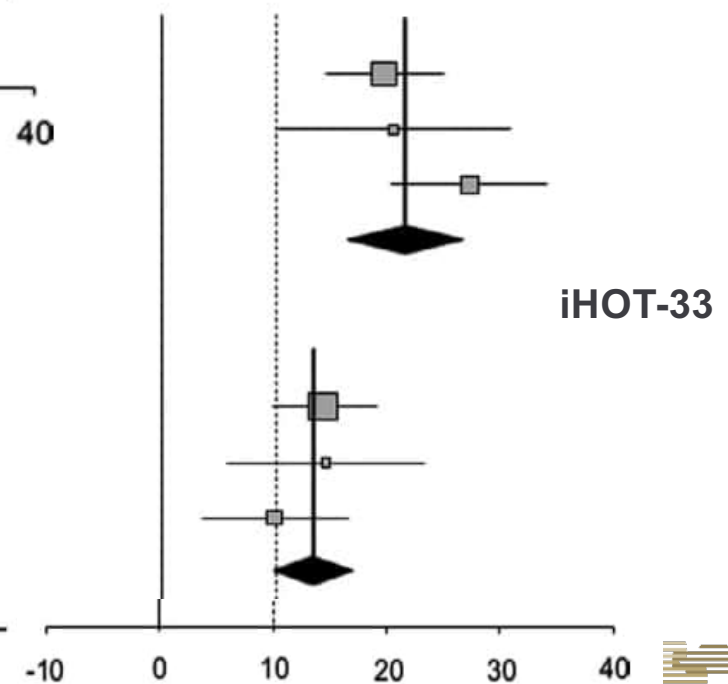
BRIEF REPORT

Effectiveness of Hip Arthroscopy on Treatment of Femoroacetabular Impingement Syndrome: A Meta-Analysis of Randomized Controlled Trials

Nicola C. Casartelli,¹ Pedro L. Valenzuela,² Nicola A. Maffioletti,³ and Michael Leunig¹

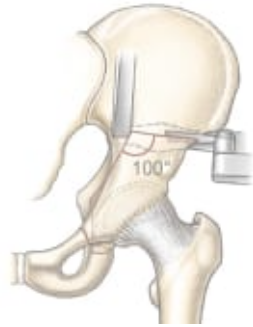Changes in iHOT-33 score from baseline to follow-up

Study	Baseline		Follow-up		Weight	MD (95% CI)	P value
	Mean ± SD	n	Mean ± SD	n			
Hip arthroscopy							
Griffin et al. 2018	39.2 ± 20.9	171	58.8 ± 18.1	171			
Mansell et al. 2018	28.5 ± 15.5	37	48.9 ± 10.0	37			
Palmer et al. 2019	35.2 ± 21.9	112	62.4 ± 28.4	93	34%	27.2 (20.3 - 34.1)	<0.001
Total					100%	22.3 (17.3 - 27.4)	<0.001
Heterogeneity: Q=3.09, I ² =35%; Publication bias: Begg's P=1.000							
Physical therapy							
Griffin et al. 2018	35.6 ± 18.2	177	49.7 ± 25.0	163	56%	14.1 (9.5 - 18.7)	<0.001
Mansell et al. 2018	29.4 ± 15.5	37	43.9 ± 22.0	37	16%	14.5 (5.8 - 23.2)	0.001
Palmer et al. 2019	35.7 ± 21.4	110	45.5 ± 25.2	86	28%	9.8 (3.3 - 16.3)	0.003
Total					100%	13.0 (9.5 - 16.4)	<0.001
Heterogeneity: Q=1.25, I ² =0%; Publication bias: Begg's P=1.000							

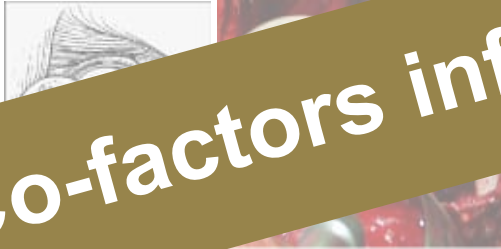

pelvic osteotomy

→ dysplasia

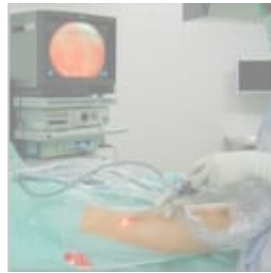

surgical hip
dislocation



→ FA

arthroscopy



Co-factors influencing the outcome

rates

rates

↓
conversion to
arthroplasty

function
& QoL
(PROMS)

Co-factors influencing outcome in hip preservation surgery

- **cartilage degeneration (osteoarthritis)**
- **lesions of labrum**
- **patient age**
- **comorbidities**
- **surgeon experience**
- **...**

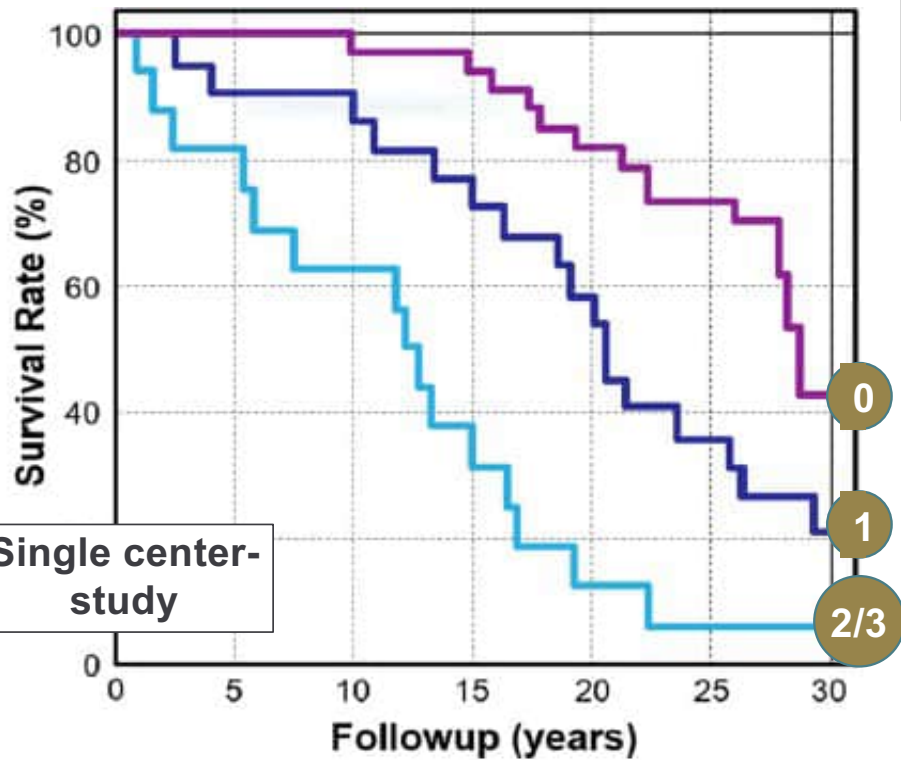


Osteoarthritis (osteotomy)

Clin Orthop Relat Res (2017) 475:1154–1168

One-third of Hips After Periacetabular Osteotomy Survive 30 Years With Good Clinical Results, No Progression of Arthritis, or Conversion to THA

Till Dominic Lerch MD, Simon Damian Steppacher MD, Emanuel Francis Liechti MD, Moritz Tannast MD, Klaus Arno Siebenrock MD

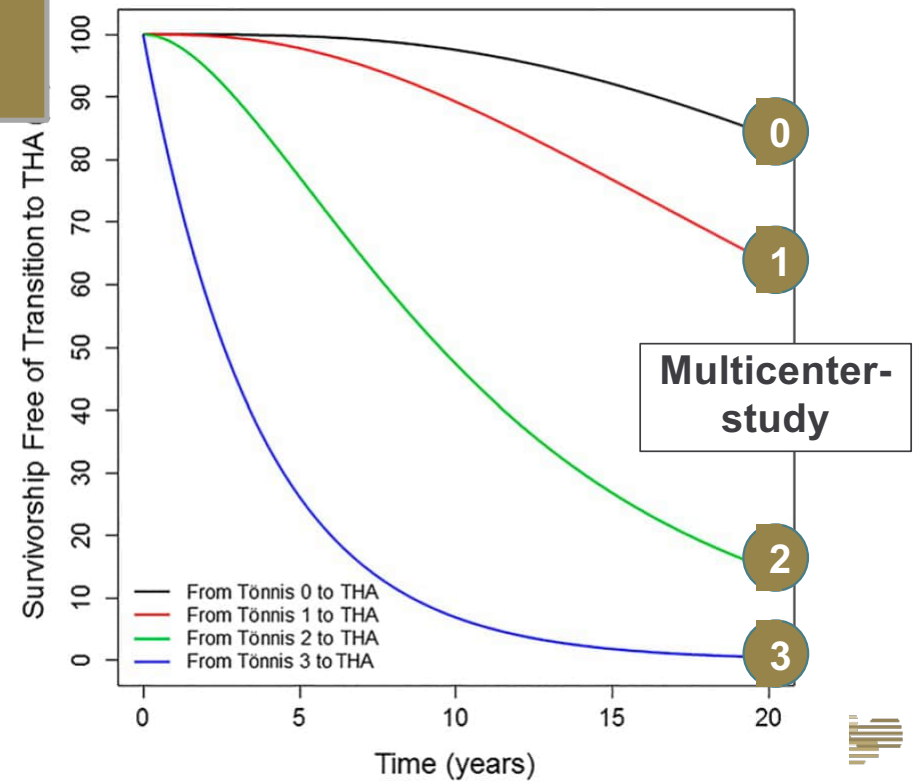


Tönnis-grading of OA

J Bone Joint Surg Am. 2019;101:932-8

Natural History of the Dysplastic Hip Following Modern Periacetabular Osteotomy

Cody C. Wyles, MD, Juan S. Vargas, MD, Mark J. Heidenreich, MD, Kristin C. Mara, MS, Christopher L. Peters, MD, John C. Clohisey, MD, Robert T. Trousdale, MD, and Rafael J. Sierra, MD



Multicenter-study



Osteoarthritis (SHD & AS in FAI)

Authors	OP	n	f/u(y)	correlation OA-grade & outcome (survival)
Gedouin (2010)	AS	100		OA grade 1 bad predictor
Steppacher (2015)	SHD	72	10	Tönnis <grade 1 bad predictor
Sitterlee (2017)	SHD	43	4	OA bad predictor
Sogbei (2019)	meta-analysis			Tönnis 2 and JSN <2mm are bad predictors
Büchler (2021)	AS	63	10	Tönnis 1 bad predictor
Andronic (2022)	meta-analysis			mixed outcomes in Tönnis >2
Sivasundaram (2022)	AS	50	5	Tönnis 0 better than Tönnis 1
Filan (2023)	AS	53	10	58% survival in Tönnis 2
Lee (2023)	meta-analysis			„chondral damage is a predictor of failure“
Lerch (2023)	AS	107	3,5	MRI degeneration bad predictor
Ruzbarski (2023)	AS	782	4,2	JSN bad predictor, no strict 2mm-rule

(Studien 2016-2024)



Patient age (osteotomy)

Clin Orthop Relat Res (2017) 475:1154–1168

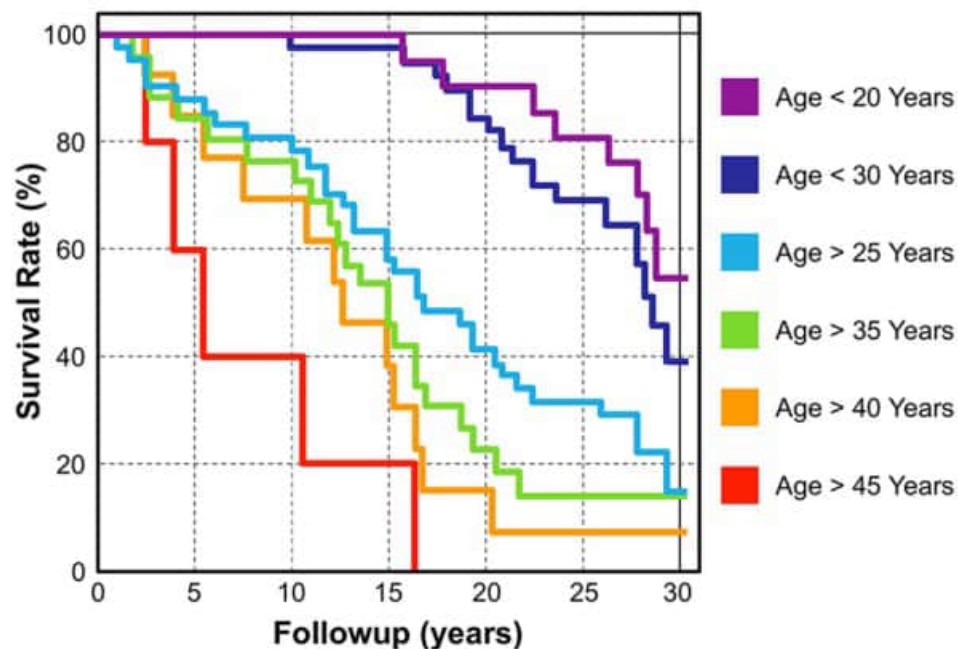
One-third of Hips After Periacetabular Osteotomy Survive 30 Years With Good Clinical Results, No Progression of Arthritis, or Conversion to THA

Till Dominic Lerch MD, Simon Damian Steppacher MD, Emanuel Francis Liechti MD, Moritz Tannast MD, Klaus Arno Siebenrock MD

Clin Orthop Relat Res (2017) 475:396–405

Survivorship of the Bernese Periacetabular Osteotomy: What Factors are Associated with Long-term Failure?

Joel Wells MD, MPH, Michael Millis MD, Young-Jo Kim MD, PhD, Evgeny Bulat MA, Patricia Miller MS, Travis Matheny MD



“Age older than 25 years at the time of PAO (OR 3.6; 95% CI, 1.3–9.8; p = 0.01) and ... were associated with long-term failure...”

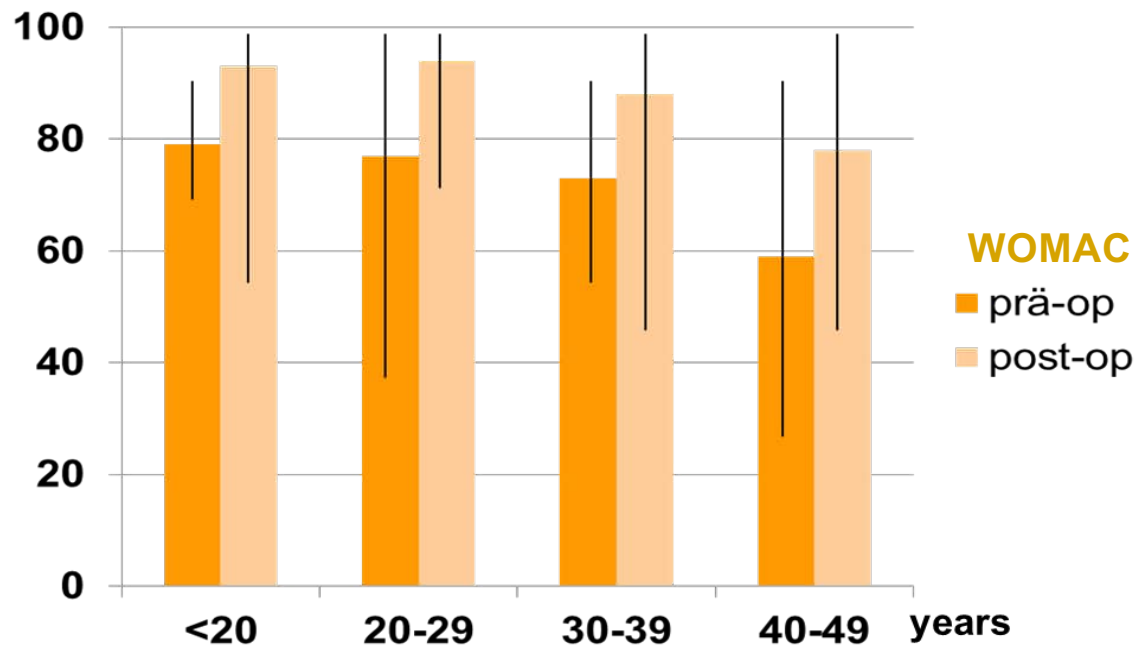


Patient age (osteotomy)

Orthopäde Published online: 12 February 2018

Periazetabuläre Osteotomie – Welchen Einfluss hat das Alter auf patientenrelevante Ergebnisse?

L. Franken¹ · F. Thielemann¹ · A. Postler¹ · S. Blum² · A. Hartmann¹ · K.-P. Günther¹ ·
J. Goronzy¹



106 PAO
2005 – 2010

mean age 27.1y (13-47y)

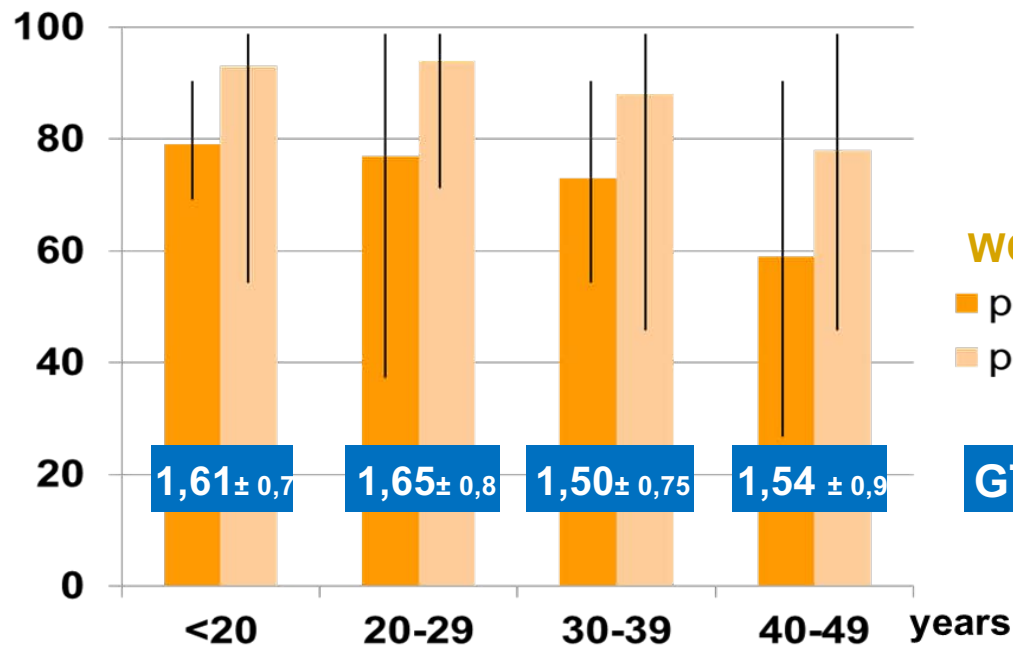


Patient age (osteotomy)

Orthopäde Published online: 12 February 2018

Periazetabuläre Osteotomie – Welchen Einfluss hat das Alter auf patientenrelevante Ergebnisse?

L. Franken¹ · F. Thielemann¹ · A. Postler¹ · S. Blum² · A. Hartmann¹ · K.-P. Günther¹ · J. Goronzy¹



106 PAO
2005 – 2010

mean age 27.1y (13-47y)

No difference in satisfaction



Patient age (arthroscopy)

systematic review

13 studies (1571 hips)

f/u 5 – 20y

Arthroscopy. 2021 Mar;37(3):1011-1025

Mid- to Long-Term Outcomes of Hip Arthroscopy: A Systematic Review



Cynthia Kyin, B.A., David R. Maldonado, M.D., Camille C. Go, B.S., Jacob Shapira, M.D.,
Ajay C. Lall, M.D., M.S., and Benjamin G. Domb, M.D.

Table 4. Summary of Predictors of Failure

Author and Year	Predictors of Failure
Dwyer et al. 2019 ³⁶	Chondral damage present on both the femoral head and acetabulum and increased age
Byrd et al. 2009 ³⁵	Preoperative osteoarthritis (subchondral sclerosis or erosions, joint space narrowing, or osteophyte formation), insidious labral tear rather than traumatic injury
Londers et al. 2007 ⁴⁰	Outerbridge grade III or IV
Meftah et al. 2011 ⁴¹	Preoperative osteoarthritis (<3 mm joint space narrowing, femoroacetabular cysts, subchondral sclerosis, or osteophytes)
Olach et al. 2019 ⁴³	Preoperative osteoarthritis (Kellgren and Lawrence grades 3 and 4)
Haefeli et al. 2016 ³⁷	Increased preoperative LCEA and femoral pistol grip deformity
Menge et al. 2017 ³⁰	Increased age, microfracture during the index procedure, and joint space <2 mm
Kaldau et al. 2018 ³⁸	Increased age and high-grade acetabular or femoral cartilage lesions
Chen et al. 2018 ¹⁴	Increased age and femoral head Outerbridge grade ≥2
Hevesi et al. 2018 ³⁴	Preoperative Tönnis grade 2, BMI >30, and age >35 years



Patient age (arthroscopy)

Arthroscopy: The Journal of Arthroscopic and Related Surgery, Vol 41, No 9 (September), 2025:

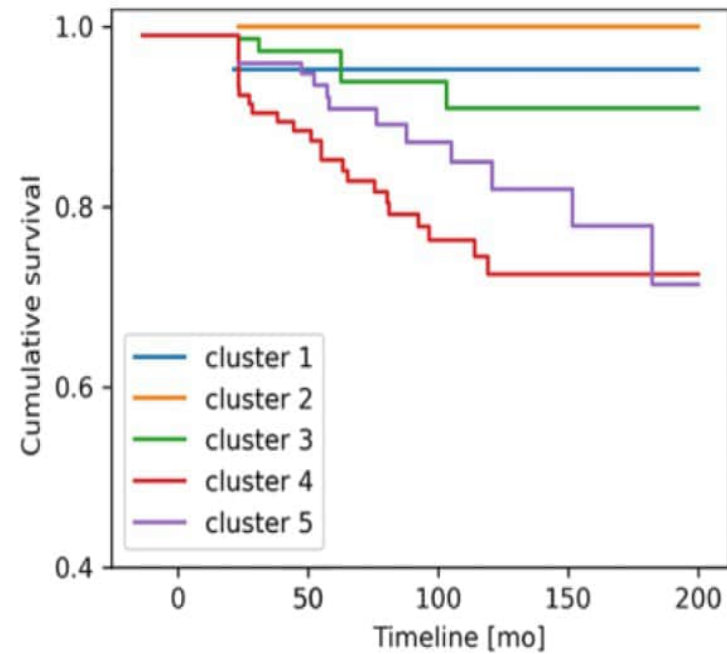
Editorial Commentary: Older Age, Higher Body Mass Index, and Female Sex May Be Associated With Inferior Long-Term Outcomes in Patients Undergoing Primary Hip Arthroscopy for Femoroacetabular Impingement, but With Modification of Risk Factors, Positive Results Can Still Be Achieved

Jay Moran, M.D., Jonathan Salandra, D.O., and Andrew E. Jimenez, M.D., Editorial Board



Muli-factorial approach

Orthopaedic Journal of Sports Medicine, 9(11) 2021
Automated Risk Stratification of Hip Osteoarthritis Development in Patients With Femoroacetabular Impingement Using an Unsupervised Clustering Algorithm
 Sunho Ko,* MD, Ayoosh Pareek,[†] MD, Changwung Jo,* MD, Hyuk-Soo Han,* MD, Myung Chul Lee,* MD, Aaron J. Krych,[‡] MD, and Du Hyun Ro,*[‡] MD




“Rochester Epidemiology Project”
 1071 patients with mean f/u 24.7 ± 12.5 y
 Machine Learning with 5 clusters
 for prediction of OA-risk in FAI

5 clusters:

Sex (female)	age (years)	co-factor
84%	20.9 ±9.6	BMI<19
95%	22.9 ±6.7	Pincer-FAI
71%	26.4 ±9.7	mixed FAI
76%	32.7 ±7.8	BMI>29, DM
57%	30.0 ±9.1	limited IR



Learning curve



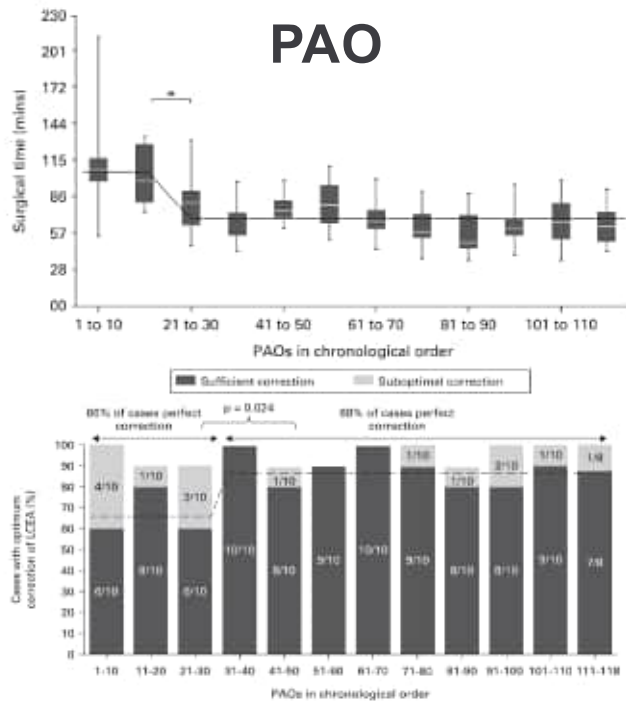
■ HIP

Unveiling the learning curve of periacetabular osteotomy

M. Haertlé,
N. Becker,
H. Windhagen,
S. S. Ahmad

The Learning Curve for Hip Arthroscopy: A Systematic Review

Daniel J. Hoppe, M.D., M.Ed., Darren de SA, M.D., Nicole Simunovic, M.Sc., Mohit Bhandari, M.D., Ph.D., F.R.C.S.C., Marc R. Safran, M.D., Christopher M. Larson, M.D., and Olufemi R. Ayeni, M.D., M.Sc., F.R.C.S.C.



Hip arthroscopy

Study	Complication Rate		
	Early Group	Late Group	P Value
Souza et al. ¹³	3.3%	7.3%	.771
Vilchez et al. ¹⁴	17%	3%	.041*
Konan et al. ¹¹	26.7%	2.9%	.080*
Sobau et al. ¹⁶	11%	2%	.005*
Lee et al. ¹²	—	—	—
Comba et al. ¹⁵	23%	5%	.002



Summary

- **Results of hip preserving surgery are generally good with**
 - low complication rates
 - high survival rates & patient satisfaction
- **Predictors for bad outcome are**
 - osteoarthritis (Tönnis > 1 and KL > 2)
 - advanced patient age
- **Need for multifactorial interpretation of results**
- **Respect learning curve**





Thank you very much
for your attention



**Universitätsklinikum
Tübingen**