UNI FR
UNIVERSITÉ DE FRIBOURG
UNIVERSITÄT FREIBURG

HFR
hôpital fribourgeois
freiburger spital

Pre-course Hip Symposium Bern 2023

Back to Life – Results of hip preservation surgery

Dr. med. Corinne A. Zurmühle, junior consultant

Departement of Orthopaedics Surgery and Traumatology
University of Fribourg, HFR Cantonal Hospital Fribourg
Switzerland

What we learnt in meantime…

Good results for decades if

- we select the right patient at the right time
- we chose the right treatment option
- we clarify the expectations with the patient

What do we know concerning the results of FAI?

Cam	Pincer	Excessive antetorsion	Retrotorsion
Inclusion	Impaction with subluxation	levering out anterior	levering out posterior

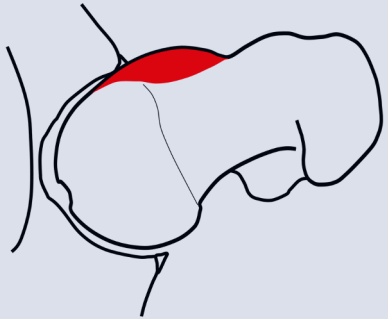

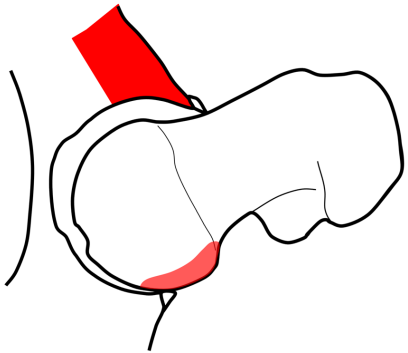

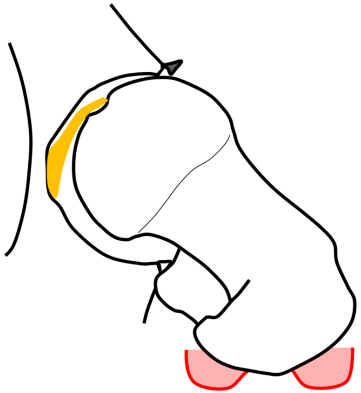

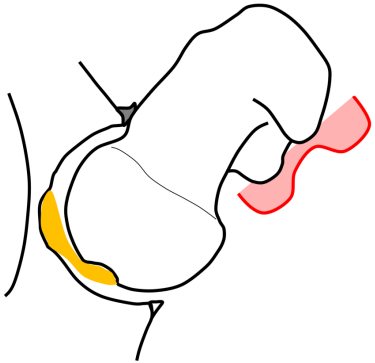

Natural history: How strong is the correlation?

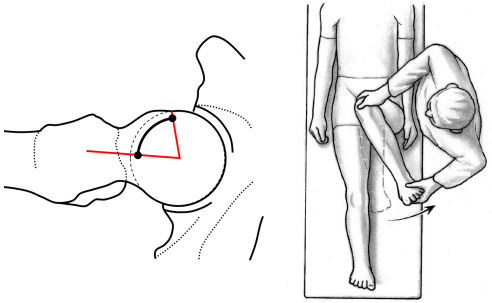

Huge asphericity with

reduced range of motion

- osteoarthritis

Sun - Melanoma

Alcohol - Liver cirrhosis

Smoking - Lung Cancer

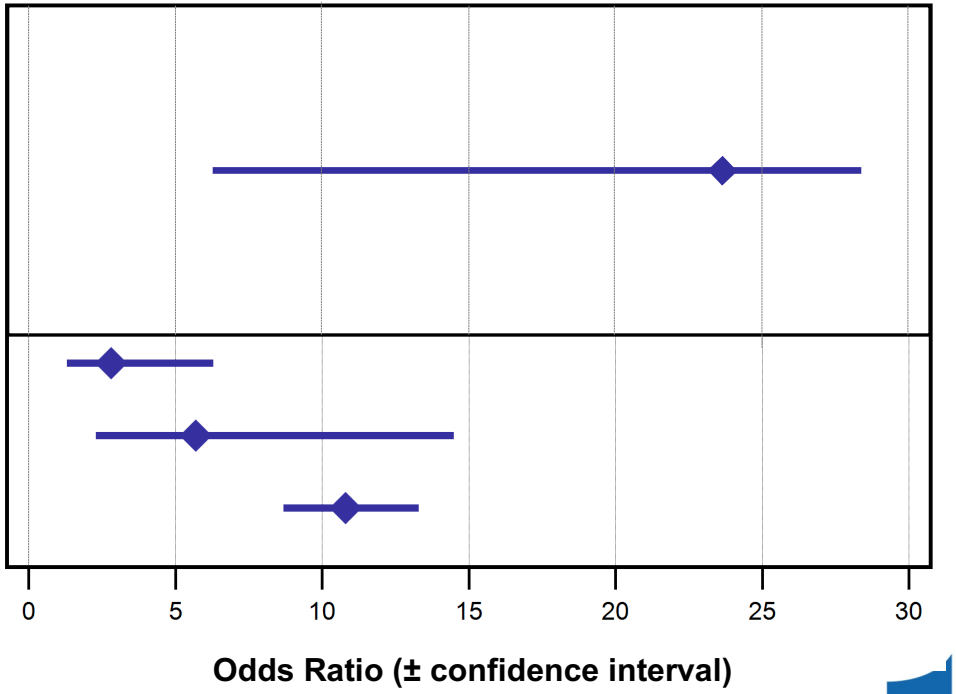

Agricola et al Ann Rheum Dis 2013
Pesch et al, Int J Cancer 2012
Stroffolini et al, Liver Int 2010
Oliveira et al, Arch Dis Child 2006

Basic Research with animal model - Swiss Alpine Sheep



- Comparable hip anatomy and biomechanics
- Comparable MRI properties
- No predisposition for osteoarthritis
- Predictable range of motion
- Timelapse effect (time machine)
- **Natural femoral asphericity**

Philipps et al, J Arthroplasty, 1987
Miozzari et al, Osteoarthritis Cartilage, 2004
Mazoochian et al, Vet Comp Orthop Traumatol. 2012

Basic Research with animal model - Swiss Alpine Sheep

- Known pathomechanism - Joint damage appears at the level of impingement

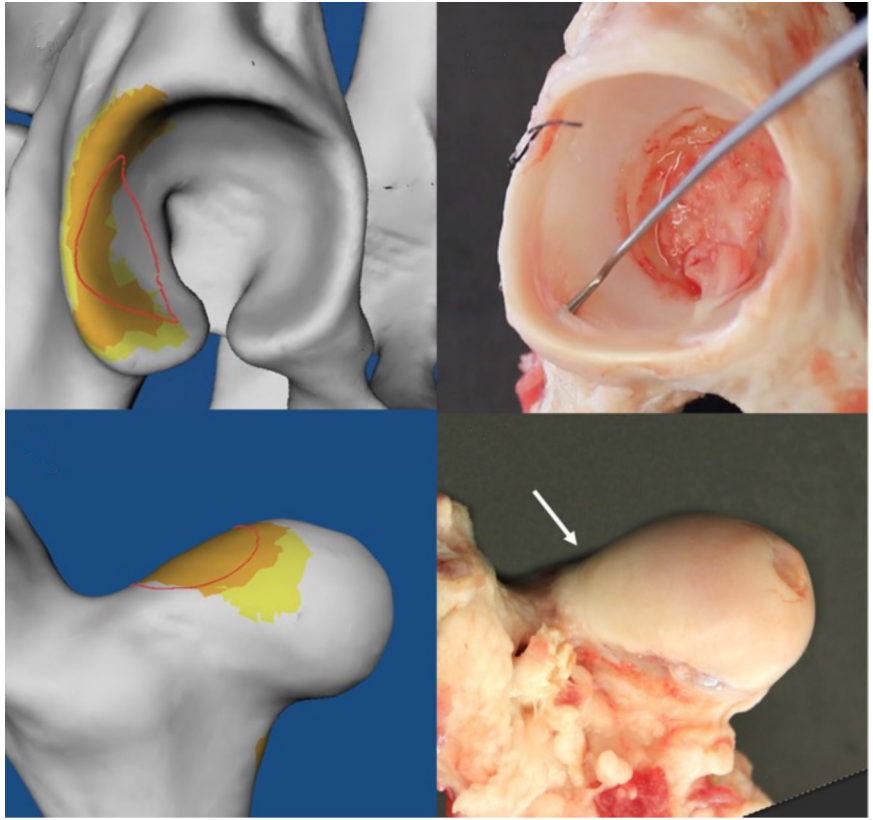

Nötzli HP JBJS Br 2002
Ganz R CORR 2003
Beck M CORR 2004
Clohishy JBJS 2011
Thomas GE Osteoarthritis Cartillage 2014
Zurmühle CA Osteoarthritis Cartilage 2019

Basic Research with animal model - Swiss Alpine Sheep

- Known pathomechanism - Joint damage appears at the level of impingement
- Histological proof

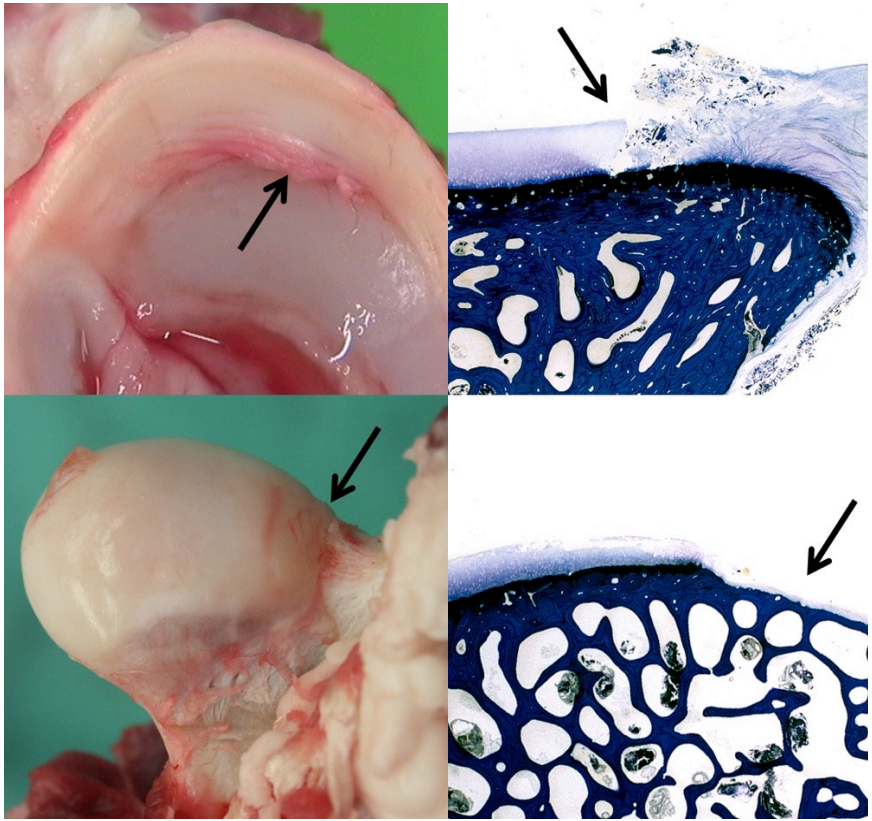

Nötzli HP JBJS Br 2002
Ganz R CORR 2003
Beck M CORR 2004
Clohishy JBJS 2011
Thomas GE Osteoarthritis Cartillage 2014
Zurmühle CA Osteoarthritis Cartilage 2019

Basic Research with animal model - Swiss Alpine Sheep

- Known pathomechanism - Joint damage appears at the level of impingement
- Histological proof
- More damage with longer ambulation time

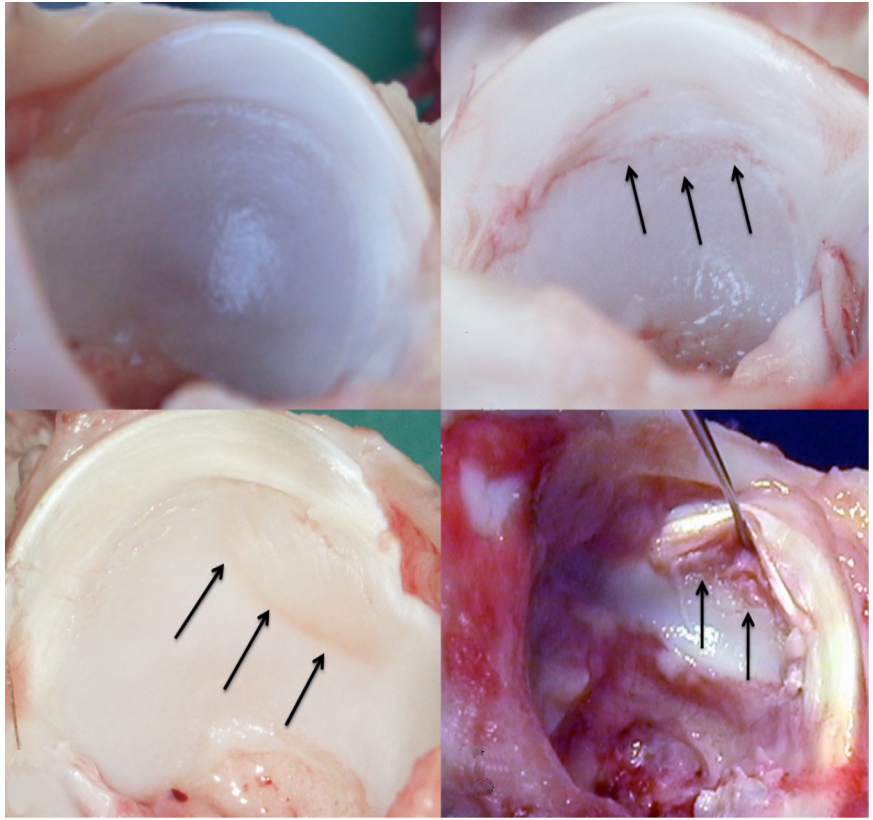

Nötzli HP JBJS Br 2002
Ganz R CORR 2003
Beck M CORR 2004
Clohishy JBJS 2011
Thomas GE Osteoarthritis Cartillage 2014
Zurmühle CA Osteoarthritis Cartilage 2019

What do we know concering natural history of FAI?

Cam	Pincer	Excessive antetorsion	Retrotorsion
Inclusion	Impaction with subluxation	levering out anterior	levering out posterior

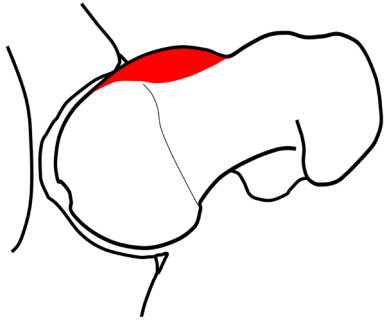

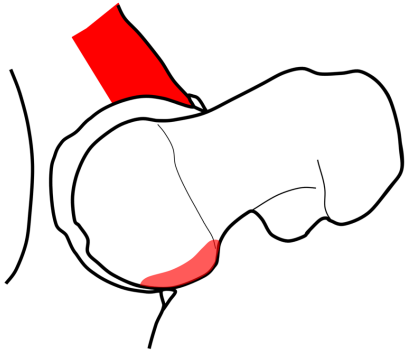

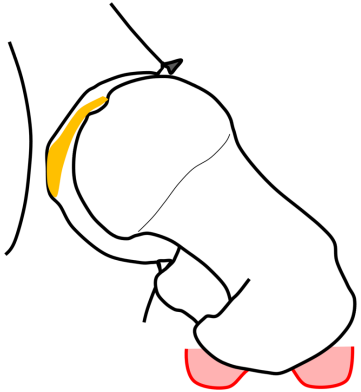

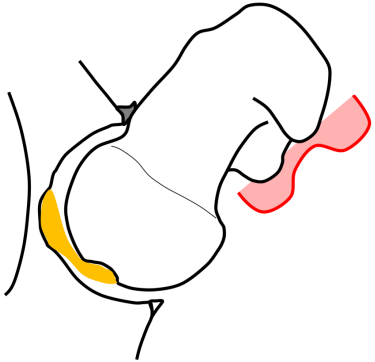

Strong correlation between cam and osteoarthritis (THA)	Study results are not conclusive OA / no OA in cases with LCE > 39 – 45° More THA in retroversion	Excessive antetosion is risk factor for more severe hip OA Retroversion is a factor for osteoarthitis	

What are good results?

Patient

- No pain
- Good function
- No osteoarthritis in young age

Imaging

- No progression of osteoarthritis

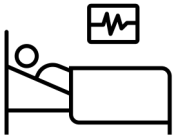

Surgery

- No complication
- No revision

Patient related outcome scores

- Different scores in different studies
- Hip specific versus general health
- Content: Pain, activity of daily life, sport, function

!

- „Good function" in young versus old patient
- Prothesis versus hip preservation
- Retrospective evaluation

Patient related outcome scores

Scoring System of Merle d'Aubigné and Postel

Points	Pain	Range of Motion	Walking Ability
6	None	Flexion > 90°, abduction > 30°	Normal
5	Occasional	Flexion = 80 -90°, abduction > 15°	Slight limp
4	Disappears on rest	Flexion = 60 -80°, can reach foot	Short distance without cane
3	Limits activity	Flexion = 40 -60°	Permanent use of 1 cane
2	Prevents activity	Flexion < 40°	2 canes
1	Night pain	Ankylosis, good hip position	2 crutches
0	Permanent intense	Ankylosis, bad hip posi tion	None

Interpretation
Excellent: 18 points
Good: 15 - 17 points
Fair: 12 - 14 points
Poor: < 12 points

Radiological outcome parameters

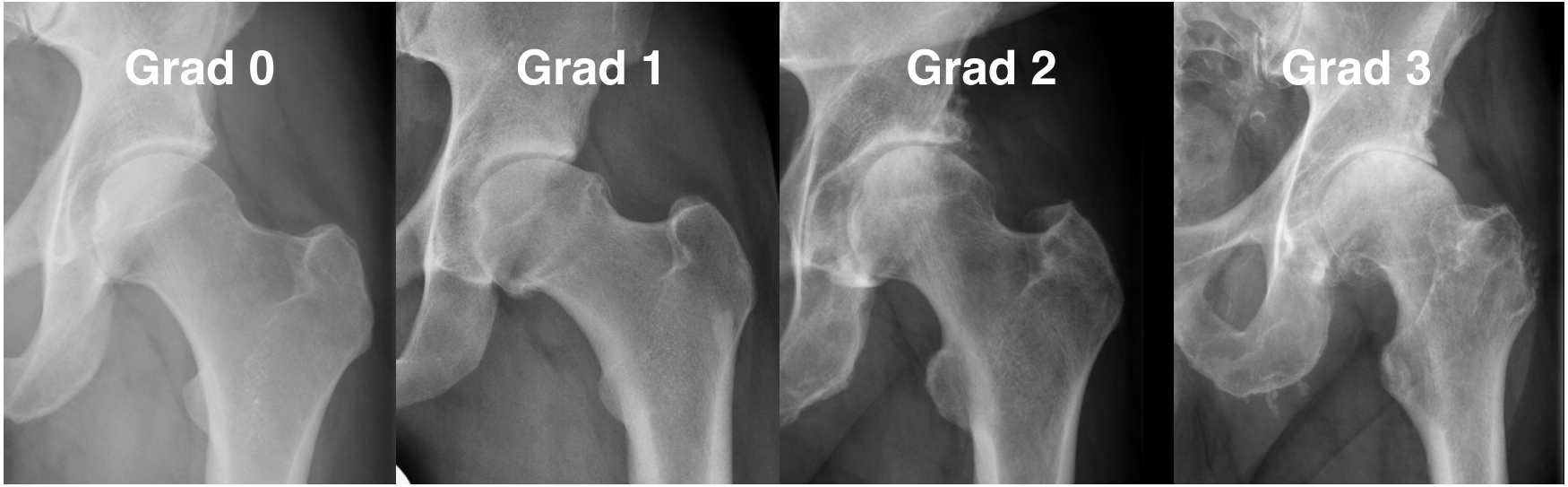

Progression of osteoarthrits (Tönnis score)

- Standard x-ray based followup
- Advanced signs of osteoarthritis

Radiological outcome parameters

MR-based followup

- Early signs of osteoarthritis
- Expensive cost
- Long acquisition time
- Special sequences and contrast agent

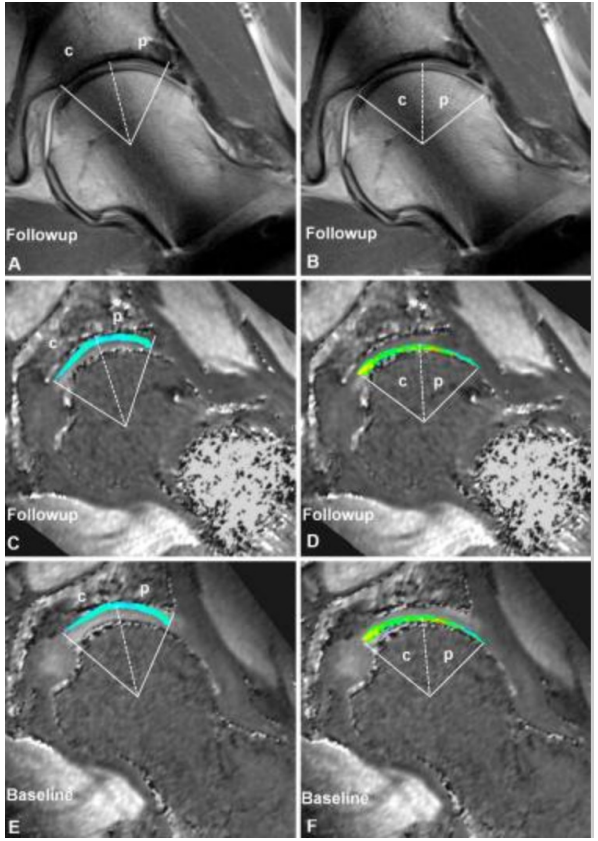

!

- Only for special questions
- Only in prospective studies

Results - Surgical hip dislocation

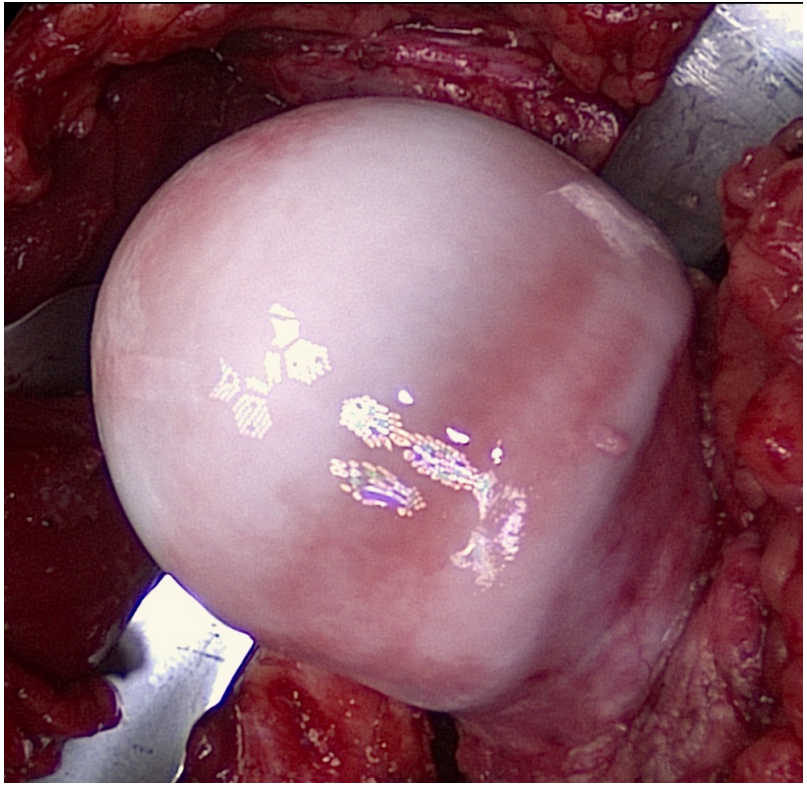

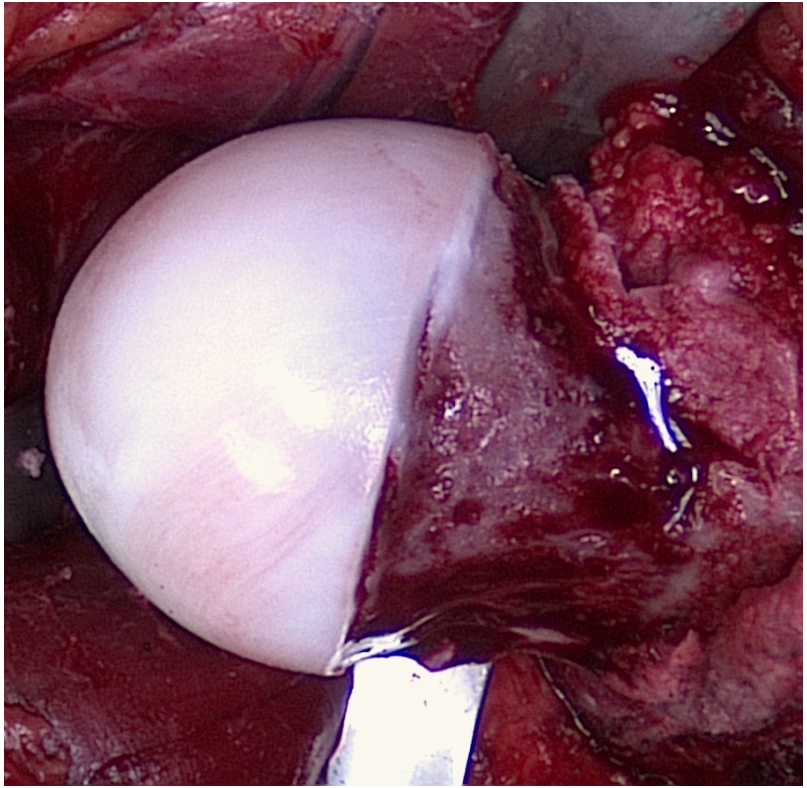

Results SHD – Survivorship

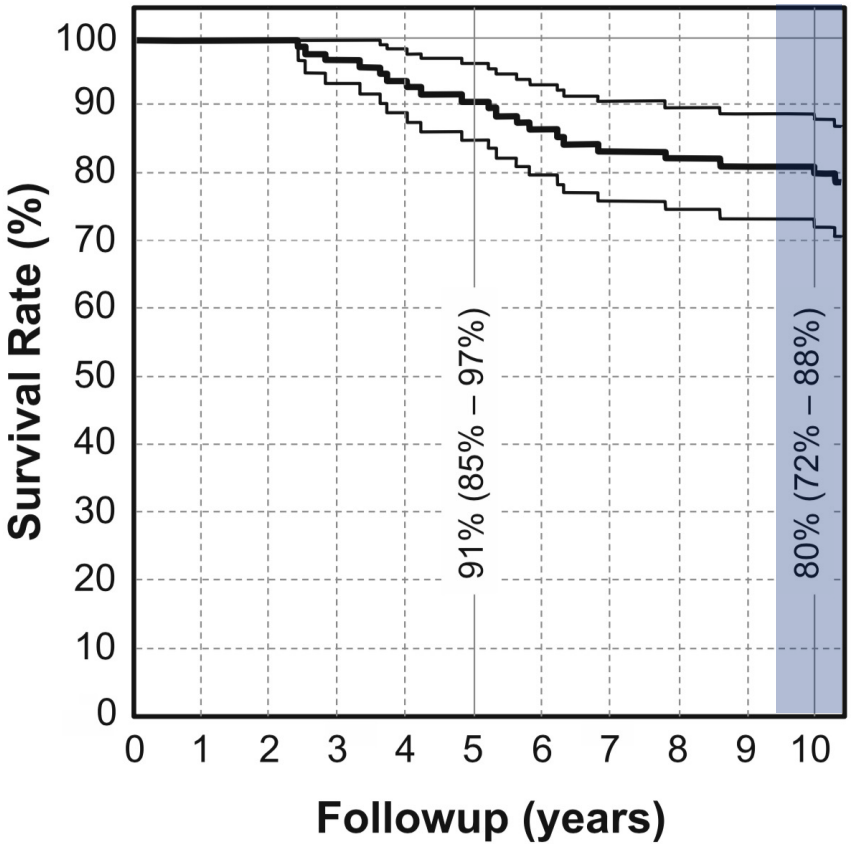

Retrospective study of 97 hips

- Worse clinical outcome (= Merle d'Aubigne Score < 15) in **3 hips (3%)**
- Progression of osteoarthritis (Tönnis) in **8 hips (8%)**
- Conversion to THA in **11 hips (11%)**

Steppacher et al, CORR, 2014
Steppacher et al, CORR, 2015

Results SHD - Outcome

Patient

- Good mean Merle d‘Aubigné score: 17 ± 1 (12-18)

Imaging

- Progression of osteoarthritis in 8%
- THA in 11%

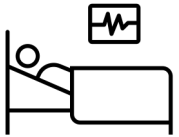

Surgery

- 6% complications
- 45% revisions

Steppacher et al, CORR, 2014
Steppacher et al, CORR, 2015

Results SHD – Negative predictors

Category	Parameter	Hazard ratio† (95% confidence interval)	p value	Adjusted hazard ratio‡ (95% confidence interval)	p value
Demographic factors	Age > 40 years	4.9 (4.0–5.8)	< 0.001	5.9 (4.8–7.1)	0.002
	Weight > 100 kg	4.6 (3.3–5.9)	0.019		
	Body mass index > 30 kg/m^2	5.1 (3.6–6.6)	0.033	5.5 (3.9–7.2)	0.041
Postoperative factors related to surgical accuracy	LCEA < 22° or > 32°*	5.4 (4.3–6.5)	0.003	5.4 (4.2–6.6)	0.006
	AI < 3° or > 13°*	5.3 (3.7–6.9)	0.037		
	Extrusion index < 18% or > 28%*	5.6 (4.5–6.7)	0.002		
	Total femoral coverage < 72% or > 83%*	3.1 (2.1–4.1)	0.029		
	Anterior femoral coverage < 15%*	3.7 (2.4–4.9)	0.038		
	Posterior femoral coverage < 34%*	3.4 (2.4–4.3)	0.011	4.8 (3.7–5.9)	0.006

- Age and body mass index

Steppacher et al, CORR, 2014
Steppacher et al, CORR, 2015

Results SHD – Negative predictors

Category	Parameter	Hazard ratio† (95% confidence interval)	p value	Adjusted hazard ratio‡ (95% confidence interval)	p value
Demographic factors	Age > 40 years	4.9 (4.0–5.8)	< 0.001	5.9 (4.8–7.1)	0.002
	Weight > 100 kg	4.6 (3.3–5.9)	0.019		
	Body mass index > 30 kg/m^2	5.1 (3.6–6.6)	0.033	5.5 (3.9–7.2)	0.041
Postoperative factors related to surgical accuracy	LCEA < 22° or > 32°*	5.4 (4.3–6.5)	0.003	5.4 (4.2–6.6)	0.006
	AI < 3° or > 13°*	5.3 (3.7–6.9)	0.037		
	Extrusion index < 18% or > 28%*	5.6 (4.5–6.7)	0.002		
	Total femoral coverage < 72% or > 83%*	3.1 (2.1–4.1)	0.029		
	Anterior femoral coverage < 15%*	3.7 (2.4–4.9)	0.038		
	Posterior femoral coverage < 34%*	3.4 (2.4–4.3)	0.011	4.8 (3.7–5.9)	0.006

- Age and body mass index
- Acetabular under- or overcoverage

Steppacher et al, CORR, 2014
Steppacher et al, CORR, 2015

Results - Hip Arthroscopy (HAS)

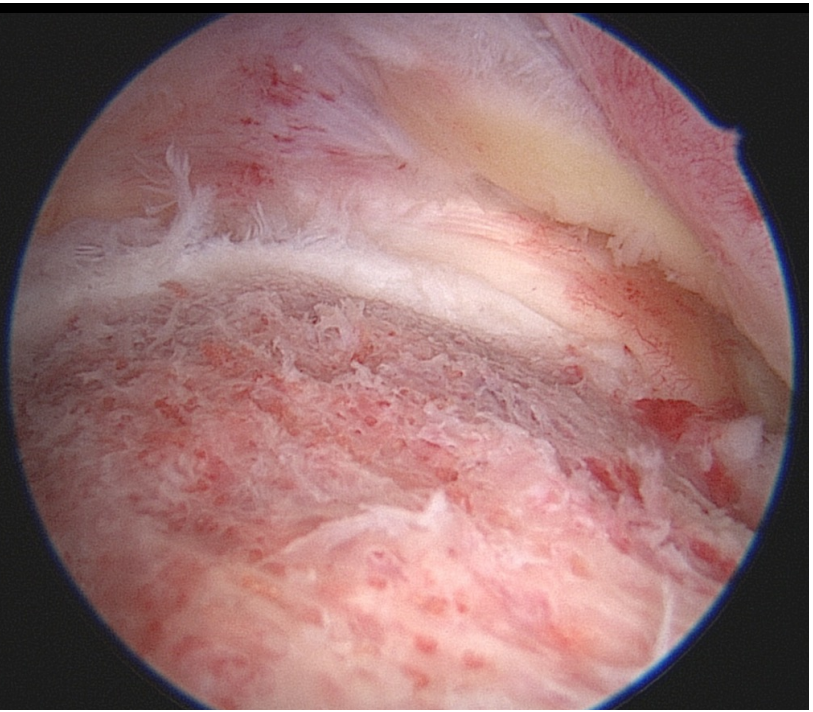

- Popular in sports medicine
- Improvement in clinical outcomes scores in at least 10-year follow-up

!

- Heterogeneous indications
  - FAI
  - Labral tears
  - Dysplasia
- Addresses only intraarticular pathomorphologies

Lee et al, Arthroscopy, 2023

Results HAS – Survivorship

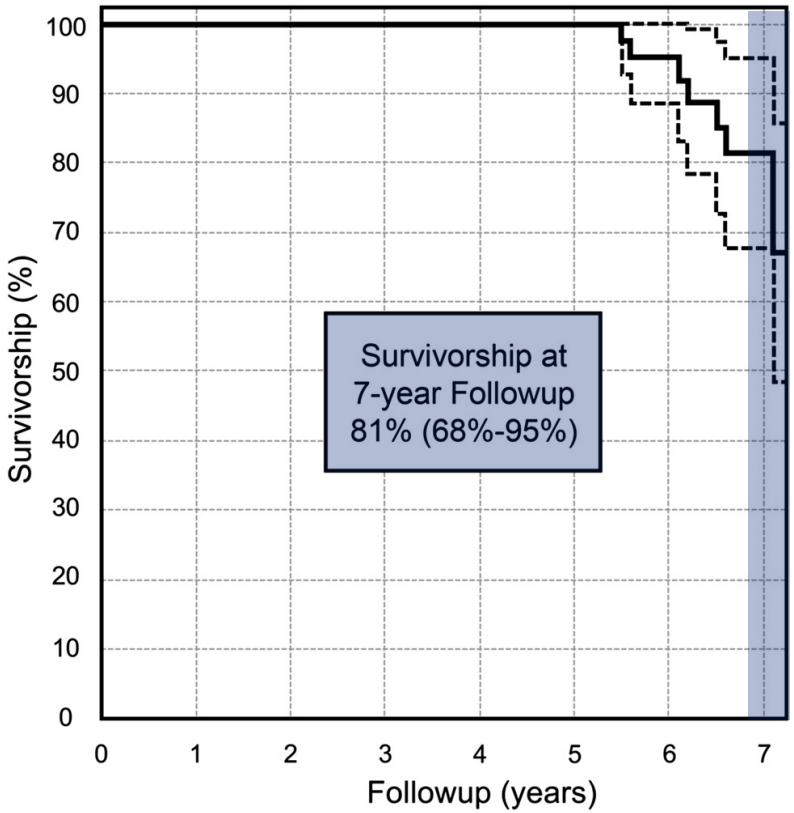

- 7-year follow-up (OP between 2003 – 2008)
  - 52 hips in 52 patients
  - Mean age: 35 ± 12 years (16 - 63)
- 39 cam, 4 pincer, 9 mixed type impingement
- Merle d‘Aubigné Score preoperative
  - Mean score: 14 ± 1 (8 - 15)

Haefeli PC et al, CORR, 2016

Results SHD - Outcome

Patient

- Mean Merle d‘Aubigné score: 16 ± 2 (7-18)
- 13% with score < 15

Imaging

- Progression of osteoarthritis in 13%
- THA in 4%

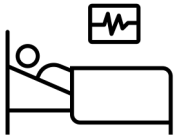

Surgery

- 17% revisions (offset / acetabular correction!)

Haefeli PC et al, CORR, 2016

Results HAS – Risk factors for revisions

Factor	Hazard ratio	p value
Demographic		
Left hip	5.30 (1.08–26.12)	0.040
BMI > 25 kg/m^2	3.89 (0.97–15.64)	0.056
BMI < 25 kg/m^2	0.28 (0.07–1.14)	0.075
Preoperative radiographic parameters		
LCE angle > 33°	4.63 (1.07–19.94)	0.040
LCE angle (per °)	1.15 (1.00–1.32)	0.045
AI < 3°	95.58 (8.02–1162.64)	< 0.001
AI (per °)	0.77 (0.64–0.94)	0.009
Extrusion index (per %)	0.85 (0.73–1.00)	0.051
Pistol grip deformity (per °)	1.55 (1.34–1.78)	< 0.001
Surgical interventions		
Labrum refixation	3.86 (0.40–37.23)	0.242
Labrum excision	0.40 (0.08–1.96)	0.260
Postoperative radiographic parameters		
Pistol grip (beta angle)	1.05 (1.00–1.09)	0.035

- Large acetabular coverage
  - Technical challenge
- Pistol grip deformity
  - Technical challenge
  - Retinacular vessels
- Persistant pistol grip deformity
  - Insufficient correction

Haefeli PC et al, CORR, 2016

Results HAS – Outcome Age and Osteoarthritis

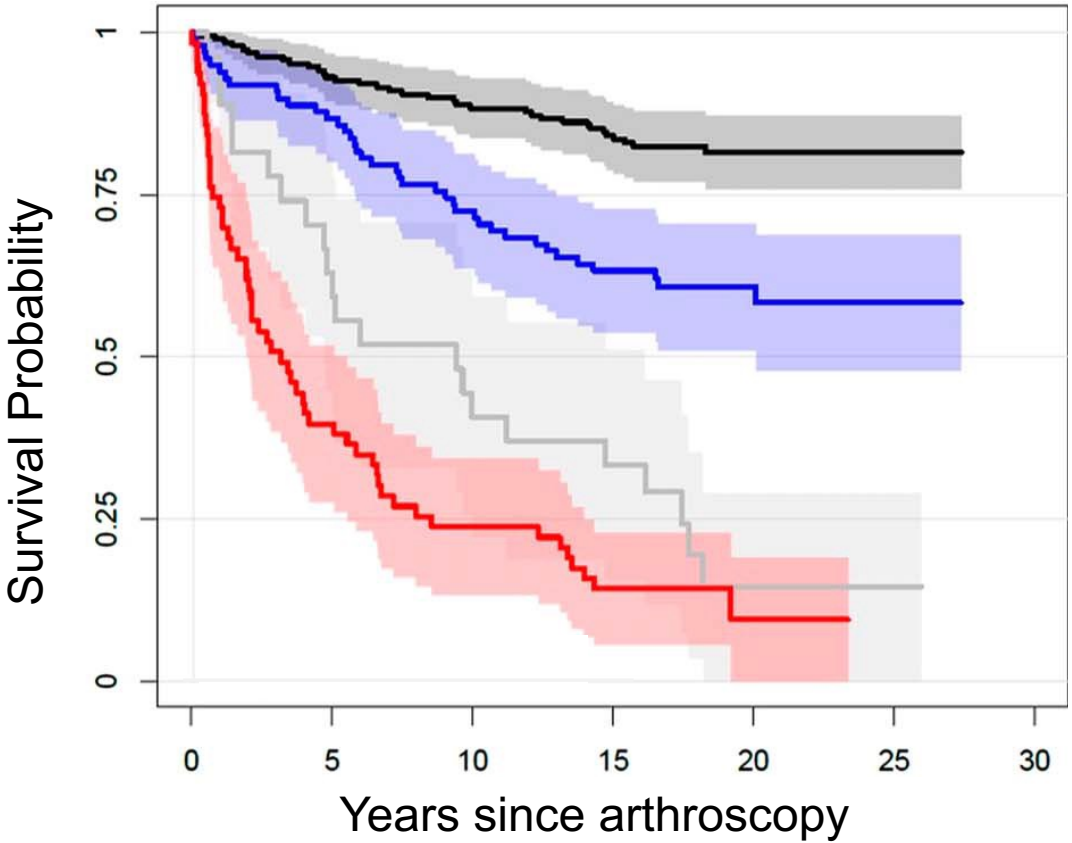

Acetabular osteoarthritis

- < 40 years, no damage
- > 40 years, no damage
- < 40 years, **damage**
- > 40 years, **damage**

Dwyer MK et al, CORR, 2019

Results HAS – Outcome Age and Osteoarthritis

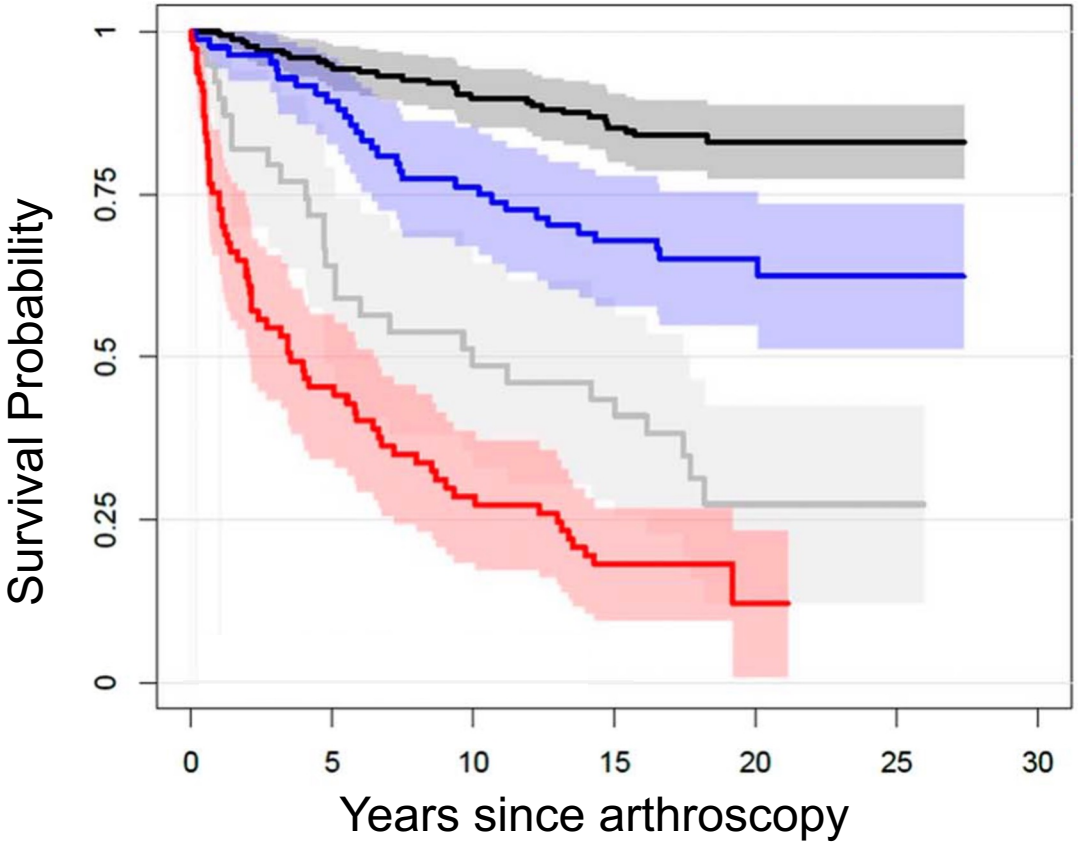

Femoral osteoarthritis

- < 40 years, no damage
- > 40 years, no damage
- < 40 years, **damage**
- > 40 years, **damage**

Significance (p-value)

- Age: 0.011
- Cartilage damage: 0.001

Dwyer MK et al, CORR, 2019

Results HAS – Outcome predictors

Negative predictors

- Preoperative osteoarthitis (Tönnis grades >1)
  - 54% conversion to THA
- Labral debridement / resection
- Age ≥ 40-50 years
- Obesity
- Huge deformity
- Low preoperative clinical scores
- Dysplastic hips / acetabular overcorrection
- Decreased femoral torsion

Positive predictors

- Tönnis score < 1
- Labral repair
- Age ≤ 40-50 years
- Normal acetabular coverage
- > 2mm joint space

Zimmerer et al, Arthroscopy, 2021
Kucharik MP et al, Orthop J Sports Med 2022
Carton P et al Am J Sports Med 2021
Büchler L et al, CORR 2021
Menge TJ et al, J Bone Joint Surg Am, 2017

What do we know concerning the results of FAI?

Cam	Pincer	Excessive antetorsion	Retrotorsion
Inclusion	Impaction with subluxation	levering out anterior	levering out posterior

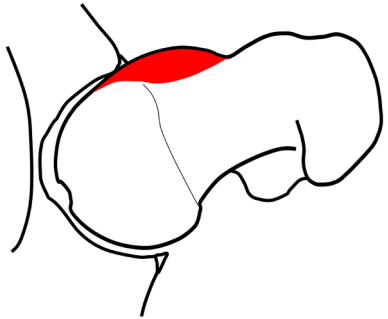

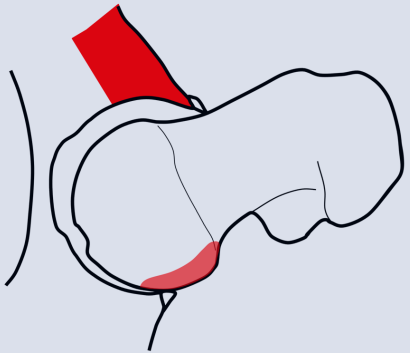

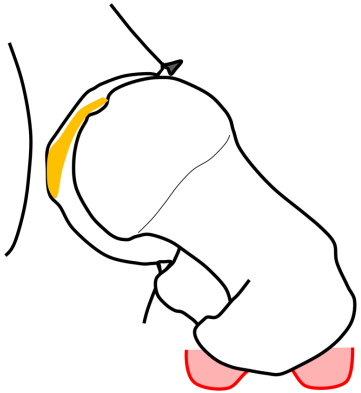

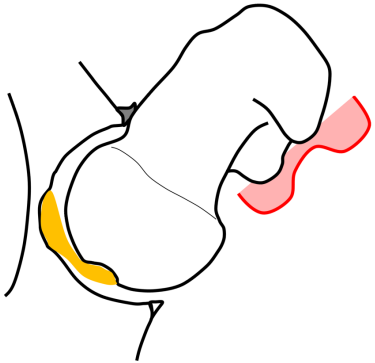

Results – Reversed periaceetabular osteotomy (rPAO)

Definition of acetabular retroversion

- Cross-over sign
- Posterior wall sign
- Ischial spine sign

Important reason for pincer type femoroacetabular impingement

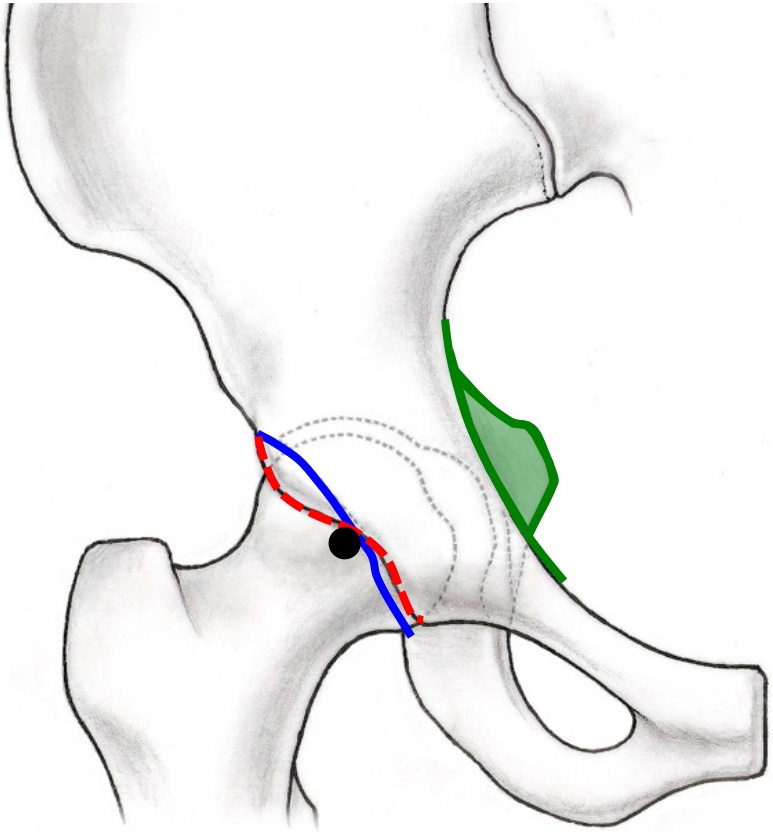

Results rPAO– Technique

Acetabular retroversion	Reversed PAO with offset correction	Surgical hip dislocation with rim trimming

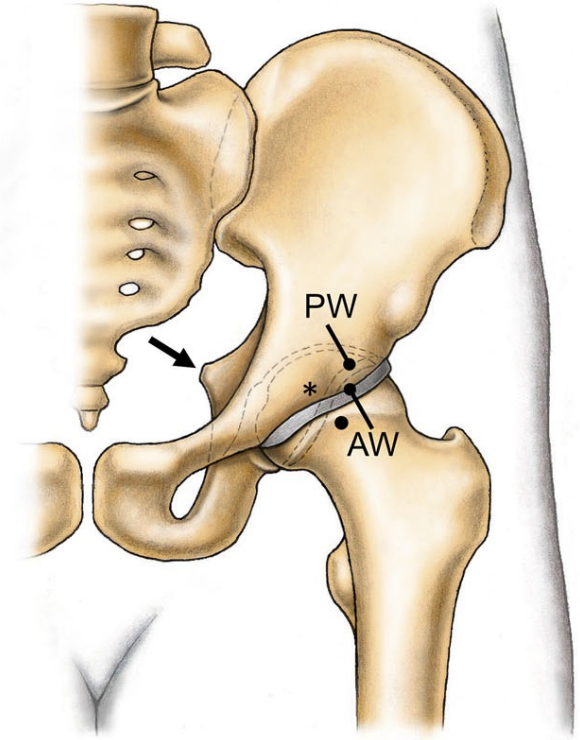

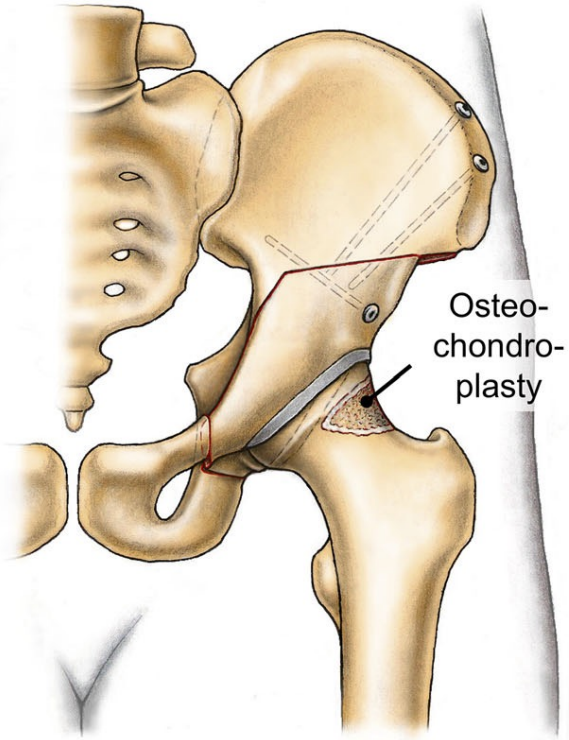

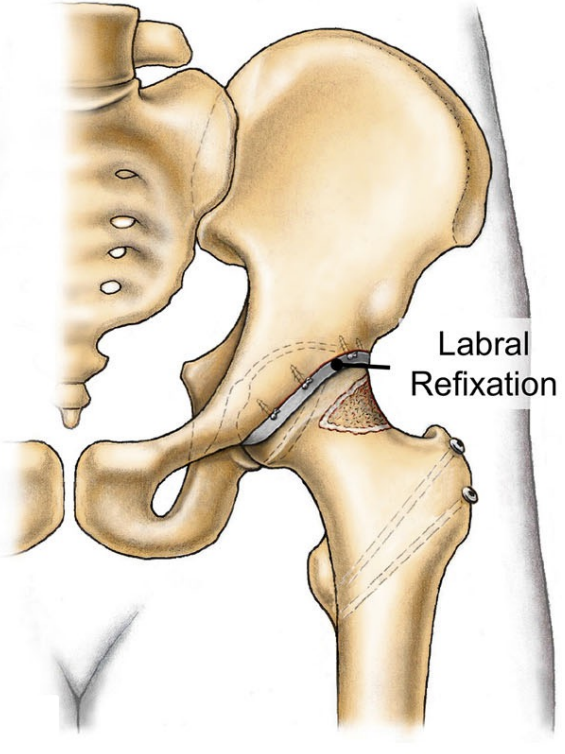

Results rPAO – Survivorship

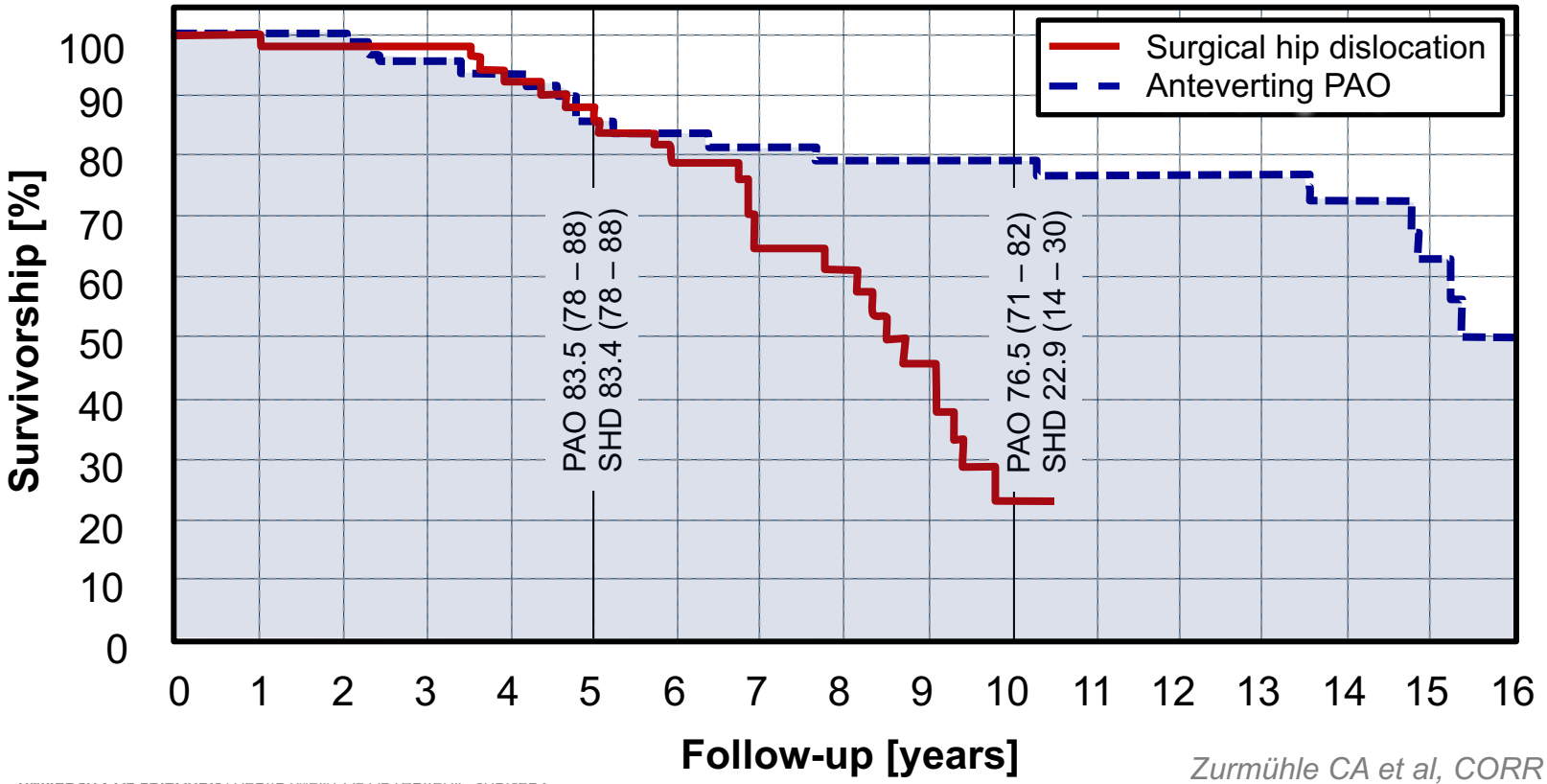

Zurmühle CA et al, CORR 2017

What do we know concerning the results of FAI?

Cam	Pincer	Excessive antetorsion	Retrotorsion
Inclusion	Impaction with subluxation	levering out anterior	levering out posterior

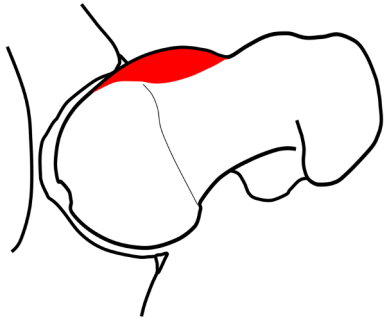

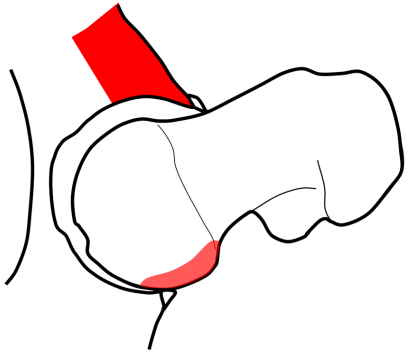

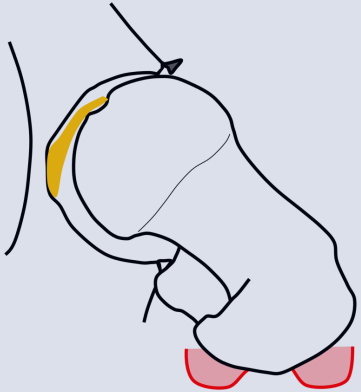

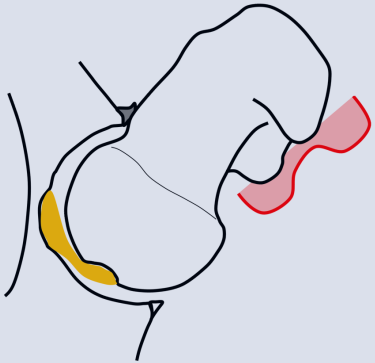

Results femoral osteotomies

Different techniques

- Intramedullary nail versus plate
- Open versus closed
- +/- surgical hip dislocation
- Different levels of corrections

Limitations

- Small cohorts
- Short followups
- Hetergenous indications

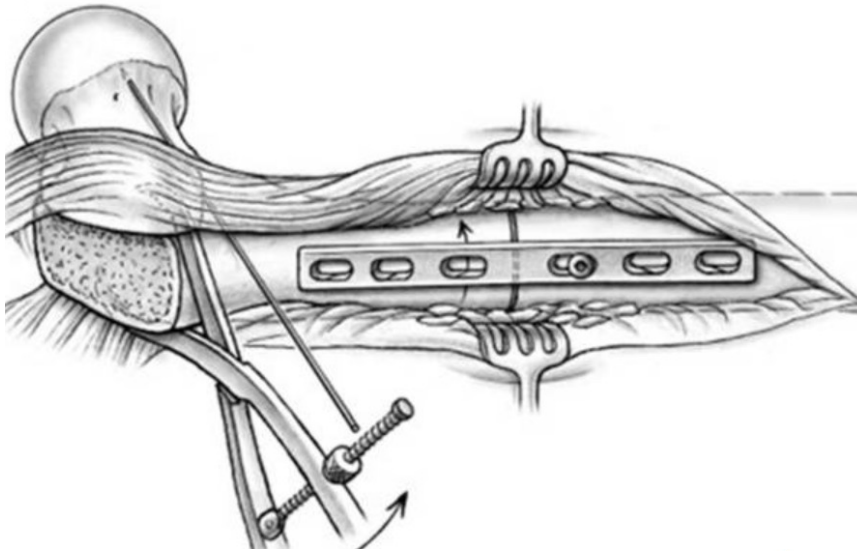

Kamath et al , J Hip Perserv, 2015
Lerch et al, HIP, 2020
Buly RL et al, J Am Acad Orthop Surg, 2018

Results Femoral Osteotomies - Outcome

Patient

Imaging

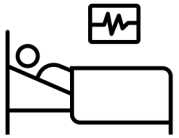

Surgery

- Good mean Merle d‘Aubigné score: 16 ± 2 (12–18)
- 80% would do surgery again

- No osteoarthritis (CAVE short follow-up
- No THA

- No complications
- 64% hardware removal

Lerch et al, HIP, 2020

Natural history – Hip dysplasia

Pathognomic factors

- Reduced joint surface and coverage
- Joint instability with luxation or subluxation

Natural history

- 4.3x more degenerative changes than in normal hips



Murphy SB et al JBJS 1995
Weinstein SL et al CORR 1987
Reijman A et al Arthritis Rheum 2005
Jacobsen S et al Acta Orthop 2005
Steppacher et al Osteoarthritis Cartillage 2014

Results – periacetabular osteotomy (PAO)

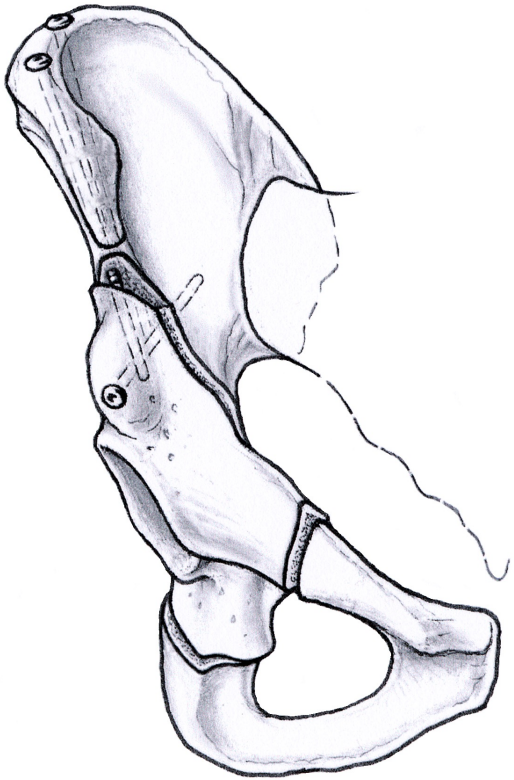

- 30-year followup (OP 1984 – 1987)
  - 75 hips in 63 patients
  - Mean age: 29 ± 12 years (13 - 56)
- Merle d‘Aubigné Score preoperative
  - Mean 15 ± 2 (9-18)
- Endpoint
  - Conversion to THA
  - Progression of osteoarthritis (> 1 Tönnis Score)
  - Merle d’Aubigne Score < 15 points

Lerch TD et al, CORR, 2017

Results PAO – Survivorship

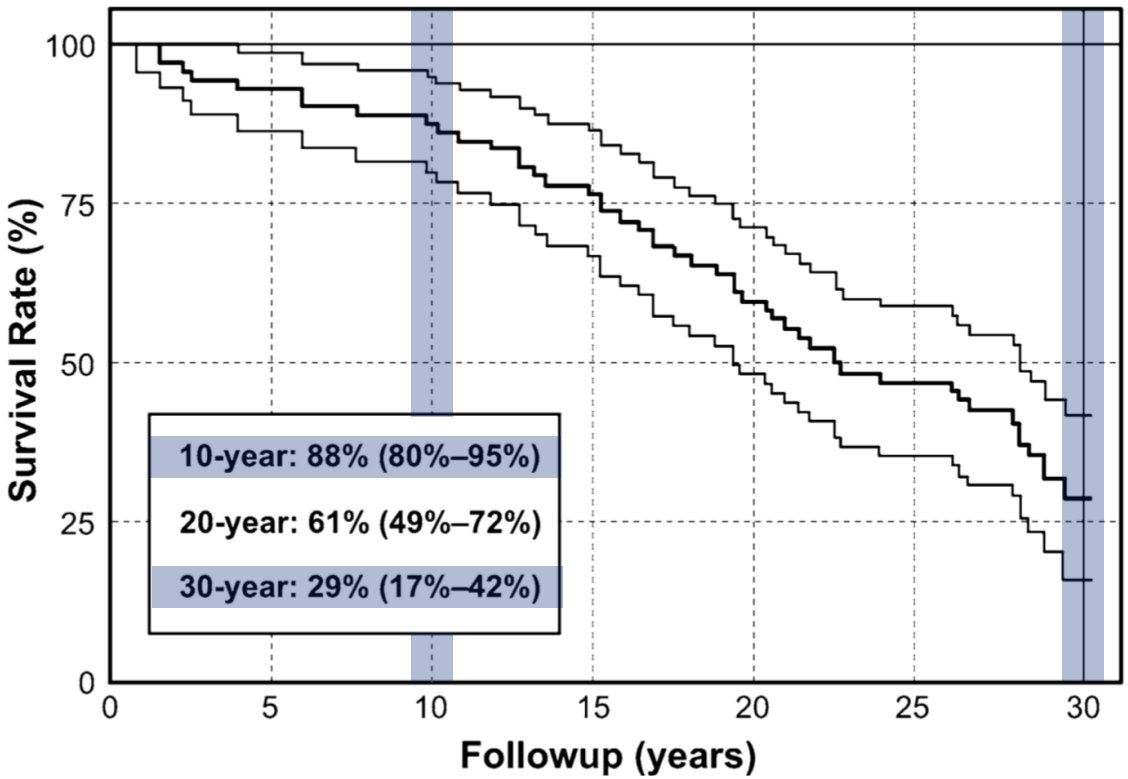

Lerch TD et al, CORR, 2017

Results PAO - Outcome

Patient

- Good mean Merle d‘Aubigné score: 15 ± 2 (9–18)
- 9% bad outcome score

Imaging

- osteoarthritis progression in 5%
- 43% no THA (at 30 – year followup

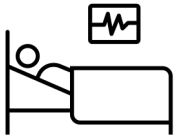

Surgery

- Learning curve included!

Lerch et al, CORR, 2017

Results PAO – Negative predictors

Parameter	Hazard ratio* (95% confidence interval)	p value	Hazard ratio† (95% confidence interval)	p value
Age > 30 years	3.8 (3.0–4.6)	< 0.001		
Age > 40 years	4.3 (3.7–4.9)	< 0.001		
Preoperative Merle d'Aubigné-Postel score [8] < 15	4.1 (3.5–4.6)	< 0.001	3.4 (2.7–4.2)	< 0.001
Preoperative Harris hip score [13] < 70	5.8 (5.2–6.4)	< 0.001		
Preoperative limp	1.7 (1.4–1.9)	0.001		
Preoperative pain in flexion and internal rotation (anterior impingement test)	3.6 (3.1–4.2)	< 0.001	2.6 (1.8–3.3)	0.006
Preoperative pain in extension and external rotation (posterior impingement test)	2.5 (1.7–3.2)	0.021		
Preoperative internal rotation < 20°	4.3 (3.7–4.9)	< 0.001		
Preoperative osteoarthritis [51] Tönnis Grade > 1	5.7 (5.0–6.4)	< 0.001	2.7 (1.9–3.5)	0.014
Postoperative anterior overcoverage (anterior coverage > 27%) [46]	3.2 (2.5–3.9)	0.001	2.5 (1.7–3.3)	0.021
Postoperative retroversion‡	4.8 (3.4–6.3)	0.034		

- Poor function
- Severe pain
- Pre-existing joint degeneration

Lerch TD et al, CORR, 2017

Results PAO – Negative predictors

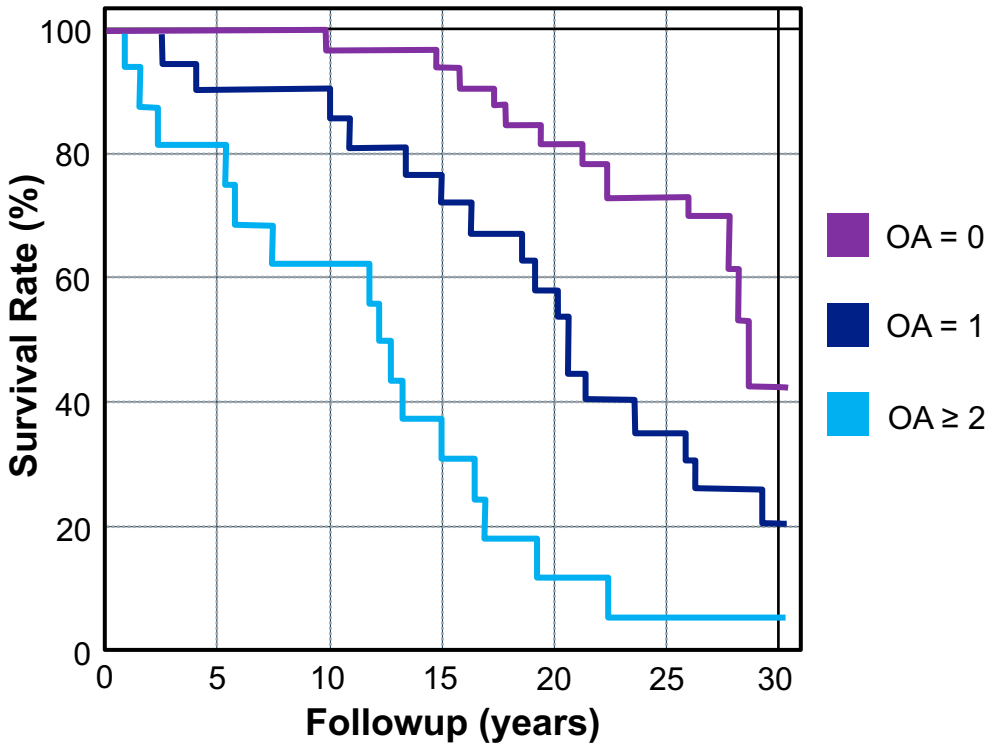

Results PAO – Negative predictors

Parameter	Hazard ratio* (95% confidence interval)	p value	Hazard ratio† (95% confidence interval)	p value
Age > 30 years	3.8 (3.0–4.6)	< 0.001		
Age > 40 years	4.3 (3.7–4.9)	< 0.001		
Preoperative Merle d'Aubigné-Postel score [8] < 15	4.1 (3.5–4.6)	< 0.001	3.4 (2.7–4.2)	< 0.001
Preoperative Harris hip score [13] < 70	5.8 (5.2–6.4)	< 0.001		
Preoperative limp	1.7 (1.4–1.9)	0.001		
Preoperative pain in flexion and internal rotation (anterior impingement test)	3.6 (3.1–4.2)	< 0.001	2.6 (1.8–3.3)	0.006
Preoperative pain in extension and external rotation (posterior impingement test)	2.5 (1.7–3.2)	0.021		
Preoperative internal rotation < 20°	4.3 (3.7–4.9)	< 0.001		
Preoperative osteoarthritis [51] Tönnis Grade > 1	5.7 (5.0–6.4)	< 0.001	2.7 (1.9–3.5)	0.014
Postoperative anterior overcoverage (anterior coverage > 27%) [46]	3.2 (2.5–3.9)	0.001	2.5 (1.7–3.3)	0.021
Postoperative retroversion‡	4.8 (3.4–6.3)	0.034		

- miscorrection

Lerch TD et al, CORR, 2017

Results PAO – Acetabular retroversion

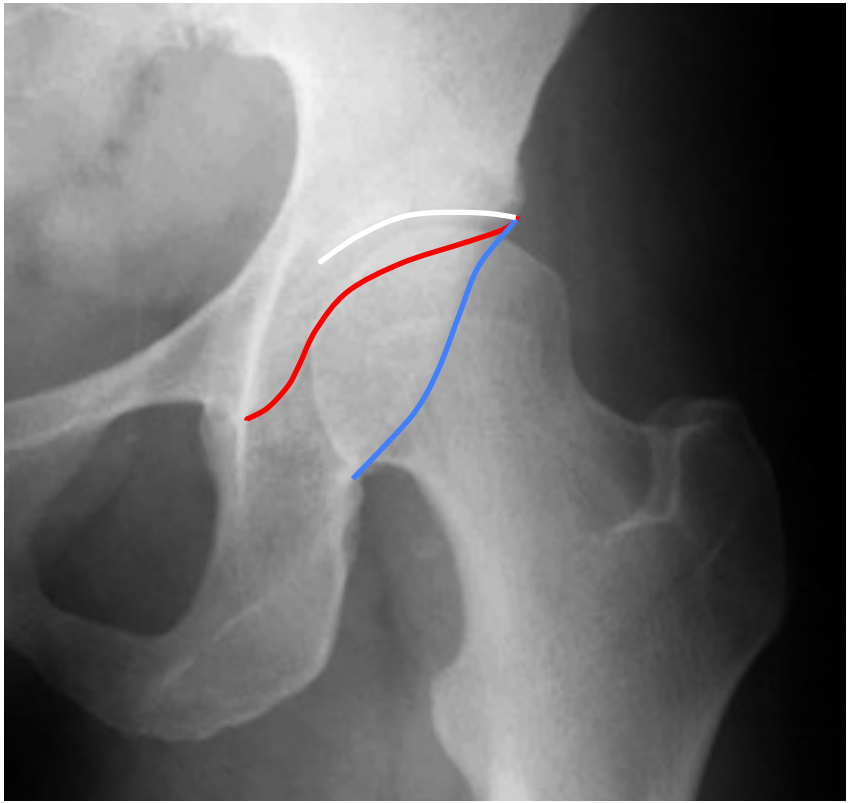

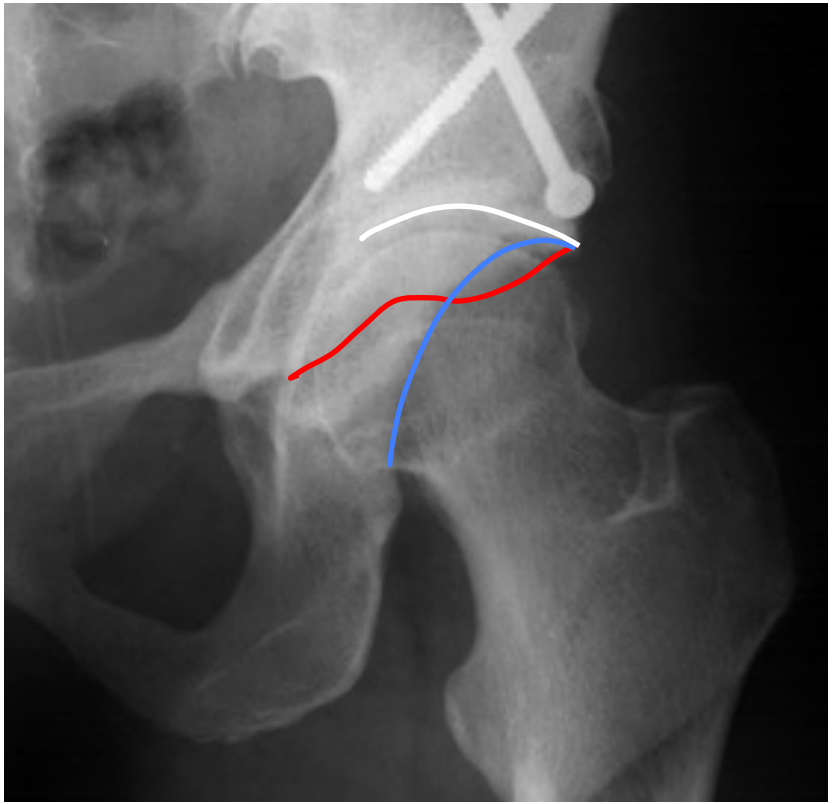

Overview complications in hip preservation surgery

HAS (3.3-8%)	CHL (9%)	PAO (9%)	*Sink*
Heteotopic ossification I+II 0.5-19% Dysesthesia LCFN Temporary Nerv lesion 0.9% Iatrogenic lesions 0.7%	Heteotopic ossification I+II (1.8%)	Heteotopic ossification I+II Dysesthesia LCFN	I
Superficial infections 0.2%	Delayed union trochanteric osteotomy Neuropraxia sciatic nerve	Delayed union os pubis Fracture posterior column Neuropraxia femoral nerve	II
Adhesions 0.2% Deep infection 0.02% Intraabdominal extravasate 0.04%	Fracture greater trochanter Wound infection Adhesions (6%) Trochanter refixation (2%)	Hematome / wound dehiscence Deep wound infection	III
Iatrogenic lesions (4.7-50%) Femoral neck fracture DVT 0.09%, PE 0.01% AVN 0.02%, Death 0.01%	DVT Lesion sciatic nerve (0.3%)	DVT Lesion sciatic nerve (0.3%)	IV

Steppacher SD et al, CORR 2015; Haefeli PC et al. CORR 2016; Papavasiliou et al BJR 2012; Sink et al. JBJS Am 2011; Nakano N. BJJ 2017; Weber AE Sports Med Arthroscopy 2015

Results SHD – Literatur overview

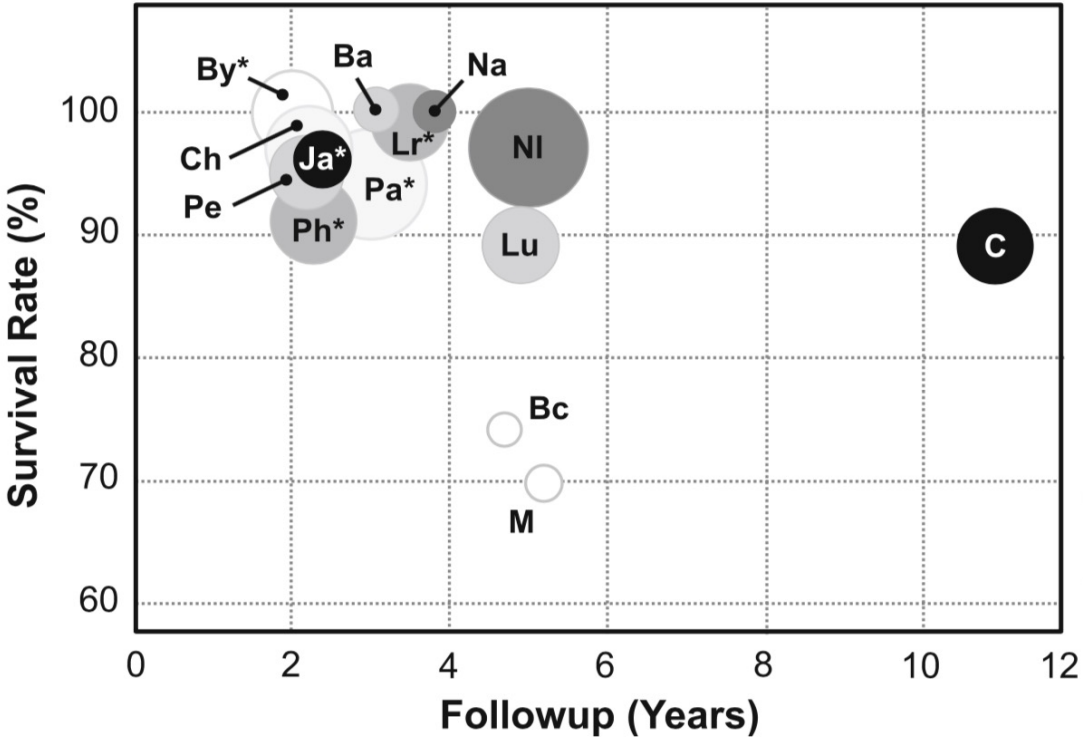

Bc Beck et al, 2004 [3]
M Murphy et al, 2004 [26]
Ba Beaulé et al, 2007 [2]
Lu Laude et al, 2009 [20]
Ph* Philippon et al, 2009 [31]
Pe Peters et al, 2010 [30]
By* Byrd and Jones, 2011 [6]
Na Naal et al, 2011 [28]
Ch Chiron et al, 2012 [7]
Lr* Larson et al, 2012 [19]
Nl Naal et al, 2012 [27]
Pa* Palmer et al, 2012 [29]
Ja* Jackson et al, 2014 [15]
C Current Study

* Arthroscopic Surgery

Steppacher et al, CORR, 2015

Results HAS – Literatur overview

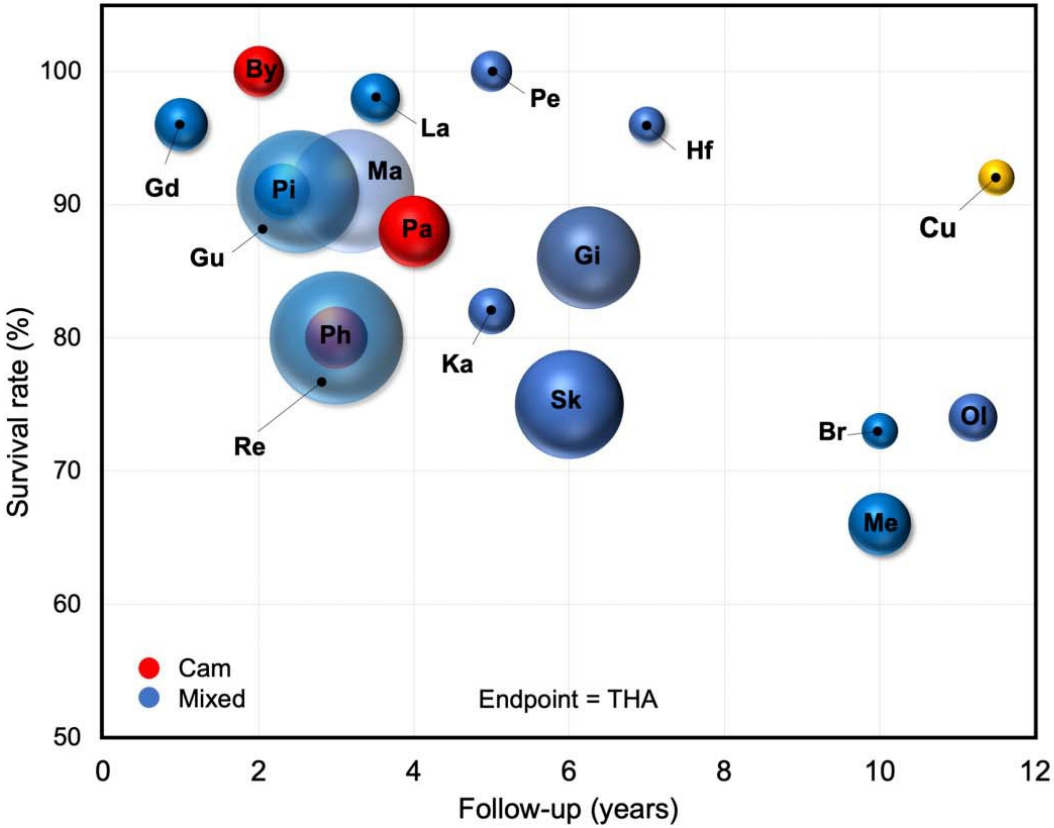

Pi	Philippon et al.[38]
Br	Byrd et al.[10]
Gd	Gedouin et al.[17]
By	Byrd et al.[11]
La	Larson et al.[25]
Ma	Malviya et al.[29]
Pa	Palmer et al.[36]
Ph	Philippon et al.[39]
Sk	Skendzel et al.[42]
Gu	Gupta et al.[19]
Re	Redmond et al.[41]
Me	Menge et al.[32]
Hf	Haefeli et al.[20]
Ol	Olach et al.[35]
Ka	Kaldau et al.[23]
Pe	Perets et al.[37]
Gi	Giordano et al.[18]
Cu	Current study

Büchler et al, CORR, 2021

Results PAO – Literatur overview

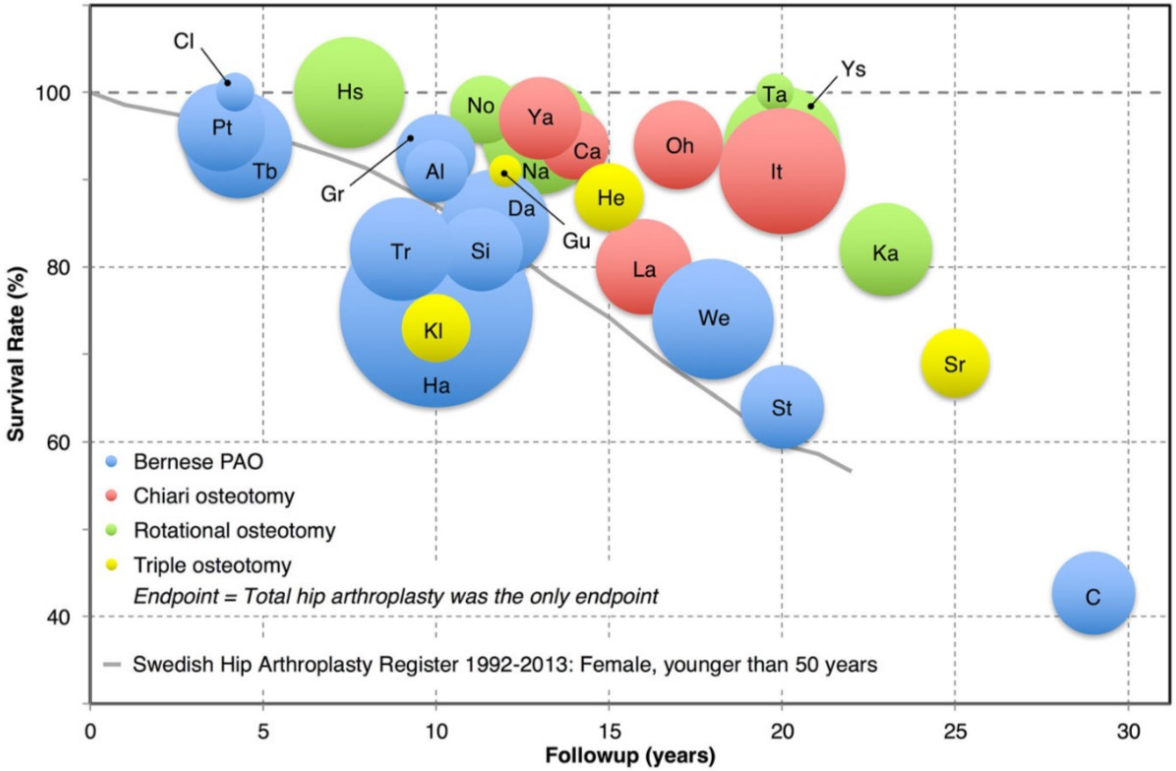

Al	Albers et al, 2013
Ca	Calvert et al, 1987
Cl	Clohisy et al, 2005
Da	Dahl et al, 2014
Gr	Grammatopoulos et al, 2016
Gu	Guille et al, 1992
Ha	Hartig-Andreasen et al, 2012
He	van Hellemondt et al, 2005
Hs	Hasegawa et al, 2002
It	Ito et al, 2011
Ka	Kaneuji et al, 2015
Kl	de Kleuver et al, 1997
La	Lack et al, 1991
Na	Nakamura et al, 1998
No	Nozawa et al, 2002
Oh	Ohashi et al, 2000
Pt	Peters et al, 2006
Si	Siebenrock et al, 1999
Sr	van Stralen et al, 2013
St	Steppacher et al, 2008
Ta	Takatori et al, 2001
Tb	Trumble et al, 1999
Tr	Troelsen et al, 2009
We	Wells et al, 2016
Ya	Yanagimoto et al, 2005
Ys	Yasunaga et al, 2016
C	Current study

Lerch et al, CORR, 2017

Summery

- Hip preservation surgery is succesful
  - Almost 80% with good clinical outcome and without progression of osteoarthris and THA after 10 years and 30% after 30 years

- Include risk factors in decision making
  - Pre-existing osteoarthritis (> Tönnis 1)
  - Age > 40 - 50 years
  - Obesity

- The right intervention for the pathomorphology in question
  - Intra- versus extraarticular impingement
  - Relevant problem of femoral torsion
  - Reversred PAO versus trimming in acetabular retroversion


© Pierre Cuony Photographies